

Efficacy and safety of dual-axis rotational coronary angiography versus conventional angiography

GERARDO NAU¹, MARIANO ALBERTAL², FERNANDO CURA^{MTSAC, 1}, LUCIO PADILLA¹, ALFONSINA CANDIELLO¹, FABRICIO TORRENT¹, SEBASTIÁN PERALTA¹, JORGE BELARDI^{MTSAC, 1}

Received: 01/27/2012

Accepted: 03/22/2012

Address for reprints:

Dr. Gerardo Nau
Instituto Cardiovascular de Buenos Aires
Blanco Encalada 1543
(1428) CABA
Phone number: +54 11 4787-7500
e-mail: g_nau@yahoo.com

ABSTRACT

Background

Conventional coronary angiography (CA) is the gold standard for the diagnosis of coronary artery disease. However, this technique requires several orthogonal projections to determine the severity of the disease. Dual-axis rotational coronary angiography (DARCA) is a new technique which acquires the image of each coronary artery using a single contrast injection, potentially reducing both radiation and contrast exposure.

Objective

The aim of this study was to determine the amount of contrast used, radiation exposure and diagnostic accuracy of DARCA compared to conventional CA.

Methods

We conducted a prospective, self-controlled study of consecutive patients undergoing elective coronary angiography to compare DARCA versus the conventional technique. All the angiographies were reviewed by two independent interventional cardiologists (observer 1 and observer 2) who evaluated agreement between both types of images. The observers evaluated firstly DARCA and three weeks later conventional CA images to prevent bias in their interpretation.

Results

The contrast volume used in the diagnostic procedure was significantly lower with DARCA (33.29 ± 11.2 ml vs. 17 ± 5.4 ml; $p < 0.01$). Radiation exposure in the patient (235.6 ± 76.8 mGy vs. 82.7 ± 46.6 mGy; $p < 0.01$) and operator was also significantly lower (5.7 ± 3.26 μ Sv vs. 2.48 ± 1.47 μ Sv; $p < 0.04$). A slight difference and a strong correlation were seen in the number of lesions, vessel diameter and percentage of stenosis between both observers and both methods. Categorical assessment of percentage of stenosis also showed adequate agreement.

Conclusion

DARCA reduces the use of contrast agents and radiation exposure compared to the conventional technique without modifying the diagnostic accuracy of the method.

REV ARGENT CARDIOL 2012;80:280-285. <http://dx.doi.org/10.7775/rac.v80.i4.1489>

Key words > Rotational Angiography - Coronary Artery Disease - Radiation

Abbreviations >

CA	Conventional angiography	mGy	Miligray
DARCA	Dual-axis rotational coronary angiography	μ Sv	Microsievert
RCA	Right coronary artery		

^{MTSAC} Full Member of the Argentine Society of Cardiology

¹ Department of Interventional Cardiology and Endovascular Therapeutics, ICBA

² Research Department, ICBA

BACKGROUND

Despite the increasing progress in cardiac imaging techniques, conventional angiography (CA) is still the standard diagnostic tool for the evaluation of coronary artery lesions and therapeutic strategy. (1)

However, CA has some limitations, such as the risk of contrast-induced nephropathy and radiation exposure of patients and hemodynamics laboratory staff. (2, 3)

The introduction of dual-axis rotational coronary angiography (DARCA), in which the C-arm rotates in two axes during scanning has allowed visualization of the coronary tree by using a single contrast injection. (4-6)

Thanks to this novel technique of image acquisition that entails automatic gantry movement following a left to right and cranial to caudal trajectory, the entire coronary tree is visualized. This movement has been adjusted to obtain all the projections of the CA, including the optimal projections of each segment, without vessel overlap and foreshortening. (6)

Several studies have demonstrated the feasibility and safety of DARCA for coronary artery evaluation. (7) However, the diagnostic accuracy of the method should be similar to that of CA to be considered as a standard method.

So far, current evidence on the performance and diagnostic safety of DARCA is limited.

The goal of this study is to determine the safety and diagnostic accuracy of DARCA compared to CA.

METHODS

Sample selection

This prospective study was designed to compare the feasibility, diagnostic accuracy and safety of DARCA versus conventional CA.

Population

Consecutive patients undergoing diagnostic coronary angiography were included. The study was performed in the Department of Interventional Cardiology and Endovascular Therapeutics at the Instituto Cardiovascular de Buenos Aires using a Philips Allura FD 20 system. All patients gave their informed consent prior to inclusion in the study. Patients with acute coronary syndromes, history of revascularization surgery and diagnosis of previous kidney failure (creatinine levels > 1.3 mg/dl) were excluded from the study.

Angiography

The choice of vascular access was left to the operator's discretion. Hypoosmolar contrast agent was injected manually following the standard protocol procedure. In all cases 6 French diagnostic catheters were used.

Conventional angiography was systematically performed in four projections for the left coronary artery (right anterior oblique-caudal, antero-posterior cranial, left anterior oblique-cranial and left anterior oblique-caudal) and in two projections for the right coronary artery (RCA) (left anterior oblique and antero-posterior cranial). The field of view was of 22 mm with image acquisition of 15 frames per second.

When conventional angiography ended, patients underwent DARCA. The isocenter was adjusted before image acquisition.

Total duration did not include the time taken to place the catheter in the artery under fluoroscopy and to adjust the isocenter.

DARCA acquisition is automated; therefore, the rotating C-arm follows a pre-established trajectory (Figure 1). Moreover, the duration of the C-arm movement and image acquisition are fixed: 5.3 seconds for the left coronary artery and 4 seconds for the right coronary artery.

Patients with total or severe occlusion of the RCA ostium or poorly developed and small caliber RCA were excluded from DARCA.

Analyzed variables and objectives

Procedure-related data (milliliters of contrast agent, patient and staff radiation exposure), angiographic data, patient risk factors, demographic information and procedure-related complications were prospectively collected.

The total radiation delivered during acquisition with both techniques was measured using air-kerma rate (mGray). Operator radiation exposure was also measured. Both radiations were measured for each diagnostic method with digital dosimeters placed outside the lead apron in the workplace following basic protection procedures.

The studies were evaluated by two independent, blinded, interventional cardiologists (observer 1 and observer 2) to determine the diagnostic accuracy of DARCA.

The observers reported the number of lesions (greater than 50% for the total number of patients) and their characteristics (percentage of stenosis and vessel length and size) observed with both techniques. According to the protocol, DARCA was evaluated firstly and CA was examined three weeks later. In order to minimize the margin of error in estimating lesion length, 30/82 (36.5%) lesions were selected with the same location in the coronary tree assessed by both methods and by both observers. Lesions were stratified in three groups: short (< 10 mm), intermediate (10-20 mm) and long (> 20 mm).

Statistical Analysis

Continuous variables were expressed as mean \pm standard deviation. The t test or the Kruskal-Wallis test was used

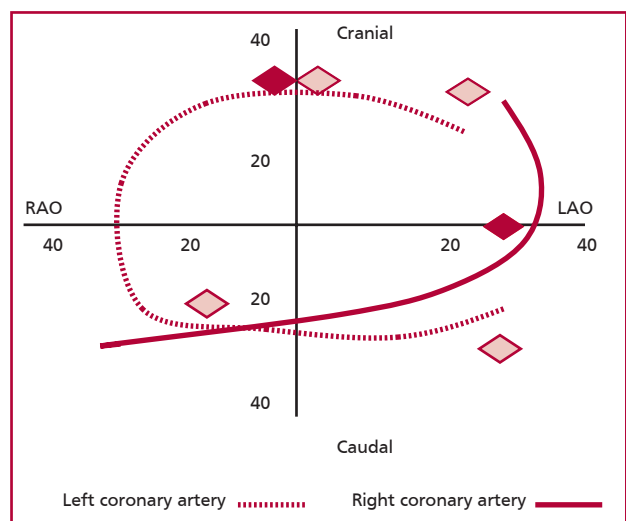


Fig. 1. Image acquisition with DARCA and CA. RAO: Right anterior oblique view. LAO: Left anterior oblique view. Lines: Detector trajectory during acquisition with DARCA. Diamonds: Automated acquisitions.

to compare two groups with parametric or non-parametric distribution, respectively. Categorical variables were expressed as percentages and were compared using the chi square test or Fischer's test as applicable. A p value < 0.05 was considered statistically significant.

Quantitative agreement between both techniques was established by means of the correlation coefficient and the results were graphically analyzed with the classic Bland-Altman method. The level of categorical variable inter-observer and inter-method agreement was analyzed using Cohen's kappa coefficient. Statistical analysis was performed using SPSS 18.0.0 statistical package for Windows, Chicago, Ill, USA.

RESULTS

Patient characteristics

Forty four patients were included: 80% were men and the majority had multiple risk factors (80% hypertension, 22.5% diabetes mellitus and 23.5% had smoking habits). One third of the patients had previous history of coronary artery disease, while 95.4% presented lesions greater than 50%, totalizing 82 lesions.

DARCA of the left coronary artery was performed in all patients; however, this method could not be used in the right coronary artery in eight patients due to the presence of ostial lesions with significant damping (two patients), proximal occlusion (two patients) and nondominant right coronary artery (four patients).

No complications were reported with both methods in the analyzed patients.

Contrast volume

The contrast volume used in DARCA was 45.4% lower than that used in CA (CA 33.29 ± 11.2 ml vs. DARCA 17 ± 5.4 ml; $p < 0.01$) (Figure 2).

The use of contrast agent decreased significantly in the left coronary artery (CA 28.1 ± 10 ml vs. DARCA 12 ± 2.9 ml; $p < 0.03$), while there was only a slight reduction in the RCA (CA 5.1 ± 4 ml vs. DARCA 4 ± 2.9 ml; $p < 0.06$).

Radiation

Patient radiation exposure was significantly lower with DARCA (CA 235.6 ± 76.8 mGy vs. DARCA 82.7 ± 46.6 mGy; $p < 0.01$) (65.4% total exposure reduction). This reduction was still significant when both arteries

were evaluated separately (in the left coronary artery: CA 186 ± 68.3 mGy vs. DARCA 52.9 ± 30.2 mGy; $p < 0.01$; in the RCA: CA 49.6 ± 44.5 mGy vs. DARCA 29.8 ± 6 mGy; $p < 0.03$).

Operator radiation exposure also decreased with DARCA compared to CA (CA 5.7 ± 3.26 μ Sv vs. DARCA 2.48 ± 1.47 μ Sv; $p < 0.04$) (see Figure 2).

Lesion evaluation

Of the 82 relevant lesions, 21 were bifurcation lesions, 6 were total occlusions, 5 were left main coronary artery lesions and 3 were intrastent restenosis. All the lesions were detected by both observers using both methods.

Intra-observer variability: observer 1 and observer 2

Independently of the observer, a slight, non-significant difference and a strong correlation could be seen in the number of lesions, vessel diameter and percentage of stenosis with both methods (Table 1). In the case of percentage of stenosis evaluation with both methods, $\leq 10\%$ difference was observed in 90% and 83.4% of the lesions assessed by observers 1 and 2, respectively (Figure 3). The Bland-Altman plot (Figure 4) shows that most of the observations lie within the 95% CI and does not suggest presence of systematic errors. In addition, there was an optimal agreement between observer 1 and observer 2 in the evaluation of lesion length (Table 2).

Inter-observer variability: observer 1 versus observer 2

No significant differences were noticed in the number of lesions, vessel size and percentage of stenosis evaluated by both observers with DARCA (Table 1). Less than 10% difference was observed for percentage of stenosis in 66.7% of lesions evaluated by DARCA and in 86.8% lesions assessed by CA (see Figure 3). The Bland-Altman plot (Figure 5) shows that most of the observations lie within the 95% CI and does not suggest presence of systematic errors.

DISCUSSION

The following results should be highlighted:

1. The exposure to contrast agents and radiation is lower in DARCA than in CA.

Fig. 2. Contrast volume and radiation exposure according to the method.

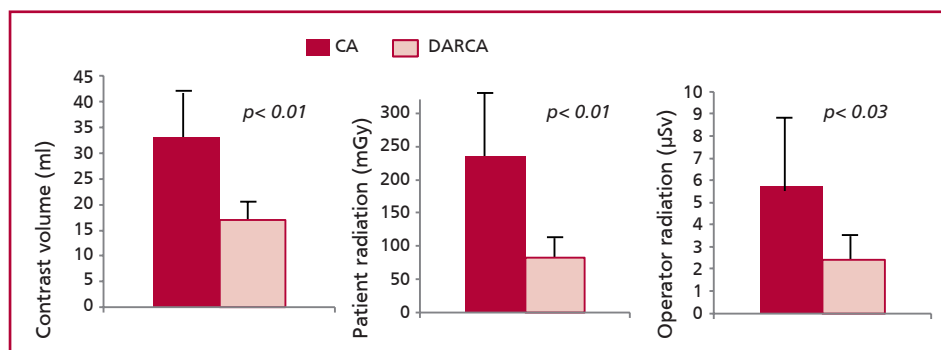


Table 1. Evaluation of lesion characteristics according to the observer and angiographic method

	CA	Observer 1 DARCA	Delta*/Correlation**	CA	Observer 2 DARCA	Delta*/Correlation**
Number of lesions	2 ± 0.9	1.9 ± 1	0 (0 a 0.25)/r = 0.70	2.2 ± 1.1	1.8 ± 1.1	0 (0 to 1)/r = 0.8
Vessel diameter (mm)	2.92 ± 0.45	2.95 ± 0.66	0 (-0.3 to 0.5)/r = 0.77	2.8	2.8 ± 1.3	0 (-5 to 5)/r = 0.76
Stenosis (%)	73 ± 17	72 ± 17	0 (-5 to 0)/r = 0.77	73 ± 16	75 ± 18	0 (0 to 5)/r = 0.87

*Delta (CA - DARCA) is expressed as median (25-75% interquartile range). ** (CA vs. DARCA).

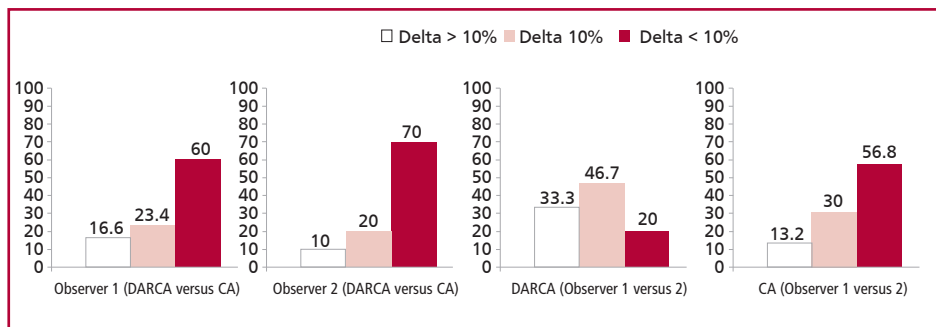


Fig. 3. Categorical comparison of percentage of stenosis between observers and between methods. Delta (observer 1 minus observer 2 or DARCA minus CA) was divided into three groups: < 10%, 10% and >10%.

2. The diagnostic accuracy of DARCA is similar to that of CA.

The use of diagnostic imaging tests such as computed tomography, arteriography and coronary angiography, among others, is a common medical practice associated with a not negligible nephrotoxicity risk. Contrast-induced nephropathy represents the third most common cause of intrahospital acute renal failure and its incidence in the literature varies significantly due to different definitions of contrast-induced nephropathy and the type and volume of administered contrast agent. (8, 9) Several studies confirm the impact of contrast-induced nephropathy in short- and long-term cardiovascular survival. In this sense, the reduction in contrast volume used with DARCA might have a favorable impact in patient outcome. (10) In addition, the use of lower contrast volume might be promising for patients with hemodynamic instability and volume overload. (10, 11) More studies are needed to clarify these issues.

Percutaneous interventions and reinterventions have increased due to greater life expectancy and progress in interventional cardiology. Thus, it is necessary to reduce the cumulative exposure to x-rays in patients with cardiovascular diseases. DARCA is an efficient tool to reduce administered radiation dosage as images are acquired at a speed of 30 frames per second. (12, 13) The use of special software associated with DARCA helps to choose the correct working position, with lower vessel overlap and foreshortening in all vessel segments, to program the therapeutic intervention after the three-dimensional reconstruction of the coronary tree.

Similarly, rotational X-ray tube motion allows a

better space location avoiding repetitive acquisitions during the intervention. In addition, reduction of operator radiation exposure is an advantage especially in high-volume centers with complex, prolonged procedures.

Despite our study was conducted on a small number of patients, we have included a broad spectrum of coronary artery diseases. However, no hemodynamic complications or arrhythmias were reported in agreement with previous publications. (6) These findings supplement the safety concept of the technique described in this study.

The diagnosis of coronary artery lesions with DARCA was comparable to that of CA in the number and characteristics of the evaluated lesions. These findings are similar to those reported in previous studies; however, our experience is the first one evaluating both methods by two independent and blinded interventional cardiologists, conferring reliability to the two methods. (6) Moreover, the diagnostic accuracy of the method is high according to this study as the interpretation of lesions > 50% have been similarly characterized by independent specialists.

CONCLUSIONS

DARCA is a safe diagnostic method to perform coronary angiographies. This technique is feasible to use in routine medical practice reducing radiation dosage and contrast volume. Moreover, the study has revealed image quality equivalent to that of conventional methods associated with an adequate diagnostic interpretation.

Fig. 4. Bland-Altman plots comparing both methods.

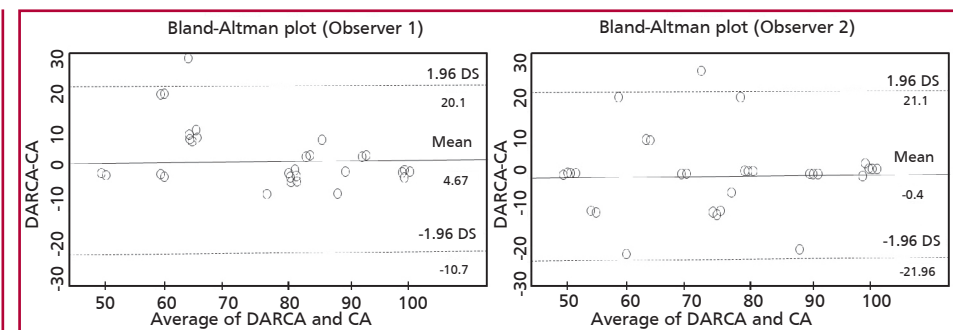


Fig. 5. Bland-Altman plots comparing both observers.

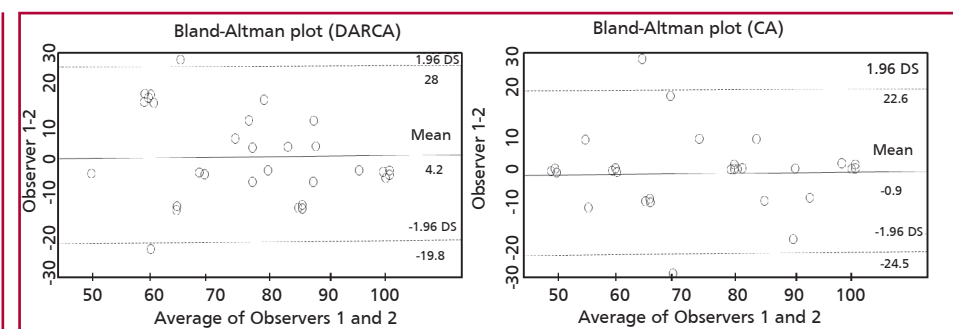


Table 4. Results of multivariate analysis

Observer 1		DARCA (n = 30)			Total
		≤ 10 mm	11-20 mm	> 20 mm	
CA (n = 30)	≤ 22	7	2	0	9
	11-20 mm	0	13	0	13
	> 20 mm	0	0	8	8
	Total	7	15	8	30

Level of agreement (kappa index): 0.92

Observer 2		DARCA (n = 30)			Total
		≤ 10 mm	11-20 mm	> 20 mm	
CA (n = 30)	≤ 22	7	3	0	10
	11-20 mm	2	11	3	16
	> 20 mm	0	0	4	4
	Total	9	14	7	30

Level of agreement (kappa index): 0.61

RESUMEN

Angiografía coronaria con técnica rotacional doble: eficacia y seguridad frente a la coronariografía convencional

Introducción

La angiografía convencional (AC) es la técnica de referencia para el diagnóstico de la enfermedad coronaria. Sin embargo, requiere múltiples proyecciones ortogonales para determinar el grado de enfermedad. La técnica de angiografía rotacional dual (ARD) permite una única adquisición e inyección de contraste para cada coronaria, con potencial reducción del volumen de contraste y de la dosis de radiación.

Objetivo

Comparar ambas técnicas (AC vs. ARD) a través de la eval-

uación de cantidad de contraste, exposición a la radiación y eficiencia diagnóstica.

Material y métodos

El presente es un estudio prospectivo, consecutivo, autocontrolado de coronariografías electivas para comparar AC y ARD. Todas las angiografías fueron revisadas por dos hemodinamistas independientes (observador 1 y observador 2) para evaluar la concordancia entre ambos tipos de imágenes. Para prevenir un sesgo en la lectura de las imágenes, los observadores evaluaron primero las ARD y tres semanas más tarde hicieron lo propio con las AC.

Resultados

Con la ARD se observó una reducción en la utilización de contraste ($33,29 \pm 11,2$ ml vs. $17 \pm 5,4$ ml; $p < 0,01$) y en la exposición a radiación del paciente ($235,6 \pm 76,8$ mGy vs. $82,7 \pm 46,6$ mGy; $p < 0,01$) y del operador ($5,7 \pm 3,26$ μ Sv vs. $2,48 \pm 1,47$ μ Sv; $p < 0,04$). Se observó una leve diferencia y una fuerte correlación en el número de lesiones, diámetro del vaso y porcentaje de estenosis entre ambos observadores y entre ambos métodos. La evaluación categórica del porcentaje de estenosis también demostró una concordancia adecuada.

Conclusión

La ARD reduce el uso de contraste y la exposición a radiación en comparación con la técnica convencional, sin alterar la eficiencia diagnóstica del estudio.

Palabras clave > Angiografía rotacional - Enfermedad coronaria - Radiación

REFERENCES

1. Scanlon PJ, Faxon DP, Audet AM, Carabello B, Dehmer GJ, Eagle KA, et al. ACC/AHA guidelines for coronary angiography: executive summary and recommendations. A report of the American College of Cardiology/American Heart Association Task Force on Practice Guidelines (Committee on Coronary Angiography) developed in collaboration with the Society for Cardiac Angiography and Interventions. *Circulation* 1999;99:2345-57.

2. Caixeta A, Mehran R. Evidence-based management of patients undergoing PCI: contrast-induced acute kidney injury. *Catheter Cardiovasc Interv* 2010;75:S15-20.
3. Solomon RJ, Mehran R, Natarajan MK, Doucet S, Katholi RE, Staniloae CS, et al. Contrast-induced nephropathy and long-term adverse events: cause and effect? *Clin J Am Soc Nephrol* 2009;4:1162-9.
4. Garcia JA, Agostoni P, Green NE, Maddux JT, Chen SY, Messenger JC, et al. Rotational vs. standard coronary angiography: an image content analysis. *Catheter Cardiovasc Interv* 2009;73:753-61.
5. Maddux JT, Wink O, Messenger JC, Groves BM, Liao R, Strzelczyk J, et al. Randomized study of the safety and clinical utility of rotational angiography versus standard angiography in the diagnosis of coronary artery disease. *Catheter Cardiovasc Interv* 2004;62:167-74.
6. Klein AJ, Garcia JA, Hudson PA, Kim MS, Messenger JC, Casserly IP, et al. Safety and efficacy of dual-axis rotational coronary angiography vs. standard coronary angiography. *Catheter Cardiovasc Interv* 2011;77:820-7. doi: 10.1002/ccd.22804.
7. Garcia JA, Chen SY, Messenger JC, Casserly IP, Hansgen A, Wink O, et al. Initial clinical experience of selective coronary angiography using one prolonged injection and a 180 degrees rotational trajectory. *Catheter Cardiovasc Interv* 2007;70:190-6.
8. Mehran R, Nikolsky E. Contrast-induced nephropathy: definition, epidemiology, and patients at risk. *Kidney Int Suppl* 2006;(100):S11-5.
9. Schweiger MJ, Chambers CE, Davidson CJ, Blankenship J, Bhalla NP, Block PC, et al. Prevention of contrast induced nephropathy: recommendations for the high risk patient undergoing cardiovascular procedures. *Catheter Cardiovasc Interv* 2007;69:135-40.
10. McCullough PA, Wolyn R, Rocher LL, Levin RN, O'Neill WW. Acute renal failure after coronary intervention: incidence, risk factors, and relationship to mortality. *Am J Med* 1997;103:368-75.
11. Rihal CS, Textor SC, Grill DE, Berger PB, Ting HH, Best PJ, et al. Incidence and prognostic importance of acute renal failure after percutaneous coronary intervention. *Circulation* 2002;105:2259-64.
12. Grech V, Grech M, Debono J. Greater radiation savings at higher body mass indexes with dual axis rotational coronary angiography. *Catheter Cardiovasc Interv* 2012 Apr 18. doi: 10.1002/ccd.24407.
13. Lee JB, Chang SG, Kim SY. A comparison between dual axis rotational coronary angiography and conventional coronary angiography. *Catheter Cardiovasc Interv* 2011 Nov 22. doi: 10.1002/ccd.23415.