



## CASE REPORT

Yuri Castro.<sup>1</sup>  
Silvana Grados.<sup>2</sup>  
Sixto Grados.<sup>2</sup>

1. Centro Médico Naval Cirujano Mayor  
Santiago Távara. Perú.

2. Universidad Nacional Mayor de San  
Marcos. Perú.

Corresponding author: Yuri Castro.  
Jr. Tomás Catari 463, Urb. El Trébol.  
Dpto 201. Los Olivos. Perú. Phone:  
9 89836354. E-mail: yuricastro\_16@  
hotmail.com

**Receipt:** 08/07/2014 **Revised:** 08/25/2014  
**Acceptance:** 09/04/2014 **Online:** 09/04/2014

## Peri-implant soft tissue augmentation with a porcine collagen matrix.

**Abstract:** A good amount and width of keratinized tissue around implants has been associated with better peri-implant health, less bone loss and improved esthetics. The purpose of this case was to evaluate a new porcine xenograft (collagen matrix) used as an interpositional graft to augment thickness of the peri-implant mucosa. There are few studies using a collagen matrix as a substitute for subepithelial connective graft around implants. This case involved a clinical implant in teeth 15 in which it was made the most of it during placement of healing abutment by taking the opportunity to increase peri-implant mucosa with a collagen matrix. Thickness increased 1.5mm while the amount of keratinized mucosa was kept at 4mm. It is concluded that the collagen matrix of porcine origin is a good alternative to increase thickness of the peri-implant mucosa and reduce morbidity. It is easy to handle and suture as well.

**Keywords:** *Esthetics, dental implant, peri-implant tissue, peri-implant mucosa thickness, peri-implant health.*

*Cite as: Castro Y, Grados S & Grados S. Peri-implant soft tissue augmentation with a porcine collagen matrix. J Oral Res 2014; 3(4): 244-248.*

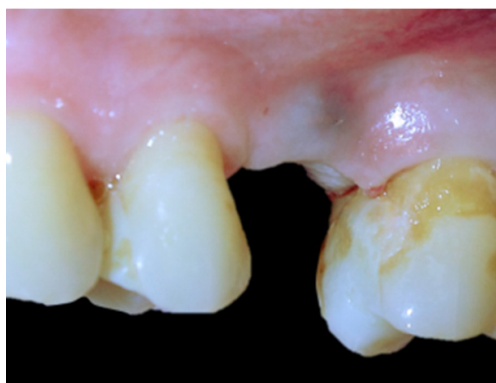
### INTRODUCTION.

Keratinized gingiva is important because it keeps teeth fixed protecting periodontal insertion (bone, periodontal ligament and cementum)<sup>1</sup>. There is still controversy about the right amount of gum which is necessary to maintain proper periodontal health. Valderhaug says its scarcity increases swelling and subsequent loss of insertion<sup>2</sup>. The amount of soft tissue surrounding the implants is also a matter of controversy<sup>3</sup>. Grusovin conducted a review in which there was not sufficient evidence about the influence of peri-implant mucosa width on implant survival<sup>4</sup>. Just as the amount of gum is important, its thickness (gingival biotype and/or peri-implant biotype) has even greater importance when planning dental implants placement. An implant which is put in thin biotype is more likely to develop mucosal recessions or affect esthetics<sup>5</sup>. The inadequate amount and thickness of peri-implant soft tissue may cause poor esthetics leading to exposed implant thread as well<sup>6</sup>. Mandelaris *et al.*<sup>7</sup> indicated a good condition of soft tissue and keratinized tissue around implants relate to healthier

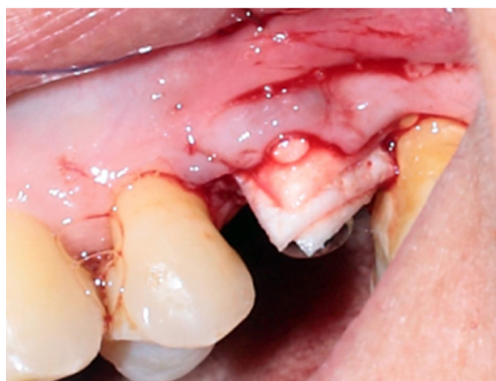tissue, less bone loss, and improved esthetics. There are several alternatives to improve the amount and thickness of soft tissue around the implants, the subepithelial connective graft being the main one. However, they require a donor site and a second surgery, greater postoperative discomfort and the graft volume depends on the anatomy of the host<sup>8</sup>. Collagen matrices arise as an alternative to autografting to increase the amount of keratinized tissue and its thickness<sup>4,6-8</sup>. Jung *et al.*<sup>9</sup> demonstrated that the action of the matrices is to encourage fibroblasts repopulation, blood vessels and epithelial growth. In their clinical trial, McGuire *et al.*<sup>10</sup> found wide root coverage (>88%) using collagen matrices. Castro *et al.*<sup>11,12</sup> found a 100% increase in fine biotype to coarse for treating recessions using collagen matrices as well. In this clinical case report, it is shown the use of the collagen matrix to enhance soft tissue thickness around an implant before prosthesis positioning.

### CASE.

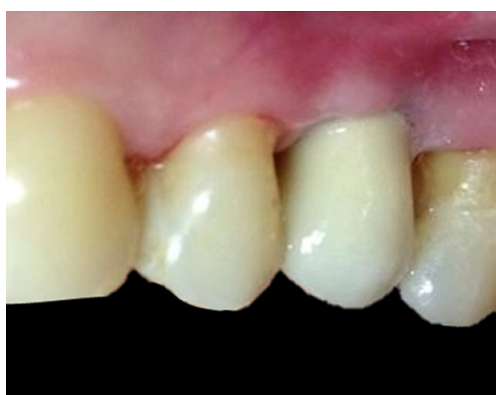This is the clinical case of a 58-year old patient



**Figure 1.** Translucency of implant thread in teeth 25.



**Figure 2.** Placement of the collagen matrix in partial thickness flap elevation.



**Figure 3.** Complete prosthetic restoration. The peri-implant biotype has thickened.

**Table 1.** Comparison of pre and postoperative parameters.

MEASURE	PERI-IMPLANT BIOTYPE	KERATINIZED MUCOSA
Basal	0.5mm	4mm
2 months	1.5mm	4mm

without systemic history to consider. She had an implant of 3.75mm with length of 11mm placed with sinus lift using the Summers technique with periostomes. After a 4-month period of implant osseointegration, the patient returned for implant rehabilitation. In the intraoral clinical examination, it was observed that the mucosa was translucent so the implant could be seen as a dark zone at coronal level in the vestibular region (Figure 1). The implant did not show any mobility signs or peri-implant radiolucency at peri-implant level. A mucogingival deformity with small thickness of peri-implant mucosa in the edentulous ridge was diagnosed. Then, it was planned to augment the thickness of such tissue using a porcine collagen matrix.

#### **Surgical procedure.**

The surgical site was anesthetized with local anesthesia, lidocaine at 2% and epinephrine (Scandicaine) 1:80,000. It was decided to make a partial thickness flap without releasing incisions before placing healing abutment. Once a partial thickness flap had been created, it was proceeded to manipulate the collagen matrix. The collagen matrix (Porciper)<sup>®</sup> was a bilaminar matrix composed of a complex extracellular matrix collagen and elastic fibers. The collagen matrix of porcine origin (xenograft) was obtained from the Tissue Bank of the Institute of Child Health (Instituto de Salud del Niño, INSN) of Perú and processed through cryopreservation and lyophilization at the Peruvian Institute of Nuclear Energy (Instituto Peruano de Energía Nuclear, IPEN). The matrix was immersed in physiological saline for 30 minutes before being inserted in the flap; placing the porous portion of the matrix against the periosteum and the occlusive layer towards the inside of the flap (Figure 2). The matrix was sutured with 4-0 polyglycolic acid to the peri-implant mucosa to fix its position. Once it was attached to the matrix, a 4mm implant healing abutment was placed and then the flap was placed in a more apical position and it was set using horizontal mattress suturing.

#### **Clinical follow-up.**

Prior to surgical intervention, measures of keratinized mu-

cosa (KM) amount (measured from the most coronal edge of the edentulous ridge to the mucogingival junction) and the thickness of the mucosa (TM) (drilling with periodontal probe until it comes to an endodontic end, 1mm apical to the gingival margin of the flap up to bone level). All measurements were done with a WHO 15mm millimeter periodontal probe (Hu-Friedy). Baseline measurements were: KM 4mm and 0.5mm of basal TM. The postoperative measure was reassessed two months after surgery getting a new TM of 1.5mm and maintaining the same amount of keratinized mucosa (Table 1) (Figure 3).

## DISCUSSION.

In the present study, the initial peri-implant mucosa thickness was 0.5mm and the new postoperative thickness was 1.5 thus obtaining an increase of 75% in the amount with collagen matrix of porcine origin, maintaining the amount of 4mm keratinized mucosa to achieve higher peri-implant biotype and prevent translucency of the dental implant. The absence of adequate keratinized peri-implant mucosa has been associated with increased plaque accumulation and gingival inflammation but not with increased peri-implant bone loss<sup>13</sup>. The collagen matrix of porcine origin was introduced as an alternative to autografting to improve conditions of the peri-implant keratinized mucosa<sup>14</sup>. Rochietta *et al.*<sup>14</sup> performed a histological study to determine its properties and found that, thirty days after surgery, almost complete healing of the area where the collagen matrix had been grafted was achieved. In this case, two months followed after surgery and complete healing was also observed in that time. Sanz *et al.*<sup>15</sup> used collagen matrices to increase the amount of keratinized tissue around teeth with prosthetic restorations finding similar results between the connective graft and the collagen matrix. Wei<sup>16</sup> and *et al.*<sup>17</sup>, Park used it around implants and achieved an average increase of keratinized mucosa of 2.2mm. In this case, the amount of keratinized mucosa did not increase, maintaining a measure of 4mm. Histological studies show that the collagen matrix has the capacity to lead fibroblast stimulating their growth and increase the expression of extracellular proteins such as

collagen type I and fibronectin<sup>18</sup>. In their systematic review, Sanz *et al.*<sup>5</sup>, Jung *et al.*<sup>9</sup> and Thoma<sup>19</sup> indicated that the biggest increase of keratinized gingiva occurs when there is a flap apically positioned and a free gingival graft. On increased volume (biotype), there are few data or studies which relate to peri-implant mucosa. Mandelaris *et al.*<sup>7</sup> found an excellent biocompatibility of the matrix when used around implants achieving rapid replacement and a new epithelialization of the matrix; no inflammatory cell proliferation or harmful response was seen. In this case, it was similar since no complications or adverse reactions to the collagen matrix were observed. The collagen matrix has already been approved by the FDA for regenerative therapy of teeth and implants including treatment of recessions and, in the future, it could replace connective grafts<sup>10</sup>. Rothamel *et al.*<sup>20</sup> mentioned that during collagen membrane matrix healing, a rapid transmembrane angiogenesis occurs and is followed by a gradual enzymatic degradation of the matrix due<sup>10</sup> to immune cells. Jun *et al.*<sup>9</sup> recommend to further research with this new biomaterial and/or develop new biomaterials and techniques. In this case, a porcine matrix was used as an alternative to increase the peri-implant mucosa biotype. Nevertheless, future clinical studies and clinical trials are needed to determine the success and long-term stability of this new biomaterial.

## CONCLUSION.

The adequate amount of keratinized mucosa to maintain health around implants is still controversial; but its absence has been associated with a greater accumulation of plaque and inflammation, not with increased peri-implant bone loss, though.

Xenografts may be a good alternative to connective tissue grafts since they have proved to have a uniform thickness of graft, be easy to handle, provide good esthetics and reduce treatment morbidity for patients.

The collagen matrix of porcine origin is biocompatible and can increase soft tissue volume as well as the amount of keratinized mucosa. Besides, in approximately 30 days, it is quickly replaced by new connective tissue.

It was possible to increase the thickness of the peri-implant mucosa, a second operation for extracting a graft was avoided

and acceptable esthetics around the dental implant was achieved using the collagen matrix of porcine origin.

### Aumento de tejido blando periimplantario con matriz de colágeno porcino. Reporte de caso clínico.

**Resumen:** Una buena cantidad y grosor de tejido queratinizado alrededor de implantes ha sido asociado con una mejor salud periimplantaria, menos pérdida ósea y una mejora en la estética. El propósito de este caso clínico fue evaluar un nuevo xenoinjerto de origen porcino (matriz de colágeno) al ser utilizada como un injerto interposicional para aumentar el grosor de la mucosa periimplantaria. Son pocos los estudios que utilizan la matriz de colágeno como sustituto del injerto conectivo subepitelial alrededor de implantes. El

caso clínico incluyó un implante a nivel de la pieza 15, en el cual durante la colocación del pilar de cicatrización se aprovechó para engrosar la mucosa periimplantaria utilizando una matriz de colágeno. Se obtuvo un aumento de grosor de 1,5mm manteniéndose la cantidad de mucosa queratinizada de 4mm. Se concluyó que la matriz de colágeno de origen porcino es una buena alternativa para aumentar el grosor de la mucosa periimplantaria, además de reducir la morbilidad, ser de fácil manejo y de fácil sutura.

**Palabras clave:** *Estética, implante dental, tejido periimplantario, grosor mucosa periimplantaria, salud periimplantaria.*

### REFERENCES.

1. Lindhe J. Periodontología Clínica e Implantología Odontológica. 1° Ed. Madrid: Médica Panamericana; 2000.
2. Valderhaug J, Birkeland JM. Periodontal conditions in patients 5 years following insertion of fixed prostheses. Pocket depth and loss of attachment. J Oral Rehab 1976; 3: 237-43.
3. Lorenzo R, García V, Orsini M, Martin C, Sanz M. Clinical efficacy of a xenogeneic collagen matrix in augmenting keratinized mucosa around implants: a randomized controlled prospective clinical trial. Clin Oral Impl Res 2012; 23: 316-24.
4. Grusovin MG, Coulthard P, Worthington HV, Esposito M. Maintaining and recovering soft tissue health around dental implants: a Cochrane systematic review of randomised controlled clinical trials. European J Oral Implantol 2008; 1: 11-22.
5. Palacci P, Nowzari H. Soft tissue enhancement around dental implants. Periodontol 2000. 2008; 47: 113-132.
6. Schallhorn RA, Charles A, Clem D, McClain PK, Newman MG. Practice-Based Case Series Evaluation of a Porcine Collagen Matrix to Thicken Soft Tissue, Increase Keratinized Tissue and Improve Esthetics Around Existing Dental Implants. Clin Adv Periodontics 2012; 2; 1-7.
7. Mandelaris GA, Lu M, Rosenfeld AL. The Use of a Xenogeneic Collagen Matrix as an Interpositional Soft-Tissue Graft to Enhance Peri-Implant Soft-Tissue Outcomes: A Clinical Case Report and Histologic Analysis. Clin Adv Periodontics 2011; 1: 193-8.
8. Simion M, Rocchietta I, Fontana F, Dellavia C. Evaluation of a resorbable collagen matrix infused with rhPDGF-BB in peri-implant soft tissue: A preliminary report with 3.5 years of observation. Int J Periodontics Restorative Dent 2012; 32: 273-82.
9. Jung RE, Hurzeler MB, Thoma DS, Khraisat A, Hammerle CH. Local tolerance and efficiency of two prototype collagen matrices to increase the width of keratinized tissue. J Clin Periodontol 2011; 38: 173-9.
10. McGuire MK, Scheyer ET. Xenogenic Collagen Matrix With Coronally Advanced Flap Compared to Connective Tissue With Coronally Advanced Flap for the Treatment of Dehiscence-Type Recession Defects. J Periodontol 2010; 81: 1108-17.
11. Castro Y, Grados S. Porcine collagen matrix for treating gingival recession. Randomized clinical trial. J Oral Res. 2014; 3(1): 23-8.
12. Calderón IC, Castro YR. Cirugía periodontal e implantológica. Paso a paso. 1era edición. Lima: Universidad Nacional Mayor de San Marcos; 2013.
13. Chung DM, Oh TJ, Shotwell JL, Misch CE, Wang HL. Significance of Keratinized Mucosa in Maintenance of Dental Implants With Different Surfaces. J Periodontol 2006; 77: 1410-20.
14. Rocchietta I, Schupbach P, Ghezzi C, Moschera E, Simion M. Soft tissue integration of a porcine collagen membrane: an experimental study in pigs. Int J Periodontics Restorative Dent 2012; 32: e34-e40.
15. Sanz M, Lorenzo R, Aranda JJ, Conchita M, Orsini M. Clinical evaluation of

- a new collagen matrix (Mucografts prototype) to enhance the width of keratinized tissue in patients with fixed prosthetic restorations: a randomized prospective clinical trial. *J Clin Periodontol* 2009; 36: 868-76.
16. Wei PC, Laurell L, Geivelis M, Lingen MW, Maddalozzo D. Acellular dermal matrix allografts to achieve increased attached gingiva. Part 1. A clinical study. *J Periodontol* 2000; 71: 1297-305.
17. Park JB. Increasing the width of keratinized mucosa around endosseous implant using acellular dermal matrix allograft. *Implant Dent* 2006; 15: 275-81.
18. Thoma DS, Jung RE, Schneider D, Cochran DL, Ender A, Jones AA, Görlach C, Uebersax L, Graf-Hausner U, Hämmerle CH. Soft tissue volume augmentation by the use of collagen-based matrices: a volumetric analysis. *J Clin Periodontol* 2010; 37: 659-66.
19. Thoma DS, Hämmerle CH, Cochran DL, Jones AA, Görlach C, Uebersax L, Mathes S, Graf-Hausner U, Jung RE. Soft tissue volume augmentation by the use of collagen-based matrices in the dog mandible – a histological analysis. *J Clin Periodontol* 2011; 38: 1063-70.
20. Rothamel D, Schwarz F, Sager M, Herten M, Sculean A, Becker J. Biodegradation of differently cross-linked collagen membranes: an experimental study in the rat. *Clin Oral Impl Res* 2005; 16: 369-78.