

CASE REPORT

Oscar Venegas¹, Luis Jaramillo¹,
Martin Nicola¹, Natalia
Covarrubias², Benjamín
Martínez³, Bárbara Olivós¹.

1.- Hospital San Juan de Dios, La
Serena, Chile.

2.- Facultad de Medicina, Universidad
Católica del Norte, Chile.

3.- Facultad de Odontología,
Universidad Mayor, Chile.

Receipt: 01/23/2014

Revised: 02/10/2014

Acceptance: 03/07/2014

Online: 03/07/2014

Corresponding author: Dr. Oscar Venegas.
Balmaceda 916. Hospital San Juan de Dios
de la Serena. Phone: 90249246. Email:
oscarvenegasmax@gmail.com.

Introduction.

Pleomorphic Adenoma (PA) is the most common of benign salivary gland tumors (80%)¹. It is an epithelial derivation and normally appears as a well-circumscribed, benign tumor, which may or may not be encapsulated².

Approximately, 75% of PAs occur in the parotid gland. Other common sites are the submandibular gland (15%) and minor salivary glands of the palate and nasal septum (10%). They appear less frequently in the minor salivary glands of the upper lip, cheeks, floor of the mouth, larynx and trachea³. The most frequent location of the pleomorphic adenoma in the minor salivary glands is the hard palate, followed by lips, oral mucus, floor of the mouth, tonsil, pharynx, retromolar area and nasal cavity⁴.

Histologically, it is characterized by a diverse architecture comprised of epithelial stromal elements mixed with mucoid, myxoid, or chondroid fibrohyaline⁴ located in the depths of the submucosa. Tumors in the salivary glands lack fibrotic encapsulation, giving a false appearance of infiltration (although, they possess a very thin capsule)⁵.

Historically, the main clinical problems have been risk of recurrence and possible malignant

Pleomorphic adenoma of the palate: Two cases report and literature review.

Venegas O, Jaramillo L, Nicola M, Covarrubias N, Martínez B & Olivós B. Pleomorphic adenoma of the palate: Two cases report and literature review. *J Oral Res* 2014; 3(1): 46-49.

Abstract: Pleomorphic adenoma (PA) is the most common neoplasm encountered in major and minor salivary glands. Intraorally, it is most frequently developed in the palatal glands. Histologically, it is characterized by a diverse architecture comprised of epithelial stromal elements mixed with mucoid, myxoid, or chondroid fibrohyaline. A PA does not generally present gender bias and can occur at any age with the same clinical behavior. It is usually a round, slow-growing, painless tumor, which is firm upon palpation. We reported two cases of adult patients who were treated using transoral resection at San Juan de Dios Hospital in La Serena.

Keywords: Pleomorphic Adenoma, Salivary Glands, Tumor.

Adenoma pleomorfo palatino: Reporte de 2 casos y revisión de la literatura.

Abstract: El Adenoma Pleomorfo es la neoplasia más común de las glándulas salivales mayores y menores. Intraoralmente las glándulas del paladar son las más afectadas. Histológicamente se caracteriza por una arquitectura variada que comprende elementos epiteliales mezclados con estroma mucoso, mixoide, fibrohialino o condroide. Los AP no suelen presentar predisposición por sexos, pudiendo aparecer a cualquier edad, con el mismo comportamiento clínico. Se presentan habitualmente como una tumoración redondeada de crecimiento lento, indolora y firme a la palpación. Presentamos dos casos de pacientes adultos, quienes fueron tratados mediante resección transoral en el hospital de la Serena.

Palabras clave: Adenoma Pleomorfo, Glándulas salivales, Tumor.

transformation⁶. However, mixed malignant tumors, which include carcinoma, ex-pleomorphic adenoma (malignant transformation of benign pleomorphic adenoma), carcino-sarcoma or metastasizing pleomorphic adenoma (MPA), are rare and represent 2 to 6% of salivary gland tumors⁶.

Clinical signs of malignancy in pleomorphic adenoma are the following:

1. Brusque acceleration of growth in a tumor that has been present for 10 to 30 years.

2. Irregular surface of the tumor and adherence to skin.

3. Appearance of superficial vascular alterations, at times with telangiectases or necrosis, which can be observed to fluctuate in the necrotic areas and attachment to other tissues. Ulceration may be present.

4. Sensation of tightness or pressure changes to pain⁷.

PAs do not normally present gender predisposition, appearing at any age and with the same clinical behavior. They are usually a round, slow-growing, painless tumor, which is firm upon palpation⁸.

Tumor-like lesions in the palate are not infrequent in clinical practice and their possible diagnoses, con-

sidering the posterior location of the hard palate, could include⁹:

1. Dental or periodontal infection.
 2. Benign or malignant neoplasia of salivary glands.
 3. Soft tissue tumor, including a wide variety of tissues (fibrous tissue, fat, muscle, nerves and vessels).
- This group involves a large variety of lesions from fibromas to alveolar sarcoma of soft parts.

The most frequent masses found in the palate are mixed tumors (pleomorphic adenoma) of the salivary gland followed by mucoepidermoid carcinoma¹⁰⁻¹¹.

Diagnosis of PA depends on clinical findings, tissue sampling and radiographic images by means of CT with contrast and MRI in T1 and T2⁹. These tests are essential to evaluate with utmost precision the extension and anatomical relations of the tumor to be able to plan an effective surgical treatment⁴.

Due to its initial benign behavior, it is best to use the most conservative surgical techniques whenever excision is possible. Prognosis is excellent if the resection has been effectively performed. Another therapeutic option is post-operative radiotherapy which reduces the recurrence rate; above all, when the capsule has broken during surgery and for patients whose border of normal tissue surrounding the resected tumor was very narrow¹². In those cases, periodical check-ups are necessary due to the possibility of local recurrence and malignancy¹².

The objective of this publication is to describe two clinical cases of Pleomorphic Adenoma, treated in the Unit of Surgery of San Juan de Dios Hospital in La Serena, and carry out a literature review about this pathology.

Case 1.

One of the patients was a sixty-five year-old female. She had a history of hypertension and diabetes and was allergic to acetylsalicylic acid. In May 2010, she consulted the Head & Neck and Maxillofacial Team at San Juan de Dios Hospital in La Serena due to an increase in palate volume over a period of two years.

In the transoral exam, a 3x4 cms tumor could be observed in the left palatal area (Fig. 1). It was covered with normal mucus, well-circumscribed, firm and painless upon palpation. There was no sensory or motor deficiency and no clinical evidence of alterations in the general physical exam.

Imaging (computerized tomography) showed a hypodense lesion in the left posterior hard palate. It was well-defined and slightly lobulated, measuring 20.25x21.19x13 mm in its maximum diameter. An imprint of the lesion could also be observed in the maxillary and palatal bones (Fig. 2).

Before definitive surgery, an incisional biopsy of the involved area was carried out; the histopathological report of tissue samples confirmed a Pleomorphic Adenoma (Fig. 3).

Considering the clinical study, imaging and histology, a mucoperiosteic resection of the lesion, with a safety margin of one centimeter¹³, was planned for January 2011, thus confirming the initial pathology. The intervened area was left with a prosthesis (attached with screws and wires due to the absence of maxillary teeth) and iodized gauze for approximately 18 days (Fig. 4).

In November 2011, hyperplastic tissue was clinically observed in the area of the original lesion; it was removed and biopsied, the report informing conjunctive epithelial hyperplasia with mild dysplasia.

At present, three years after the resection, there has been no sign of recurrence, observing a palate with normal cicatrization (Fig. 5).

Figure 1. Left palatine tumor well located, 3x4 cm. Figure 2. Brain CT, lesion on left hard palate, 20,25mm x 21,19mm x 13,00mm, imprinting over maxillar and palatine bones.

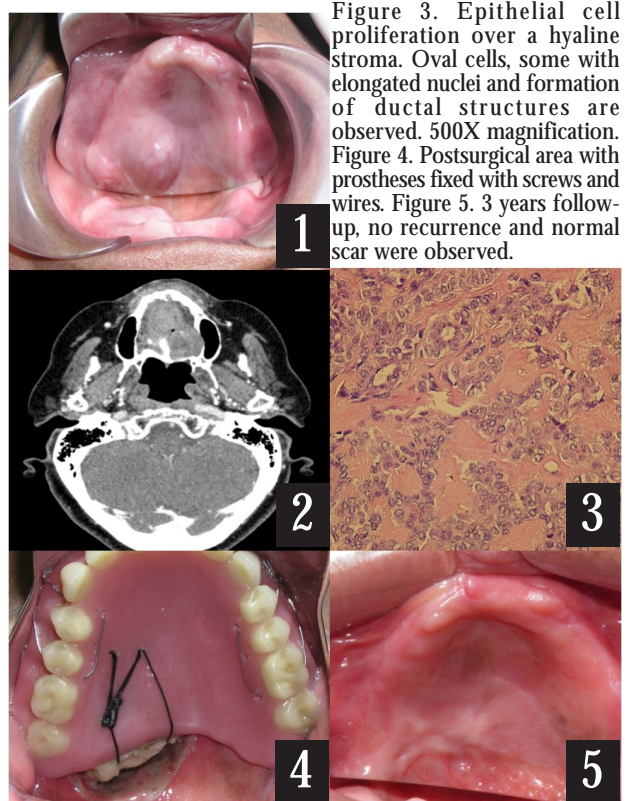


Figure 3. Epithelial cell proliferation over a hyaline stroma. Oval cells, some with elongated nuclei and formation of ductal structures are observed. 500X magnification. Figure 4. Postsurgical area with prostheses fixed with screws and wires. Figure 5. 3 years follow-up, no recurrence and normal scar were observed.

Case 2.

The other patient was a thirty-six year-old female, with no history of systemic illnesses and allergic to penicillin. In 2004, she consulted The Head & Neck and Maxillofacial Team at San Juan de Dios Hospital

in La Serena due to an increase in palate volume over a period of seven months.

In the transoral exam, a 2x2 cms tumor could be observed in the left palatal area. It was covered with normal mucus, well-circumscribed, firm and painless upon palpation (Fig.6). There was neither sensory or motor deficiency nor alterations in the general physical exam.

Imaging (computerized tomography) showed a hypodense lesion in the left posterior hard palate, without bone involvement (Fig.7).

Before the final surgical procedure, an incisional biopsy of the pathology was performed, confirming pleomorphic adenoma.

After taking into consideration the results of all exams carried out, a mucoperiostic resection was planned with a safety margin of one centimeter. (Fig. 8) The intervened area was covered with iodized gauze and a splint or maxillary prosthesis with retainers for approximately two weeks.

No recurrence was exhibited in the patient's posterior evaluation in January, 2013 and the palate presented normal characteristics (Fig. 9).

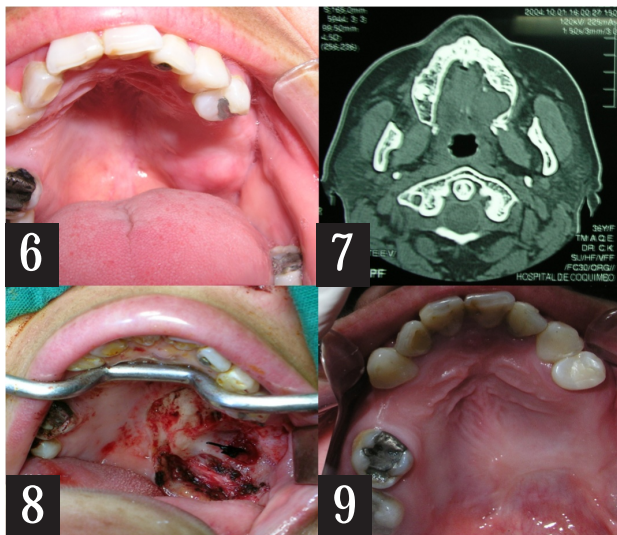


Figure 6. Left palatine tumor, 2x2cm. Figure 7. CT shows the palatine lesion on the left posterior area, without bone compromise. Figure 8. Resection of the lesion. Figure 9. 9 years follow-up, no recurrences were observed.

Discussion.

Pleomorphic adenoma, or mixed benign tumor, represents 80% of all benign tumors of salivary glands, its main location being the parotid. However, it can be found in minor salivary glands and in this case, the palate is the most frequent location^{1,4}, as seen in the two cases described above.

As indicated by literature and in agreement with the cases presented, its clinical appearance can occur at any age⁸. It is slow-growing and, generally, asymptomatic, supporting the benign component of these tumors. The reason for seeking medical consultation is volume increase, which, upon examination, shows a firm mass, covered with normal mucus, without swallowing or voice alterations. Generally, tumors of the salivary glands are discovered during routine clinical exams as an asymptomatic mass¹⁴; however, patients in both clinical cases presented sought medical consultation spontaneously.

For the histological study, an incisional biopsy was performed, demonstrating PA in both cases, thus confirming the assumed initial diagnosis. The treatment which followed was a complete mucoperiostic surgical resection, with a safety margin of one centimeter of healthy mucus, using transoral access. Some authors describe the superficial scraping or curettage of adjacent bone tissue; this is due to the possible presence of remainders of PA on the bone surface and not to the infiltration of the bone¹⁵. Pedemonte *et al.* indicates that, in the oral cavity, mucoperiostic surgical extirpation of the lesions located in the palate must be performed. With a correct surgical technique, the recurrence of PA is less than 5%. Risk of recurrence seems to be less in minor salivary glands¹⁴. It is important to point out that, in the palate, tumor cells are usually found in the capsule. Besides, when the capsule is incomplete, it is believed that these nests of neoplastic cells that perforated the capsule may form new tumor sites. If simple tumor enucleation is carried out, these cells may not be completely eliminated leading to possible recurrence. Therefore, resection of the pleomorphic adenoma must be mucoperiostic with a safety margin¹³ and it must be done after an incisional biopsy that confirms the correct histopathological diagnosis¹⁴. This was done in both of the clinical cases presented.

Recurrence of PA is mainly determined by the rupture of the tumor during surgery or incomplete resection¹⁶. At present, both patients attend follow-up consults and neither Case N° 1 nor Case N° 2 has suffered recurrence after three and nine years, respectively. However, recurrence incidence is minimized or disappears in all locations when the tumor is removed with a safety margin of normal tissue, as in both clinical cases presented.

In conclusion, it is necessary to recognize these firm and painless tumors in the palate and, considering the risk of malignancy, it is essential the opportune referral and treatment in benefit of our patients.

References.

1. Villar R, Monleón V. Adenoma pleomorfo en paladar duro. Revisión casuística. *Gaceta Dent*. 2008;198: 156-163.
2. Ethunandan M, Witton R, Hoffman G, Spedding A, Brennan P. Atypical features in pleomorphic adenoma—a clinicopathologic study and implications for management. *Int J Oral Maxillofac Surg*. 2006; 35: 608–612
3. Spencer J, Mohammed I, Sumangala B. Pleomorphic Adenoma of the Palate in Children and Adolescents: A Report of 2 Cases and Review of the Literature. *Oral Maxillofac Surg* 2007; 65: 541-549.
4. Vernetta P, García F, Ramírez J, Orts M, Morant A, Algarra J. Adenoma pleomorfo gigante de glándula salivar menor. Extirpación a través de un abordaje transoral. *Rev Esp Cir Oral Maxilofac*. 2008; 30: 201-204
5. Jorge J, Pires FR, Alves FA, Perez DE, Kowalski LP, Lopes MA, Almeida OP. Juvenile intraoral pleomorphic adenoma: report of five cases and review of the literature. *Int. J. Oral Maxillofac. Surg* 2002; 31: 273–275.
6. Reiland D, Koutlas I, Pearson A, Basi D. Metastasizing Pleomorphic Adenoma Presents Intraorally: A Case Report and Review of the Literature. *J Oral Maxillofac Surg* 2012; 70: 531-540.
7. González de Santiago M, Alatorre S, Moreno H, Muñoz L, Tovar C, Ávalos M, Muñoz D, Hernández V. Tumor mixto maligno de glándulas salivales menores de paladar. Revisión de literatura, presentación de un caso clínico. *Rev Mex Cir Bucal Maxilofac*. 2012; 8: 64-72
8. Carrillo E, Miranda E. Adenoma pleomorfo en labio. *Rev Odontol Mex*. 2012; 16: 102-104.
9. Marques KD, Andrade FR, Castro LA, Vêncio EF, Mendonça EF, Ribeiro-Rotta RF, Silva TA, Batista AC. Slow-Growing Palatal Mass: A Challenging Differential Diagnosis. *J Oral Maxillofac Surg* 2010; 68: 1884-1889,
10. Barnes L, Eveson J, Reichart P, Sindransky D. World Health Organization Classification of Tumours: Pathology and Genetics of Head and Neck Tumors. Lyon: IARC Press; 2005.
11. Pires F, Pringle G, De Almeida O, Chen S. Intra-oral minor salivary gland tumors: A clinicopathological study of 546 cases. *Oral Oncol*. 2007; 43: 463-470.
12. Piekarski J, Nejc D, Szymczak W, Wronski K, Jeziorski A. Results of Extracapsular Dissection of Pleomorphic Adenoma of Parotid . *J Oral Maxillofac Surg*. 2004; 62: 1198-1202.
13. Marx RE. Oral and Maxillofacial Pathology: A Rationale for diagnosis and treatment. Illinois: Quintessence Publishing; 2003.
14. Pedemonte C, Basili A, Montero S. Adenoma Pleomorfo de Glándulas Salivales Menores. *Rev Dent Chile* 2003; 94: 18-21.
15. Shaaban H, Bruce J, Davenport PJ. Recurrent pleomorphic adenoma of the palate in a child. *Br J Plast Surg* 2001; 54: 245-7.
16. Agreda-Moreno B, Urpegui-García A, Alfonso-Collado JL, López-Vásquez A, Valles-Varela H. Adenoma Pleomorfo de paladar. *ORL Aragón* 2010; 13: 8-10.