



ORIGINAL ARTICLE

Camilo Urrego.
Krissna Valdez.
Mario Moreno.
Luisa Palacio.
José Domínguez.
Germán Aguilar.
Cecilia Martínez.

Universidad de Antioquia. Colombia.

Corresponding author: Camilo Urrego.
Cra 45, N° 45-71 Int 3 Apto 904. Bogotá.
Colombia. Phone: (+57) 3156 5709 38.
E-mail: kmilouo77@hotmail.com

Receipt: 03/24/2015 **Revised:** 04/02/2015
Acceptance: 04/27/2015 **Online:** 04/27/2015

Frequency of mandibular asymmetries evaluated by cone beam computed tomography at a radiology diagnostic center in Medellín, Colombia. 2011-2013.

Abstract: Longitudinal differences on the left and right sides of the jaw with respect to the midline in three spatial planes are called mandibular asymmetries. Objective: To determine the frequency of mandibular asymmetries in three spatial planes by means of Cone Beam computed tomography (CBCT) and classify them according to the degree of difference between both sides. Methods: A total of 40 Cone Beam volumetric tomography (New Tom 3G Cone Beam Volumetric tomographic scanner) records were analyzed using simple random sampling of patients between the ages of 18 and 70 from 2011 until 2013. Axial slices were obtained from the lingula in cranio-caudal direction every 5 mm until the gonial angle. Results: From the records, 2.5% showed moderate degree of difference in the length of the mandibular body with predominance on the right side. For breadth of the ramus, predominance was found on the left side. In the length of the mandibular ramus, 10% presented moderate degree of predominance on the right side. Conclusions: 1) asymmetries are more frequent at the level of the mandibular ramus thickness; (2) moderate and severe degrees of differences are most frequently found in the mandibular ramus thickness. 3) It is not possible to proportionally determine mandibular ramus thickness only with a 2D image

Keywords: *Mandibular asymmetries, Cone Beam Volumetric tomographic scanner, mandibular body, mandibular ramus, mandibular thickness*

DOI: 10.17126/joralres.2015.036

Cite as: Urrego C, Valdez K, Moreno M, Palacio L, Domínguez J, Aguilar G & Martínez C. Frequency of mandibular asymmetries evaluated by cone beam computed tomography at a radiology diagnostic center in Medellín, Colombia. 2011-2013. *J Oral Res* 2015; 4(3):174-182.

INTRODUCTION.

In terms of symmetry and balance, facial aesthetics refers to the status of facial balance; that is to say, the relationship between size, shape and location of facial features on one side over the other in the sagittal plane¹. Symmetry is defined as the exact relationship between all parts of a figure or an object with respect to a center, an axis or a plane. In the mandibular bone, such axis is given by the skeletal midline. Then, asymmetry would be considered as the longitudinal difference between the left and right sides of the jaw with respect to the midline².

According to Luckow *et al.*³, craneomandibular asym-

metries may be of congenital nature, hereditary (development) or acquired. During growth, there can be functional alterations such as muscle forces applied to bones, which alter their growth pattern. Also, there can be occlusal disharmonies which lead to the appearance of evident mandibular asymmetries when there is a deviation of the jaw^{4,5}.

During childhood, the occurrence of trauma as condyle fractures and ear infections or virus also become environmental factors associated with the etiology of mandibular asymmetries⁵. Some severe asymmetries are observed in patients with craniofacial syndromes and may be associa-

ted with alterations in embryological development such as mutations or abnormalities in the proliferation or migration of cells from the neural crest⁶.

Several authors consider that asymmetry is a typical and frequent trait in human beings. Mills (1925) stated that “structural and functional asymmetries are a basic condition of the human body and have been present in the whole evolution”⁷ and Schwarz⁸ also considered asymmetry as normal. Thompson (1943) defined that “normal asymmetry is not very clear, while abnormal asymmetry is very obvious”⁹ and Fisher argued that “facial asymmetry is a natural phenomenon and there is nothing abnormal in it.”⁸ The routine examination used to evaluate mandibular asymmetries is the panoramic x-ray, but since it is a flat image of a three-dimensional structure, it only allows measuring variations in size and shape in two planes. Therefore, CT scan offers greater validity in assessing asymmetry in three spatial planes simultaneously⁹.

Diagnostic images in two dimensions are a dimensional representation of a three-dimensional object, *i.e.* the image can only show breadth and length, but not depth¹⁰. On the other hand, diagnostic images provide dimensional length, breadth and depth¹¹. In three dimensional images using tomography, the distortion degree is almost non-existent, contrary to two-dimensional ones. Besides, there is no overlapping of structures and they can be seen with greater clarity¹².

This study aims to determine frequency of mandibular asymmetries in three spatial planes by means of Cone Beam CT scans (CBCT) and to classify them according to the degree of differences between the two sides and the relationship between ramus thickness and vertical and anteroposterior measures.

MATERIALS AND METHODS.

A cross-sectional study was conducted. Using simple random sampling (SRS), 40 records of Cone Beam CT scans obtained with a team NewTom 3G Cone Beam Volumetric tomographic scanner (QR, Verona, Italy) were chosen. They were visualized in NNT Viewer software Cone Beam

Figure 1. Measurements taken in the panoramic tomography. CCh: Condileon to chin. ChG: Chin to gonium. CG: Condileon to gonium. SNAN: sigmoid notch to antegonial notch. GA: gonial angle.

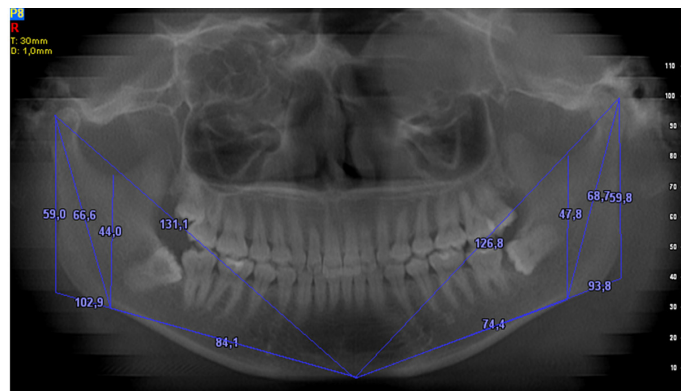
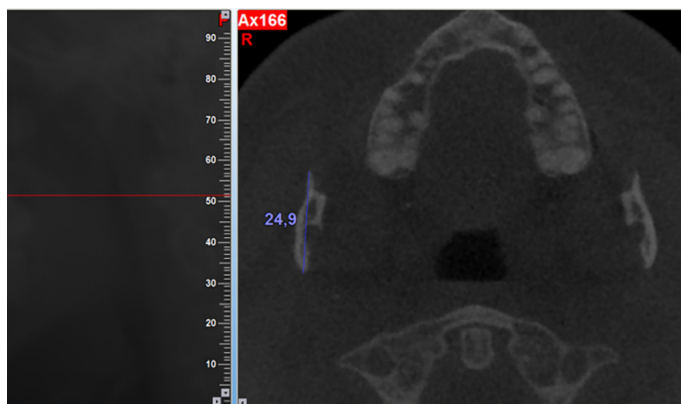
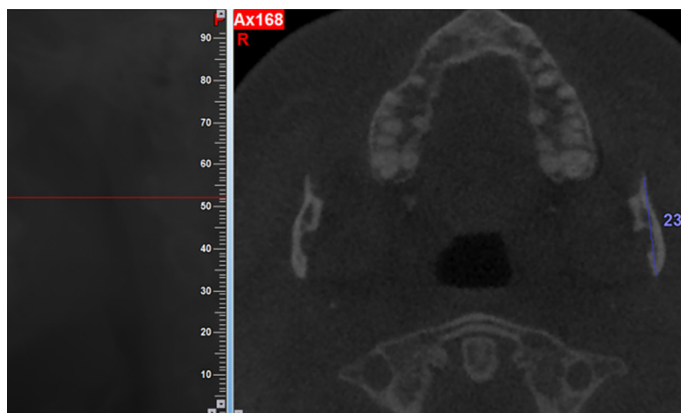


Figure 2. Measures taken in the breadth of the mandibular ramus.(APRW)



3D Imaging System from NewTom (Italy). The panoramic image obtained had a thickness of 30mm and axial slices from the lingula in crano-caudal direction- every 5mm. until reaching the gonial angle, to see mandibular ramus thickness in the transverse plane.

Figure 3. Thickness of the ramus at the level of the lingula (LOER). In this image, measures were taken from the back edge of the ramus up to its external side at the level of the lingula (BERL).

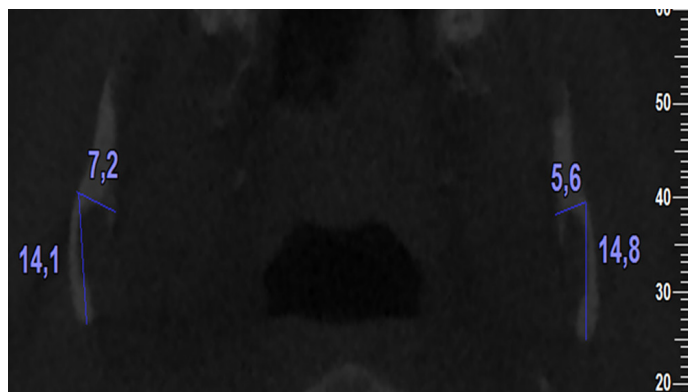
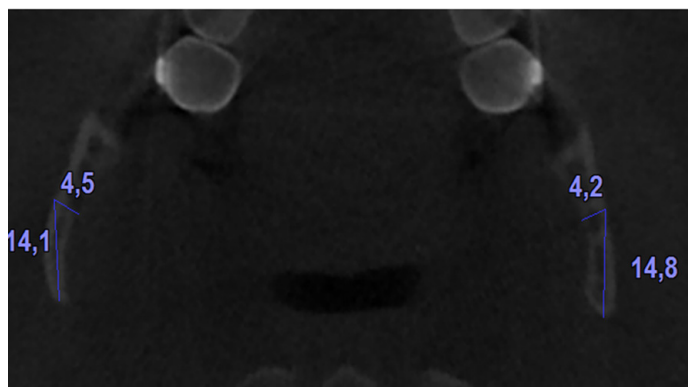


Figure 4. Ramus thickness 10 mm flow to the lingulas (RT10). This image is from the previous record and it should be noted that BERL measure remains the same, ensuring thickness can be measured at the same level in the various slices.



The patients' age recorded in the images ranged between 18 and 66 with an average of 35 (SD±14.6). From them, 57.5% were women.

The selection criteria were:

Inclusion criteria: Scanning records from patients between the ages of 18 and 70 obtained between 2011 and 2013, using a 12-inch window to display the full jaw bone.

Exclusion criteria: Scanning records from patients who had radiographic evidence of orthognathic surgery (titanium plates) and malformations from trauma, infection or tumor origin.

In the panoramic images, the following measures were taken for both sides. (Image 1):

- Condoleon - Chin (CCh).

- Chin - Gonium (ChG).

- Condoleon - Gonium (CG).

- Sigmoid Notch - Antegonial Notch(SNAN).

- Gonial angle (GA).

These measures were taken in order to establish the length of the mandibular ramus in craneo-caudal direction and the length of the mandibular body in antero-posterior direction. The following measures were taken in the axial slices for both sides:

- Breadth of the mandibular ramus in anteroposterior direction at the level of the lingula (APRW). (Image 2).

- Thickness of the ramus at the level of the lingula, i.e. from the lingula to the outer edge of the ramus (LOER). (Image 3).

- Thickness of the ramus 5mm flow to the lingula (RT5), as well as 10mm (RT10), 15mm (RT15), 20mm (RT20), 25mm (RT25) and 30mm (RT30)

- Ramus thicknesses were measured at the same level in the different slices. The distance from the back edge of the ramus up to the outside edge at the level of the lingula (this measurement was taken with LOER) was taken as a reference, i.e. the back edge of the ramus up to its external side at the level of the lingula (BERL). (Image 4).

These measures were taken in order to determine mandibular ramus thickness in transverse direction at different levels. The lingual of the mandible is taken as an anatomic reference in orthognathic surgery at the time of making a sagittal osteotomy of the mandibular ramus and in order to have a point of reference to objectively evaluate asymmetries between different images in spite of the fact that the size of the mandibular ramus varies from one person to another.

In several records, both lingulas were not at the same level, due to an asymmetry or a slight deviation in the position of the patient at the time of taking the image. For this reason, measures of both sides were taken independently. The same examiner took the measures twice, obtaining a Kappa value greater than 95%. Age and sex were also taken into account.

The data obtained from the images was compiled in a Microsoft Excel® 2010 (Microsoft Corp., USA) database and imported into SPSS® 19.0 (IBM, USA). A bivariate analy-

sis of the quantitative variables with Pearson correlation coefficient was carried out, considering $p < 0.05$.

Measurements obtained from the right side were compared with the left side. This way, asymmetries were classified after comparing both sides for each variable. The difference was calculated by taking the side with higher value as a reference and considering it as 100%. Therefore, the relationship between the percentage of that measure in relation to the lower value was calculated. The difference between these two relative values was the percentage of difference and it was classified as follows:

- 0 To 0.99% = Absence
- 1 To 4.99% = Very slight
- 5 To 9.99% = Slight
- 10 To 19.99% = Moderate
- More than 20% = Severe

This categorization was created by the authors of the study and it only determines the degree of difference seen in the images. It does not reflect the clinical behavior of asymmetries, due to the intervention of other factors which were not included in this study.

This study complied with the recommendations for biomedical research (Helsinki Declaration). In the imaging center, the patients signed the informed consent which declared, in addition to the risks and benefits of the test, the authorization to use data for research purposes. All the images included in this study are from patients referred by a treating clinician. None of the images were taken for research purposes only. The Institutional Ethics Committee evaluates research so that it complies with all the methodological and ethical requirements.

RESULTS.

In some cases, the measures of the ramus thickness in the axial slices could not be taken at 20mm (12.5% of records), 25mm (70% of records) and 30mm (97.5% of records), caudally to the lingula, due to the fact that some rami were not long enough in cranio-caudal direction.

Then, measures were taken to determine the length of the mandibular body (ChG), the breath of the mandibu-

lar ramus (APRW), the length of the mandibular ramus (CG) and the thickness of the mandibular ramus at the level of the lingula (LOER) considering that the latter thickness measure is more representative than that taken in the other axial slices.

Mandibular body length: It was found that only 2.5% of the records showed a moderate degree of difference in the length of the mandibular body with predominance on the right side. A total of 17.5% presented a slight difference with 100% of predominance on the right side, 65% presented a very slight difference with 77% of predominance on the right side and 15% showed no significant difference. (Table 1).

Breadth of the mandibular ramus: From the records, 10% showed a moderate degree of difference regarding breadth of rami with predominance on the left side. Another 12.5% of them displayed a slight difference with predominance on the left side. In 65% of them, the degree of difference was very slight with 73% of predominance on the right side and 12.5% of the records showed no difference.

Length of the mandibular ramus: Only 2.5% of the records presented a severe degree of difference with predominance on the left side, 10% showed a moderate degree of difference with predominance on the right side, 17.5% presented a slight degree of difference with predominance on the left side, 52.5% of the records presented a very slight degree of difference with predominance on left side in 57% of the cases and 17.5% showed no difference.

Thickness of the mandibular ramus at the level of the lingula: 12.5% of the records presented a severe degree of difference with a slight predominance on the right side, 25% presented a moderate degree of difference with 50% of predominance for both sides, in 25% of the records, a slight degree of difference with a predominance on the right side in 60% of the cases was found, 30% showed a very slight difference with a predominance on the right side in 75% of the cases and 7.5% of the records showed no difference. (Table 1).

It was found that 90% of the records presented a slight

Table 1. Frequency of asymmetries for each variable and classification according to the degree of proportional difference.

VARIABLE	Degree of asymmetry									
	(0-0.99%) Absence	(1 -4.99%) Very slight		(5 -9.99%) Slight		(10 -19.99%) Moderate		≥20% Severe		
Predominance	None	Right	Left	Right	Left	Right	Left	Right	Left	
	N(%)	N (%)	N(%)	N(%)	N(%)	N(%)	N(%)	N(%)	N(%)	
APRW	5 (12.5)	19 (47.5)	7 (17.5)	2 (5)	3 (7.5)	0	4 (10)	0	0	
LOER	3 (7.5)	9 (22.5)	3 (7.)	6 (15)	4 (10)	5 (12.5)	5 (12.5)	3 (7.5)	2 (5)	
RT5MM	2 (5)	2 (5)	7 (17.5)	7 (17.5)	1 (2.5)	9 (22.5)	7 (17.5)	1 (2.5)	4 (10)	
RT10MM	3 (7.5)	3 (7.5)	4 (10)	2 (5)	5 (12.5)	8 (20)	6 (15)	4 (10)	5 (12.5)	
RT15MM	1 (2.5)	4 (10)	4 (10)	7 (17.5)	3 (7.5)	7 (17.5)	4 (10)	1 (2.5)	9 (22.5)	
RT20MM	0	5 (12.5)	2 (5)	2 (5)	4 (10)	5 (12.5)	5 (12.5)	4 (10)	8 (20)	
RT25MM	1 (2.5)	1 (2.5)	1 (2.5)	1 (2.5)	2 (2.5)	2 (5)	3 (7.5)	0	1 (2.5)	
RT30MM	1 (2.5)	0	0	0	0	0	0	0	0	
CCh	8 (20)	23 (57.5)	8 (20)	0	0	1 (2.5)	0	0	0	
ChG	6 (15)	20 (50)	6 (15)	7 (17.5)	0	1 (2.5)	0	0	0	
CG	7 (17.5)	9 (22.5)	12 (30)	1 (2.5)	6 (15)	4 (10)	0	0	1 (2.5)	
SNAN	8 (20)	6 (15)	15 (37.5)	5 (12.5)	3 (7.5)	2 (12.5)	1 (2.5)	0	0	
Total	43	101	69	40	31	44	35	13	30	

APRW: Breadth of anteroposterior ramus. LOER: Lingula to outer edge of ramus. R: thickness of the mandibular ramus. CChM: Condyleon to chin. ChG: Chin to gonium. CG: Condyleon to gonium. SNAN: sigmoid notch to antegonial notch.

Table 2. Predominance of body length, breadth, thickness and length of ramus per side.

	Predominance body length, breadth, thickness and length of ramus		
	Right n (%)	Left n (%)	None n (%)
APRW PRED	21 (52.5)	14 (35)	5 (12.5)
CG PRED	14 (35)	19 (47.5)	7 (17.5)
ChG PRED	28 (70)	6 (15)	6 (15)
CCh PRED	24 (60)	8 (20)	8 (20)
SNAN PRED	13 (32.5)	19 (47.5)	8 (20)
LOER PRED	23 (57.5)	14 (35)	3 (7.5)
RT5PRED	19 (47.5)	19 (47.5)	2 (5)
RT10PRED	17 (42.5)	20 (50)	3 (7.5)
RT15PRED	19 (47.5)	20 (50)	1 (2.5)

PRED: Predominance. APRW: breadth of anteroposterior ramus. LOER: Lingula to outer edge of the ramus. RT: thickness of the mandibular ramus. CCh: Condyleon to chin. ChG: Chin to gonium. CG: Condyleon to gonium. SNAN: sigmoid notch to antegonial notch.

to moderate degree of difference in at least one of the measures of mandibular ramus thickness in the axial slices. The variables that showed greater differences in severe and moderate degrees were indicative of thickness measurements of the mandibular ramus.

It was observed that measures of APRW, ChG, CCh AND LOER were more predominant on the right side

and CCh and SNAN measures had greater predominance on the left side. (Table 2).

No statistically significant differences were found in the bivariate analysis ($p=0.7$). However, a trend in measures of CCh RT25 and RT25 with ChG (ramus thickness with body length of -0.71 and -0.70) inversely proportional between mandibular ramus thickness at 25mm from the

Table 3. Bivariate analysis of the variables and their respective correlation index.

Bivariate correlations on the right and left side													
	APRW	LOER	BERL	RT5	RT10	RT15	RT20	RT25	CCh	ChG	CG	SNAN	GA
APRW	1	,422	,700	,206	,385	,327	,230	-,533	,421	,546	,294	,198	-,385
LOER	,353	1	,377	,672	,644	,561	,410	,706	-,202	,193	-,194	-,216	-,409
BERL	,727	,282	1	,405	,409	,416	,322	-,258	,250	,301	,270	,251	-,319
RT5	,058	,573	,356	1	,678	,540	,471	,773	-,208	,036	-,020	-,052	-,403
RT10	,266	,609	,364	,668	1	,665	,546	,610	-,156	,139	-,166	-,250	-,251
RT15	,217	,587	,307	,600	,762	1	,902	,921	-,112	,085	-,072	-,112	-,140
RT20	,123	,456	,378	,626	,737	,906	1	,822	-,077	,053	-,143	-,210	,057
RT25	-,467	,857	-,325	,716	,746	,908	,948	1	-,712	-,705	-,430	-,479	,113
CCh	,436	-,154	,301	-,277	-,137	-,039	-,018	-,656	1	,628	,742	,605	-,021
ChG	,552	,189	,362	-,049	-,016	-,011	-,115	-,637	,652	1	,191	,048	-,592
CG	,271	-,160	,278	-,169	,002	,036	,079	-,568	,713	,104	1	,820	-,077
SNAN	,112	-,319	,200	-,163	-,060	,014	,048	-,577	,516	-,068	,813	1	,033
GA	-,423	-,341	-,400	-,305	-,292	-,119	,050	,143	-,010	-,483	-,031	,033	1

Correlations of the measures from the left side are below the dark strip and above it, the ones from the right side. The gray cells indicate Pearson coefficients with a proportional inverse relationship between RT25 and CCh and between RT25 and ChG from the left and right side. APRW: breadth of anteroposterior ramus. LOER: Lingula to outer edge of the ramus. RT: thickness of the mandibular ramus. CCh: Condyleon to chin. ChG: Chin to gonium. CG: Condyleon to gonium. SNAN: sigmoid notch to antegonial notch. GA: gonial angle.

lingula and mandibular body length was noted. (Table 3).

DISCUSSION.

Even though some authors such as Mills⁷, Schwarz, Fisher⁸ and Thompson⁹, considered facial asymmetries as something normal in human beings, Thompson also thought some asymmetries importance nowadays, to the point that it affects the person's quality of life. In this study, it was found that asymmetries are more frequent at the level of the mandibular rami thickness (12.5% and 25% severe to moderate level of the lingula and 90% of slight to moderate in at least one of the rest of the slices) and although this type of asymmetry may not be very obvious clinically, it acquires great importance when making a patient undergo orthognathic surgery because of an asymmetry located in another anatomical region.

In literature, there are studies which evaluate the frequency of mandibular asymmetries in three spatial planes using CBCT and show the importance of assessing them properly¹³⁻¹⁷. Baek *et al.* (2012)¹⁴ point out the importance of performing a systematic classification of asymmetries in patients who will undergo surgery using

3D Computed Tomography. Yañez *et al.*(2013)¹⁵ found a relationship between maxillo-mandibular asymmetries evaluated by means of 3D computed tomography and joint sounds. Keir and Kau (2014)¹⁶ highlight the value of properly assessing mandibular asymmetries because of their impact on occlusion. On the other hand, Bustamante *et al.*¹⁸ report very similar measures between 2D and CBCT, although this latter technique offers more precision for locating anatomical points and more approximation to real morphometric measurements¹⁹.

The evaluation of mandibular asymmetry using CBCT compares alterations at the level of the condylar process such as hyperplasia²⁰ and condylar size and tri-dimensional morphology of the condyle in patients with condylar hyperplasia^{21,22}.

The findings of this study agree with those of Plooijs *et al.*¹⁸ and Olate and Cantin¹⁹ indicating a greater predominance on the right side in the measures taken in a frontal view. Regarding CG distance, results were different because there was predominance on the left side in most of the images, although the study by the authors mentioned above was conducted in patients with a diag-

nosis of condylar hyperplasia.

In literature, there are no references about studies evaluating mandibular asymmetries using CBCT in our country. Neither do they determine the possibility of establishing proportional differences between mandibular rami thickness only with a 2D image or make a bivariate analysis with the measurements obtained. This would have great application in maxillofacial surgery.

It was not possible to determine the predominance of asymmetries in mandibular ramus thickness due to variations observed in each one of the observed axial slices and in measures of body length, ramus width and length. Asymmetries were classified from very slight to slight, *i.e.* with proportional differences between 1 and 10%.

Since no statistically significant differences were found in the correlation of variables (Pearson coefficient), it can be inferred that anteroposterior and vertical asymmetries behave independently compared to transversal asymmetries in the jaw²³⁻²⁴.

The possibilities that CBCT provides for assessing asymmetries in the three spatial planes (length, breadth and depth) [11] offers advantages compared to 2D images which only allow assessing length and breadth¹⁰. However, for economic reasons and because it has not yet been incorporated into usual dental clinical practice is not common to use CBCT. That is why, in this study, the possibility of determining the proportional difference of mandibular rami thickness only with a 2D image was considered but no correlation

coefficients close to 1 or -1 were obtained, probably because of the sample size. For this reason, it is recommended to use CBCT for more accurate diagnoses of mandibular asymmetries in function of orthognathic surgery procedures²⁵⁻²⁷, as one of the most widely used procedures in the field of maxillofacial surgery.

Additional research is needed to relate asymmetries in their different planes, including mandibular ramus thickness and with greater sample size to be able to confirm or refute the findings outlined in this study.

CONCLUSIONS.

Asymmetries are more frequent at the level of the mandibular ramus thickness and the degrees of moderate and severe differences are most frequently present at the level of the thickness.

Findings from this study are relevant because minimum mandibular ramus thickness could cause undesirable intraoperative fractures during execution of sagittal split osteotomy of ramus, which would lead to re-interventions, possible infections and other complications as a result of these.

It is not possible to proportionally determine mandibular ramus thickness using a 2D-image, which confirms the usefulness of 3D imaging.

ACKNOWLEDGEMENTS.

To Dr. Luis Gonzalo Alvarez Sánchez for helping us with the statistical analysis.

Frecuencia de asimetrías mandibulares evaluadas por tomografía computarizada cone beam de un centro de diagnóstico radiológico de Medellín, Colombia. 2011-2013

Resumen: Se denominan asimetrías mandibulares a las diferencias longitudinales de los lados derecho e izquierdo de la mandíbula con respecto a la línea media en los tres planos espaciales. Objetivo: Determinar la frecuencia de asimetrías mandibulares en los tres planos del espacio por medio de tomografía computarizada Cone Beam (TCCB) y clasificarlas según el grado de diferencia entre ambos lados.

Métodos: Se analizaron 40 registros de tomografía volumétrica Cone Beam, (New Tom 3G Cone Beam Volumetric Tomographic Scanner) mediante muestreo aleatorio simple de pacientes entre los 18 y 70 años de edad, entre los años 2011 y 2013. Se obtuvieron cortes axiales a partir de la línea en sentido cráneo-caudal cada 5 mm hasta llegar al ángulo goníaco. Resultados: El 2,5% de los registros presentaron diferencias moderadas en la longitud del cuerpo mandibular con predominio del lado derecho. En la amplitud de la rama se encontró predominio del lado izquierdo. En la longitud de la rama mandibular el 10% presentó

predominio moderado del lado derecho. Conclusiones: 1) las asimetrías más frecuentes se encuentran a nivel del grosor de las ramas mandibulares. 2) Los grados de diferencias moderados y altos se presentan con mayor frecuencia en el grosor de las ramas mandibulares. 3) No es posible deter-

minar proporcionalmente el grosor de las ramas mandibulares obteniendo solo una imagen 2D.

Palabras clave: *Asimetrías mandibulares, Tomografía computarizada Cone Beam, cuerpo mandibular, rama mandibular, grosor mandibular*

REFERENCES.

1. Taneja VK, Kumar GA, Farishta N, Minocha RC, Baiju G, Gopal D. An assessment of skeletal asymmetry in South Indian Population. *J Contemp Dent Pract.* 2012; 13(1):80-4.
2. Hernández F. Asimetrías craneofaciales: análisis radiográfico en los planos frontal y basal en individuos de ambos sexos de 18 a 22 años. *Rev Esp Cirug Oral y Maxilofac.* 2009; 31(1):24-25.
3. Luckow S, Martin Moreno M. Diagnóstico de asimetrías faciales utilizando tomografía volumétrica computarizada. *Rev Esp Ortod.* 2013; 43(1):5-12
4. Moon HJ, Lee YK. The relationship between dental occlusion/temporomandibular joint status and general body health: part 1. Dental occlusion and TMJ status exert an influence on general body health. *J Altern Complement Med.* 2011; 17(11):995-1000.
5. Biagi R, Craparo A, Trovato F, Butti AC, Salvato A. Diagnosis of dental and mandibular asymmetries in children according to Levandoski Panoramic Analysis. *Eur J Paediatr Dent.* 2012; 13(4):297-300.
6. Ramirez-Yañez GO, Stewart A, Franken E, Campos K. Prevalence of mandibular asymmetries in growing patients. *Eur J Orthod.* 2011; 33(3):236-42
7. George AM, Ganesan J, Devi S, Varghese BT, Krishnaswamy NR. Orthodontic and orthognathic management of a complex mandibular asymmetry. *Orthodontics (Chic.)* 2013; 14(1):126-39.
8. Mercier JM, Perrin JP, Longis J, Arzul L, Corre P. Facial asymmetries and their skeletal component. *Rev Stomatol Chir Maxillofac Chir Orale.* 2014; 115(4):219-28
9. Kim J, Jung H, Jung Y, Hwang C, Park H. A simple classification of facial asymmetry by TML system. *J Craniomaxillofac Surg.* 2013; 1-8.
10. Jaju PP, Jaju SP. Clinical utility of dental cone-beam computed tomography: current perspectives. *Clin Cosmet Investig Dent.* 2014; 2(6):29-43
11. Tetradis S, Anstey P, Graff-Radford S. Cone beam computed tomography in the diagnosis of dental disease. *Tex Dent J.* 2011; 128(7):620-8
12. Sanders DA, Chandhoke TK, Uribe FA, Rigali PH, Nanda R. Quantification of skeletal asymmetries in normal adolescents: cone-beam computed tomography analysis. *Prog Orthod.* 2014; 15(1):26
13. Lee H, Bayome M, Kim SH, Kim KB, Behrents RG, Kook YA. Mandibular dimensions of subjects with asymmetric skeletal class III malocclusion and normal occlusion compared with cone-beam computed tomography. *Am J Orthod Dentofacial Orthop.* 2012; 142(2):179-85.
14. Baek C, Paeng JY, Lee JS, Hong J. Morphologic evaluation and classification of facial asymmetry using 3-dimensional computed tomography. *J Oral Maxillofac Surg.* 2012; 70(5):1161-9
15. Yáñez-Vico RM, Iglesias-Linares A, Torres-Lagares D, Gutiérrez-Pérez JL, Solano-Reina E. Association between craniofacial asymmetry and unilateral temporomandibular joint sounds in adult patients using 3D-computed tomography. *Oral Dis.* 2013; 19(4):406-14.
16. Kheir NA, Kau CH. Measuring mandibular asymmetry in Class I normal subjects using 3D novel coordinate system. *Ann Maxillofac Surg.* 2014; 4(1):34-8
17. du Bois AH, Kardachi B, Bartold PM. Is there a role for the use of volumetric cone beam computed tomography in periodontics? *Aust Dent J.* 2012; 57 Suppl 1:103-8
18. Plooi JM, Maal TJ, Haers P, Borstlap WA, Kuijpers-Jagtman AM, Bergé SJ. Digital three-dimensional image fusion processes for planning and evaluating orthodontics and orthognathic surgery. A systematic review. *Int J Oral Maxillofac Surg.* 2011; 40(4):341-52
19. Olate S, Cantín M. Relación entre el tamaño condilar y la asimetría facial transversal en Individuos con Hiperplasia Condilar. *Int J Morphol.* 2013; 31(3):937-941.
20. Alhadidi A, Cevidane LH, Paniagua B, Cook R, Festy F, Tyndall D. 3D quantification of mandibular asymmetry using the SPHARM-PDM tool box. *Int J Comput Assist Radiol Surg.* 2012; 7(2):265-71.
21. Zhou H, Han J, Li Z. Conservative treatment of bilateral condylar fractures in children: Case report and review of the literature. *Int J Pediatr Otorhinolaryngol.* 2014; 78:1557-1562
22. Sanders DA, Chandhoke TK, Uribe FA, Rigali PH, Nanda R. Quantification of skeletal asymmetries in normal adolescents: cone-beam computed tomography analysis. *Prog Orthod.* 2014; 1;15(1):26.
23. Verzé L, Bianchi FA, Schellino E, Ramieri G. Soft tissue changes after orthodontic surgical correction of jaws asymmetry evaluated by three-dimensional surface laser scanner. *J Craniofac Surg.* 2012;

23(5):1448-52

24. Uribe F, Chugh VK, Janakiraman N, Feldman J, Shafer D, Nanda R. Treatment of severe facial asymmetry using virtual three-dimensional planning and a “surgery first” protocol. *J Clin Orthod.* 2013; 47(8):471-84
25. Bergamo AZ, Andrucioli MC, Romano FL, Ferreira JT, Matsumoto MA. Orthodontic-surgical treatment of Class III malocclusion with mandibular asymmetry. *Braz Dent J.* 2011; 22(2):151-6.
26. Domínguez J, Ruge O, Aguilar G, Nández O, Oliveros G. Análisis de la posición y trayectoria del conducto alveolar inferior (CAI) en tomografía volumétrica computarizada (TC Cone Beam - TCCB). *Rev Fac Odontol Univ Antioq.* 2010; 22(1):12-22.
27. Kim TY, Baik JS, Park JY, Chae HS, Huh KH, Choi SC. Determination of midsagittal plane for evaluation of facial asymmetry using three-dimensional computed tomography. *Imaging Sci Dent.* 2011; 41(2):79-84.