



CASE REPORT

Edgar Reyes¹.
Carmen Ayala².
Lizzete Díaz².

1. Servicio de Cirugía Maxilofacial del Hospital "Luz González Cosío", de los Servicios de Salud del Estado de Zacatecas. México.

2. Universidad Autónoma de Zacatecas. México.

Corresponding author: Carmen Ayala. Escandón. Calle 1ª de Mayo # 426-3. Centro Histórico. Zacatecas, Zacatecas, C.P. 98000, México. Phone: (51- 492) 9250940. E-mail: claescandon@yahoo.com

Receipt: 06/10/2015 **Revised:** 06/29/2015
Acceptance: 08/03/2015 **Online:** 08/03/2015

Parry-Romberg syndrome in a pediatric patient.

A case report.

Abstract: The Parry-Romberg syndrome is a rare degenerative disease of unknown etiology that has dental implications. It is characterized by a progressive hemifacial atrophy that appears in the early stages of life. It causes aesthetic, functional and psychological alterations, and has social implications for the patient. There is no definitive treatment for the Parry-Romberg syndrome. Systemic and immune alterations produce oral and maxillofacial manifestations, which need to be managed by specialized dental professionals. The aim of this paper is to do a literature review of the Parry-Romberg syndrome and describe the oral and clinical characteristics of this condition in a 12-year-old male pediatric patient, who had a history of neurological disorders and facial asymmetry on the left side. Dentists require an adequate knowledge of the clinical and dental characteristics of this syndrome. With early diagnosis and appropriate surgical and orthodontic treatment at an early age, they can improve the quality of life of patients and minimize invasive long-term effects.

Keywords: *Parry-Romberg syndrome, Facial asymmetry, Progressive facial hemiatrophy, Oral manifestations.*

DOI: 10.17126/joralres.2015.054.

Cite as: Reyes E, Ayala C & Díaz L. Parry-Romberg syndrome in a pediatric patient. A case report. *J Oral Res* 2015; 4(4): 282-286.

INTRODUCTION.

Described in 1825 by Caleb Parry and in 1846 by Moritz Romberg, the Parry-Romberg syndrome or Progressive Hemifacial Atrophy, as Eulemberg¹ coined the term, is a rare degenerative condition characterized by a generally slow and progressive unilateral atrophy of facial tissues, affecting the subcutaneous fatty tissue, connective tissue, skin, muscle and bone^{2,3}.

It has a higher prevalence in women (3:1) and occurs during the first two decades of life. The syndrome progresses for several years and then it reaches a period of stability⁴. Its prevalence is estimated at 1/700,000 individuals⁵. Its etiology is unknown and several hypotheses have been proposed: a manifestation of localized scleroderma⁶; an imbalance in fat metabolism; trauma; viral infections; endocrine disturbances, autoimmunity, and genetic factors⁷.

Clinically, it is characterized by a marked unilateral facial asymmetry; however, 5% and 10% of cases being bilateral have also been reported⁸. The asymmetry is preceded by a change in epidermal hue, by hyperpigmentation or depigmentation. The affected area usually becomes tense and compact, extending to the neck and to the side of the body, accompanied by other manifestations such as: alopecia, loss of eyelashes and eyebrows.

There are other symptoms such as trigeminal neuralgia, facial paresthesia, headaches, contralateral epilepsy and enophthalmos (neurological and ophthalmological manifestations), which can occur frequently in patients with this syndrome⁹. The intraoral soft tissues and muscles of mastication may not be affected, so their basic functions are not affected either. However, dental exposure caused by problems on the lips, deviation of dental midline and lingual atrophy may

occur. Facial muscles are thinned, but keep their function. Manifestations in bones or cartilages can be observed, especially when the syndrome occurs at an early age.

Between 36.6% and 53.6% of patients with Parry-Romberg syndrome have linear scleroderma or “coup de sabre”¹⁰ located in the frontal region, from the eyebrows to the scalp. They are considered a clinical-pathological variant of the same condition. Besides the fact that sometimes the two diagnoses coexist, they also coincide with the age of onset and the course of the syndrome. Histologically a fatty tissue atrophy and fibrosis of the skin are observed.

In the case of scleroderma it has been reported a massive lymphocytic inflammatory infiltration around surface vessels and deep plexuses of the skin, with a hardening of the skin caused by excessive collagen formation.

Pathophysiologically, some authors have proposed that the syndrome may be caused by an inflammatory meningoencephalic condition associated with a vasculitis; others, a chronic disorder related to vasomotor hyperactivity of the sympathetic nervous system¹¹.

Diagnosis can be made clinically if the patient has facial asymmetry, based on skin characteristics and soft tissue findings. If there are neurological symptoms a MRI and a CT scan should be performed as diagnostic aids. The Parry Romberg syndrome and scleroderma require a similar treatment, based on antibiotics and antimalarials (chloroquine and hydroxychloroquine); for severe cases, cyclophosphamide, cyclosporine and corticosteroids are suggested.

The aesthetic treatment is not recommended until the syndrome is stable. Surgical-aesthetic procedures include silicone implants, fat, skin and bone/cartilage grafting.

Regarding the dental aspects, the teeth on the affected side are smaller and have shorter roots^{7,12,13}.

The aim of this paper is to describe the clinical and dental characteristics of the Parry-Romberg syndrome in a male pediatric patient.

CASE REPORT .

12- year-old male patient treated at the pediatric unit at Hospital General “Luz Gonzalez Cosío” in Zacatecas, Mexi-

co, showing changes of symmetry in his skull and face with six months of evolution. The mother says his son suffers from oppressive headache.

Physical examination showed asymmetry on the left side with an increase in the depth of the nasolabial folds, appa-

Figure 1. Hemifacial atrophy on the left side with apparent sinking of structures on the affected hemiface.

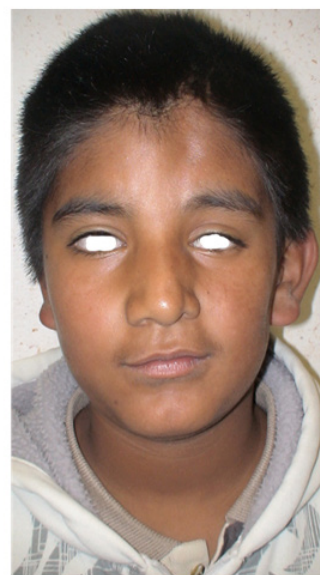

Figure 2. Patient does not show hyperpigmentation or depigmentation in the neck.

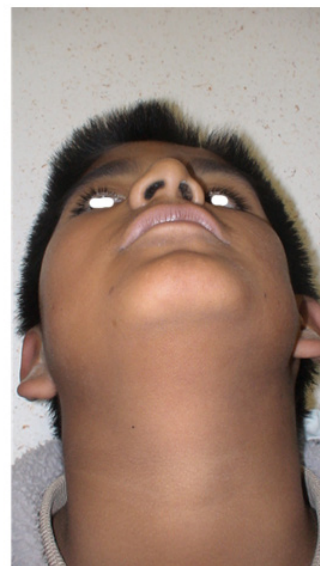

Figure 3. Short roots and pronounced curve of Spee on the affected side.

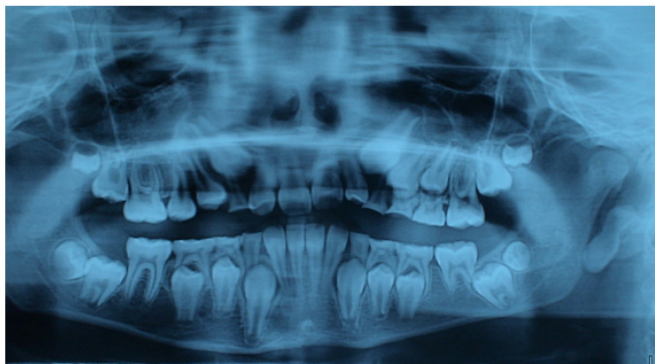
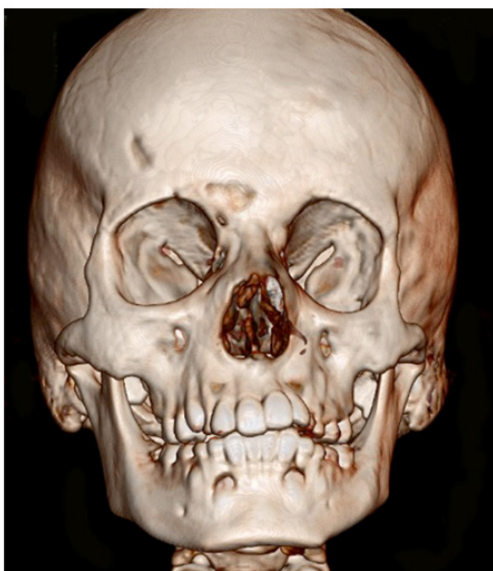

Figure 4. Tomography with 3D reconstruction showing a reduction in the size of facial bones and skull on the left side.



rent sinking of the structures on the left side of the face, thinning of the skin from the temporary area to the lower border of the mandible, without altering the function of the muscles in the affected area. (Figure 1) A depressed groove at the middle frontoparietal area extending toward the scalp, causing hair loss is observed.

The patient showed symmetrical tendon reflexes. Cognitive functions and language are normal. Enophthalmos with prominent brows and deviation of the outer corner of the eye and of the lip were observed.

Hyperpigmentation or depigmentation in the neck as described by various authors was not observed. (Figure 2). The patient was referred to the dental and maxillofacial surgery unit to undergo clinical examination and imaging studies of the facial bones with 3D reconstruction.

Intraoral examination revealed pigmentation of left attached gingiva, maxillary and mandibular depression on the left side, with loss of continuity of the ramus.

Anterior walls showed no evidence of alterations, atrophy or deviations of the soft tissues; mixed dentition with 24 teeth, dental midline deviated 4mm to the left, unilateral class II canine and molar relationship, horizontal overbite of 6.5mm and vertical overbite greater than 50%. The curve of Spee is mild on the right side and severe on the left, which causes the left temporomandibular joint to dislocate when opening the mouth.

The orthopantomography shows short tooth roots on the affected side (Figure 3).

The scan of the skull and facial bones with 3D reconstruction confirms the deformation of the left bone, affecting bone and showing a decrease in the posterior region of the eye; a reduction of the size of the facial bones and skull on the left side, affecting frontal and temporal bones on the same side, cheek bone and jaw. (Figure 4) Midline of frontal bone shows a highly marked "coupe de sabre".

Deviation of the bones of the nose to the left side, marked depression at the level of the canine eminence and malocclusion of teeth 21 and 22 were also observed.

The maxillofacial surgery unit refers the patient to specialists in pediatric dentistry to treat the condition coordinately together.

The main treatment will be in charge of the maxillofacial surgery team at a later stage. Gonadotropin tests are not requested because the patient is in pubertal development.

DISCUSSION.

The Parry-Romberg syndrome is a rare disorder, with a higher prevalence in females, and a long evolution during

the first 20 years of life¹⁴. The patient presented in this study had a unilateral disorder involving the abovementioned tissues, bone and intraoral soft tissues, especially in the tongue and lips.

There are cases of late-onset of the disorder, some with significant differences in the severity of the symptoms, with a serious affectation of facial tissues. It has been suggested that the degree of deformity may depend on the duration of the syndrome¹⁵. In this particular case and up to the date of this report, the alteration on the left side of the patient's face has been mild, with bone and intraoral tissue atrophy, and dental malocclusion.

Neurologic abnormalities associated with Parry-Romberg syndrome have been well documented¹⁶. Despite the fact that the patient's exams did not show any kind of brain injuries, he did suffer from oppressive headache, and is currently under treatment for that condition.

The patient also suffers from enophthalmos on the left side of his face. Enophthalmos are caused by the loss of peripheral adipose tissue of the eyeball¹⁷.

In order to restore function and avoid potential damage to the temporomandibular joint, malocclusion (crowding, pronounced curves of Spee, and deviation of the dental midline) caused by this pathology should be corrected. The patient received basic dental treatment before undergoing treatment to correct malocclusion.

Síndrome de Parry-Romberg en paciente pediátrico. Informe de caso.

Resumen: El síndrome de Parry-Romberg es una rara enfermedad degenerativa de etiología desconocida con implicaciones odontológicas. Se caracteriza por una atrofia progresiva que aparece a temprana edad, generalmente hemifacial. Tiene alteraciones estéticas, funcionales, psíquicas y sociales, no existiendo un tratamiento definitivo. Las manifestaciones orales y maxilofaciales de este síndrome son parte de una afectación sistémica e inmunológica, lo cual resalta la necesidad de su conocimiento y manejo por parte de los profesionales de la odontología. El objetivo de este reporte es describir las características clínicas y orales

The reduction in soft tissues can be observed on the CT. It helps to distinguish between Parry-Romberg syndrome and other disorders such as atrophy of the salivary glands or facial and chewing muscles paralysis, which could also result in facial asymmetries. Changes in bone tissue on the left side of the patient's face were observed¹⁸.

The replacement of lost tissue can be performed surgically. Grafts are preferred instead of implants, because they have a lower rate of recession of tissues, and produce a lower local and systemic inflammatory response¹⁹.

In this case it was decided to refer the patient to the pediatric dental service to receive basic dental treatment because he was in pubertal development²⁰. Subsequently he will be referred to the orthodontic and maxillofacial unit to continue with his treatment.

CONCLUSION.

The Parry-Romberg syndrome when detected at an early age should be treated by a multidisciplinary pediatric team, supported by methods of differential diagnosis and aimed at minimizing the effects produced in the skull and dentofacial area. In this case, the patient was referred to a pediatric dental service to receive basic treatment. The use of 3D imaging allows specialists to fully identify the characteristics of the disease and provide early intervention, reducing invasive long-term effects.

del Síndrome de Parry-Romberg en un paciente pediátrico masculino de 12 años de edad con antecedentes neurológicos que presenta una asimetría facial izquierda, presentado en conjunto una revisión bibliográfica de este síndrome. Las características clínicas y dentales de este síndrome como parte de una afectación sistémica requieren de un adecuado conocimiento por parte del profesional dental, el cual con un diagnóstico precoz y un adecuado tratamiento quirúrgico y ortodóntico a temprana edad para mejorar la calidad de vida del paciente y minimizar los efectos invasivos a largo plazo.

Palabras clave: *Síndrome de Parry-Romberg, Asimetría facial, Atrofia hemifacial progresiva, Manifestaciones orales.*

REFERENCES.

1. Longo D, Paonessa A, Specchio N, Delfino LN, Claps D, Fusco L, Fariello G. Parry-Romberg syndrome and Rasmussen encephalitis: possible association. Clinical and neuroimaging features. *J Neuroimaging*. 2011;21(2):188–93.
2. Pinheiro TP, Silva CC, Silveira CS, Botelho PC, Pinheiro Md, Pinheiro JdeJ. Progressive Hemifacial Atrophy--case report. *Med Oral Patol Oral Cir Bucal*. 2006;11(2):E112–4.
3. Kumar AA, Kumar RA, Shantha GP, Alogopinathan G. Progressive hemifacial atrophy - Parry Romberg syndrome presenting as severe facial pain in a young man: a case report. *Cases J*. 2009;2:6776.
4. Budrewicz S, Koszewicz M, Koziorowska-Gawron E, Szewczyk P, Podemski R, Sotwinski K. Parry-Romberg syndrome: clinical, electrophysiological and neuroimaging correlations. *Neurol Sci*. 2012;33(2):423–27.
5. Dalla G, Colombo B, Dalla D, Martinielli V, Comi G. Parry Romberg Syndrome associated with chronic facial pain. *J Clin Neurosci*. 2013;20(9):1320–22.
6. Baca SIM, Merino JE, Pérez DA. Esclerodermia localizada: corrección mediante trasplante autólogo de grasa. *Comunicación de seis casos. Dermatol Rev Mex*. 2013;57(1):60–3.
7. Devani P, Lal H, Thakral A. Parry-Romberg Syndrome: A Case Report. *Neurology*. 2014;4(1):67–70.
8. Khan M, Khan M, Negi R, Gupta N. Parry Romberg syndrome with localized scleroderma: A case report. *J Clin Exp Dent*. 2014;6(3):e313–6. [PubMed]
9. Nasser O, Greiner K, Amer R. Unilateral optic atrophy preceding Coats Disease in a girl with Parry-Romberg syndrome. *Eur J Ophthalmol*. 2010;20(1):221–23.
10. Doolittle DA, Lehman VT, Schwartz KM, Wong-Kisiel LC, Lehman JS, Tollefson MM. CNS imaging findings associated with Parry-Romberg syndrome and en coup de sabre: correlation to dermatologic and neurologic abnormalities. *Neuroradiology*. 2014;57(1):21–34.
11. Paprocka J, Jamroz E, Adamek D, Marszał E, Mandera M. Difficulties in differentiation of Parry-Romberg syndrome, unilateral facial sclerodermia, and Rasmussen syndrome. *Childs Nerv Syst*. 2006;22(4):409–15.
12. Rangare AL, Babu SG, PThomas PS, Shetty SR. Parry-romberg syndrome: a rare case report. *J Oral Maxillofac Res*. 2011;2(2):e5.
13. Sujatha SR, Devaraju D, Kunal A. Parry Romberg syndrome: Report of two cases with rare dental and skeletal findings. *e-J Dent*. 2012;2(3):212–15.
14. El-Kehdy J, Abbas O, Rubeiz N. A review of Parry-Romberg syndrome. *J Am Acad Dermatol*. 2012;67(4):769–84.
15. González ME, Cruz Y, García B, Vergara L, Mena L. Parry-Romberg's syndrome: View of its treatment. *Rev Cubana Estomatol*. 2005;42(2):1–7.
16. Amaral TN, Peres FA, Lapa AT, Marques-Neto JF, Appenzeller S. Neurologic involvement in scleroderma: a systematic review. *Semin Arthritis Rheum*. 2013;43(3):335–47.
17. González NTC, Linares LEH, Escobar PCA, Barrios MF. Síndrome de Parry-Romberg o hemiatrofia facial progresiva. Reporte de un caso. *Rev Ciencia Odont*. 2012;9(1):56–63.
18. Al-Aizari NA, Azzeghaiby SN, Al-Shamiri HM, Darwish S, Tarakji B. Oral manifestations of Parry-Romberg syndrome: A review of literature. *Avicenna J Med*. 2015;5(2):25–28.
19. Scolozzi P, Herzog G. Total mandibular subapical osteotomy and le fort I osteotomy using piezosurgery and computer-aided designed and manufactured surgical splints: a favorable combination of three techniques in the management of severe mouth asymmetry in Parry-Romberg syndrome. *J Oral Maxillofac Surg*. 2014;72(5):991–99.
20. You KH, Baik HS. Orthopedic and orthodontic treatment of Parry-Romberg syndrome. *J Craniofac Surg*. 2011;22(3):970–73.