

Acute thrombosis of the superior vena cava associated with atrial tachycardia catheter ablation

A 44-year-old menopausal woman with cardiovascular risk factors treated with hormone replacement therapy was being evaluated due to nodular goiter with normal thyroid function.

She had a 3-year history of atrial tachycardia with palpitations and episodes of collapse associated with hypotension. During follow-up she was treated with beta blockers, group 1C antiarrhythmic drugs and sotalol, but was refractory to treatment. The patient continued presenting episodes of paroxysmal tachycardia requiring frequent hospitalizations. An echocardiogram showed normal left ventricular function, normal left ventricular dimensions, normal right chamber dimensions and function, and normal left atrial dimension. The heart valves had no abnormalities. The lab tests were normal. Functional tests ruled out myocardial ischemia as the cause of the arrhythmia. Radiofrequency catheter ablation of atrial tachycardia with three-dimensional navigation system was indicated due to the lack of response to medical treatment. An EnSite NavX system version 8.0 (St. Jude Medical, SJM) was used.

A duo-decapolar Livewire catheter (SJM) was inserted in the right atrium for mapping the crista terminalis. A quadripolar catheter was positioned in the His bundle and a Blazer 8-mm tip quadripolar ablation catheter with thermistor (Boston Scientific) was inserted for mapping and ablation. The anatomical reconstruction of the right atrium and of both venae cavae was performed. A programmed atrial stimulation protocol was conducted; intranodal reentry circuit and accessory pathway were ruled out, and atrial tachycardia was induced. During mapping of the automatic atrial tachycardia, the maximal precocity was identified in relation with the P wave at the level of the superior vena cava. Upon performing local activation time (LAT) mapping with the navigation system, the origin of the tachycardia was identified in the same place. The tachycardia was reproduced with stimulation protocols and had the same characteristics as the tachycardia presented by the patient. Nine radiofrequency energy applications were delivered to the area described and tachycardia was eliminated and could not be induced after rapid pacing and isoproterenol infusion. The patient was admitted to the coronary care unit for 24 hours without complications and was discharged.

Twenty-four hours later, she was admitted to the emergency department due to headache and chest pain propagating to the anterior cervical region, with vomiting and cyanosis of upper extremities and head. A contrast-enhanced computed tomography scan of the chest was performed to confirm the diagnosis of acute obstruction of superior vena cava. The scan showed a reduction of the superior vena cava lumen at

the level of its connection with the right atrium with a transverse diameter of 7 mm and endoluminal filling defect, and reflux of contrast into the azygos system. There was also a filling defect in the posterobasal and anterobasal arterial segmental branches of the right lower lobe artery and in the anterobasal arterial segmental branch of the left lower lobe artery, as well as mild pleural effusion and mild pericardial effusion (Figure 1).

The patient evolved with cardiogenic shock requiring orotracheal intubation, mechanical ventilation and vasoactive agents. The patient persisted with hypotension and poor distal perfusion. An urgent cavography was performed.

A complete obstruction of the proximal superior vena cava involving 100% of the lumen was observed. A pig tail catheter was introduced in the lumen and balloon angioplasty was performed. The success of the procedure was confirmed by intravascular ultrasound. The vessel was patent, without residual endoluminal filling defect. Hyper reflectivity was observed between hour 9 and 12 in the upper third of the structure visualized by endovascular ultrasound. Anticoagulation with heparin was started.

During hospitalization the hemodynamic parameters improved and the inotropic agents were stopped. The patient was extubated and did not present signs of brain injury. Two-dimensional Doppler echocardiography showed normal left and right ventricular function, normal wall motion, ejection fraction of 67%, mild tricuspid regurgitation and absence of pericardial effusion. A stenosis was observed in the superior vena cava with flow velocity of 1.5m/s (normal value < 0.8m/s). The patient started oral anticoagulation with K vitamin antagonists.

The neurological examination by imaging tests

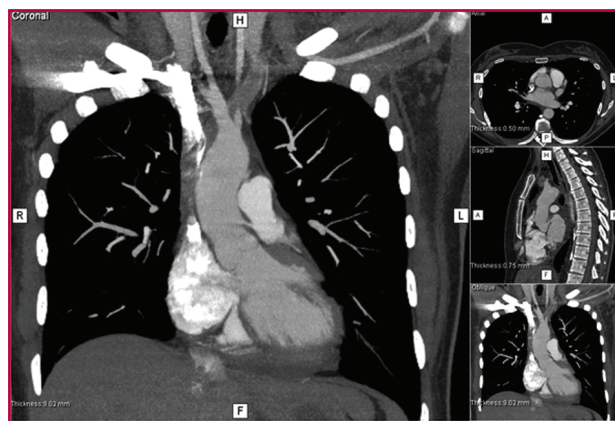


Fig. 1. Contrast-enhanced multi-detector row chest computed tomography. A complete obstruction of the proximal superior vena cava is observed, with a filling defect suggestive of luminal thrombus.

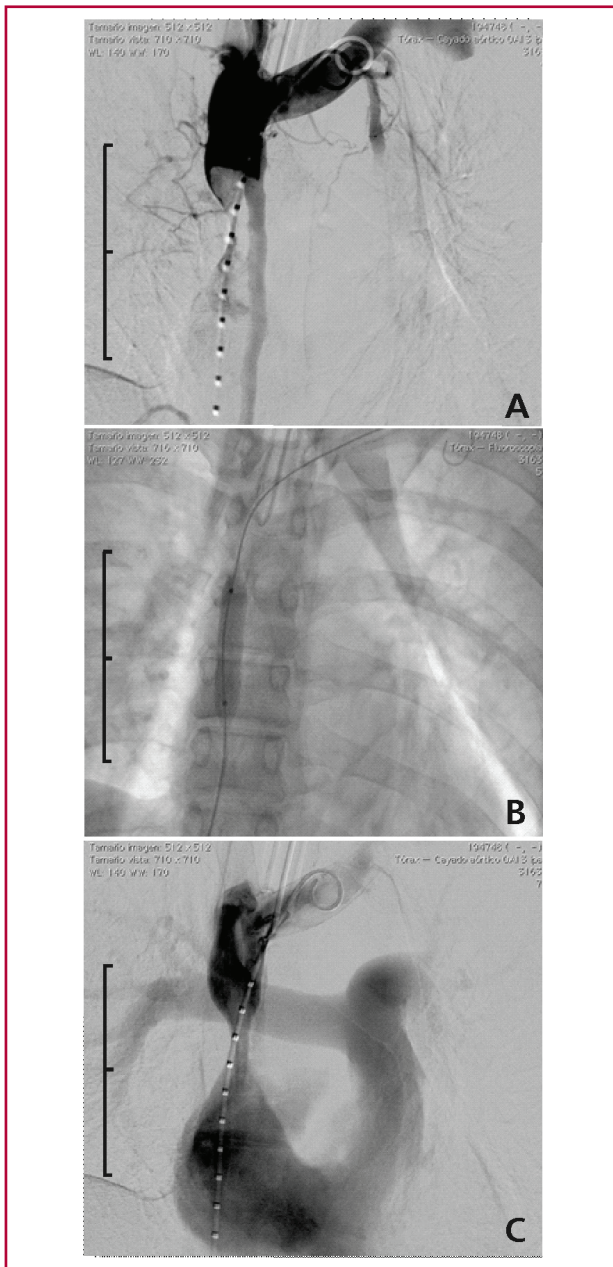


Fig. 2. Images obtained during cavography. **A.** The image shows a complete obstruction of the superior vena cava, the pig catheter inside the vein used for injection of contrast agent, and blood flow from the azygos system. **B.** Balloon angioplasty in the superior vena cava. **C.** Patent vena cava with passage of contrast agent to the right atrium and right ventricle, the pulmonary artery and its branches.

(magnetic resonance imaging and magnetic resonance angiography of the brain), transcranial Doppler ultrasound and funduscopy were normal.

The patient was discharged and is currently followed-up in the outpatient clinic.

Our patient was admitted after undergoing radiofrequency catheter ablation of atrial tachycardia using a three-dimensional navigation system. Twenty-four hours later, the patient presented acute thrombosis of

the superior vena cava with superior vena cava syndrome, requiring immediate balloon angioplasty, with favorable outcome.

Non-thrombotic etiology of superior vena cava syndrome is related with lung neoplasms. (1)

With the advent of intravascular devices, thrombosis has become an important cause of this syndrome (30%) particularly with dialysis catheters, portacaths, pacemakers and defibrillator devices. (2) However, there are no reports of thrombosis associated with invasive procedures as radiofrequency catheter ablation.

Undoubtedly, in this patient the early diagnosis and the adequate treatment were possible due to the history of the procedure on the superior vena cava, and the presence of clinical signs and symptoms. Congestion and swelling in the upper part of the body associated with signs of venous congestion and increased central venous pressures were consistent with this syndrome. The most common signs are collar of Stokes edema, distended veins of the nape and chest and facial swelling. The symptoms associated with high venous pressure are commonly present. Dypnea, laryngeal stridor, dysphagia and coughing are related with swelling of the larynx and pharynx. (3) Our patient rapidly evolved with hemodynamic impairment and consciousness deterioration. Cardiac tamponade was an alternative diagnosis that was ruled out.

The diagnosis was confirmed by computed tomography angiography with intravenous contrast injection, although magnetic resonance angiography is another option depending on its availability. (4)

The initial approach during acute thrombosis depends on the cause and on the severity of symptoms. The first step is intravenous anticoagulation. (5) Thrombolysis associated with anticoagulant therapy is recommended in most cases. Endovascular management, as balloon angioplasty, is also recommended, as we did with our patient. This procedure rapidly restores blood flow and vessel patency. The combination of both treatments increases the risk of bleeding without improving the long-term outcome. (6)

This is the first case report of superior vena cava thrombosis after radiofrequency catheter ablation of atrial tachycardia. This entity is infrequent but may develop due to the greater use of radiofrequency catheter ablation as treatment of cardiac arrhythmias.

Luis D. Barja^{MTSAC}, **Daniel F. Ortega**^{MTSAC},
Emilio A. Logarzo, **Analia G. Paolucci**,
Nicolás M. Mangani

Hospital Universitario Austral. Department of Cardiology.
Electrophysiology Laboratory. Pilar. Pcia. de Bs. As.
Clínica San Camilo. Department of Cardiology.
Electrophysiology Laboratory. CABA
e-mail: emiliologarzo@hotmail.com

REFERENCES

1. Lepper PM, Ott SR, Hoppe H, Schumann C, Stammler U, Bugalho A, et al. Superior vena cava syndrome in thoracic malignancies. *Respir Care* 2011;56:653-66. <http://doi.org/fkg9kn>

2. Rice TW, Rodriguez RM, Light RW. The superior vena cava syndrome: clinical characteristics and evolving etiology. *Medicine* 2006;85:37-42. <http://doi.org/cz2434>
3. Shaheen K, Alraies MC. Superior vena cava syndrome. *Cleveland Clinic Journal of Medicine* 2012;79:410-2. <http://doi.org/4xz>
4. Warren P, Burke C. Endovascular management of chronic upper extremity deep vein thrombosis and superior vena cava syndrome. *Semin Intervent Radiol* 2011;28:32-8. <http://doi.org/dc9pkq>
5. Kearon C, Akl EA, Comerota AJ, Prandoni P, Bounameaux H, Goldhaber SZ, et al. Antithrombotic therapy for VTE disease: Antithrombotic Therapy and Prevention of Thrombosis, 9th ed. American College of Chest Physicians Evidence-Based Clinical Practice Guidelines. *Chest* 2012;141(2 Suppl):e419S-94S.
6. Garcia Monaco R, Bertoni H, Pallota G, Lastiri R, Varela M, Beveraggi EM, et al. Use of self-expanding vascular endoprosthesis in superior vena cava syndrome. *Eur J Cardiothorac Surg* 2003;24:208-11. <http://doi.org/fd35xz>.

Rev Argent Cardiol 2015;83:347-349. <http://dx.doi.org/10.7775/rac.v83.i4.6015>

Torsades de pointes in amiodarone-associated acquired long-QT syndrome

Amiodarone was developed in Belgium in 1961 and became popular in Europe for the treatment of angina. Based on Dr. Bramah Singh's investigation, (1) the Argentine physician Dr. Mauricio Rosenbaum started using amiodarone for the treatment of ventricular and supraventricular arrhythmias with good outcomes. (2, 3) This drug is a class III agent in the Vaughan Williams classification, with class I, II and IV antiarrhythmic effects. Amiodarone produces bradycardia, prolongs myocardial action potential and delays ventricular repolarization. Due to these three pharmacological properties amiodarone prolongs the QT-interval, predisposing to torsade de pointes (TDP), a polymorphic ventricular tachycardia (VT), in about 1% of patients under this treatment. (4)

We report the case of a 69-year-old woman with history of hypertension, coronary artery disease with previous myocardial infarction requiring stent implantation in the proximal left anterior descending coronary artery. Figure 1 shows the electrocardiogram (ECG) after the angiography. A carotid endarterectomy was performed 5 months before due to an atheroembolic stroke. During the postoperative period, she presented atrial fibrillation with rapid ventricular response and amiodarone was added to her normal treatment. Her current treatment is ASA 325 mg/day, atenolol 50 mg bid, enalapril 20 mg bid and amiodarone 200 mg bid. One month before the event she attended

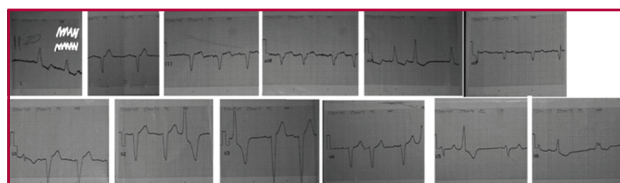

Fig. 1. Electrocardiogram before atrial fibrillation.

the outpatient clinic and an echocardiogram was performed showing: normal left ventricular dimensions, mildly increased wall thickness, normal left atrium and aorta, mild left ventricular dysfunction with an estimated ejection fraction of 50%, hypokinetic basal inferior and mid inferior segments and mitral inflow filling pattern of delayed relaxation (according to her age). Right chamber dimensions and right ventricular function were normal (TAPSE of 20 mmHg). A fibrocalcific trileaflet aortic valve with normal leaflet excursion was observed, with normal gradients and no regurgitation. The mitral valve was normal, without regurgitation, and the tricuspid and pulmonary valves were also normal. There was absence of pericardial effusion and both septae were intact.

She was attended at home by an emergency care system due to several episodes of syncope at rest. When the emergency system arrived, the patient was in cardiac arrest (CA) due to ventricular fibrillation (VF); advanced cardiopulmonary resuscitation was initiated (ACPR) and was defibrillated with 300 J with return of spontaneous circulation (ROSC). Another episode of CA with VF occurred while she was being transferred, requiring two 300 J shocks and 300 mg of intravenous amiodarone, with ROSC.

She was admitted to the emergency department, with a Glasgow score of 9 and breathing room air. Her blood pressure was 90/70, presenting slow capillary refill time and regular heart rhythm at 50 bpm. Another episode of CA in VF occurred at the emergency department. ACPR was initiated and required two 300 J shocks, with ROSC in sinus bradycardia at a heart rate of 40 bpm. Inotropic support was started with dobutamine and a loading dose of 300 mg of amiodarone was administered intravenously. The patient was sedated, intubated, received mechanical ventilation assistance and was transferred to the intensive care unit. The laboratory tests showed: BUN 1.37 g/L, creatinine levels 3.13 mg/dl, K⁺ 4.8 mEq/L, Na⁺ 138 mEq/L, Ca⁺⁺ 10.8 mg/dl, Mg⁺⁺ 1.9 mEq/L.

Coronary angiography was performed due to a diagnosis of electrical storm secondary to myocardial ischemia.

The ECG showed sinus bradycardia at a heart rate of 35 bpm, normal P-wave and PR interval, old inferior myocardial infarction and poor R wave progression from V1-V6; the QTc was 509 ms. In Figure 2, lead II shows the episode of self-limiting ventricular tachycardia (VT) of 16 beats with change in QRS polarity at 250 bpm and one ventricular triplet in V3.

A diagnosis of polymorphic VT in a patient with long QT-interval (TDP) was made. Amiodarone and inotropic agents were stopped and 2 g magnesium sulphate was administered intravenously. A Furman temporary pacemaker (Figure 3) was implanted and a unipolar lead stimulated the atria at 80 bpm with adequate capture and blood pressure of 120/80 mm Hg.

During the next 48 hours she did not present further episodes of TDP and pacing was stopped. The QT

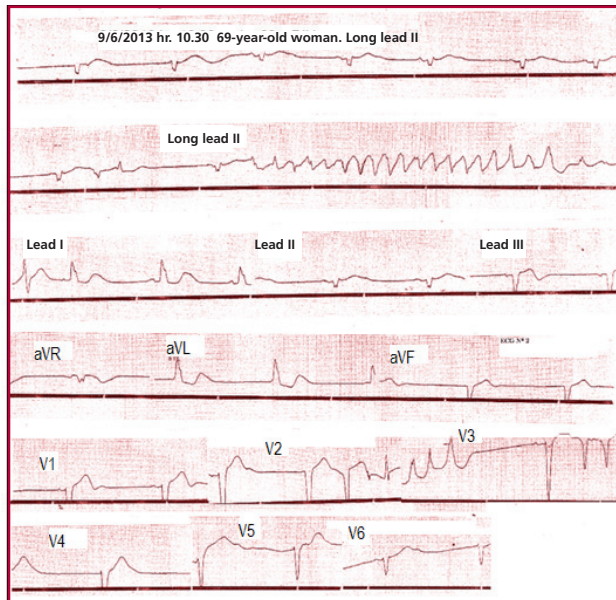


Fig. 2. Torsade de pointes.

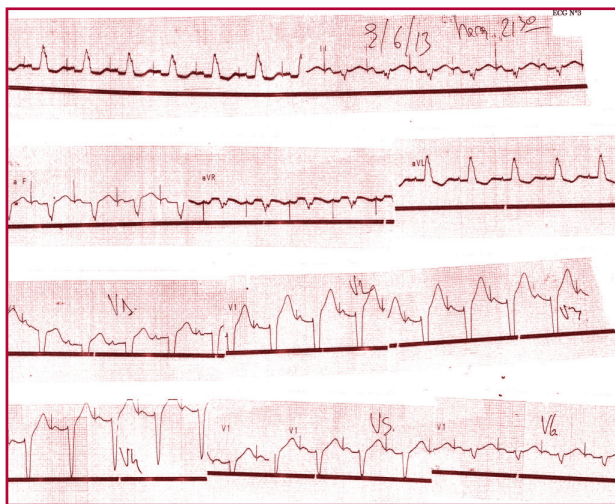


Fig. 3. Electrocardiogram after implanting a Furman pacemaker, showing atrial paced rhythm (unipolar pacing) with a heart rate of 80 bpm and 100% capture.

interval gradually returned to normal values. After 7 days of hospitalization in an internal medicine ward, the patient was discharged with sinus rhythm at 70 bpm, QTc of 440 ms and was followed-up in the outpatient clinic with favorable outcome.

Long QT syndrome (LQTS) refers to a group of channelopathies mainly affecting sodium and potassium channels and characterized by a dispersion of ventricular repolarization expressed in the electrocardiogram by a prolonged QT interval. It may be congenital or acquired. Several mutations have been identified distributed in 10 genes. The severe form of the disease is sporadic, but there are a number of common polymorphisms that may confer susceptibility to the

development of the disease when specific drugs are being administered. (5) Patients with long QT syndrome are predisposed to sudden death due to polymorphic VT (TDP). Torsade de pointes is a polymorphic VT associated with LQTS which may be abolished by increasing the heart rate. (6)

The name torsade de pointes describes a sequence of consecutive QRS complexes that then changes its polarity, like twisting around the isoelectric line. (6) Abnormal QTc values are ≥ 440 ms in men and ≥ 460 ms in women. (5) The susceptibility of suffering TDP-VF is higher if the QTc exceeds 500 ms. (4) Torsade de pointes with heart rates >220 bpm are more prone to degenerate into VF.

The factors contributing to prolong the QT interval are: drugs, electrolyte disorders (hypokalemia, hypomagnesemia, hypocalcemia), ischemia, myocarditis, severe bradycardia, T wave alternans, R-on-T phenomenon, female sex, intoxications (as cocaine or organophosphates) neurological disorders (stroke or subarachnoid hemorrhage.) and endocrine diseases (hypothyroidism or pheochromocytoma). (6)

In our patient, long QT was due to the administration of amiodarone after an episode of postoperative AF. Amiodarone is a Vaughan Williams class III antiarrhythmic drug which blocks potassium channels prolonging repolarization. Amiodarone produces bradycardia, prolongs myocardial action potential and delays ventricular repolarization. Due to these three pharmacological properties, amiodarone prolongs the QT-interval, predisposing to TDP, a polymorphic VT in about 1% of patients under this treatment. (4) Initially, our patient presented an episode of syncope evolving with cardiac arrest with shockable rhythm, probably due to TDP. As the patient had a history of coronary artery disease with stent implant to the left anterior descending coronary artery and repetitive episodes of cardiac arrest with shockable rhythm considered VF refractory to treatment, a diagnosis of electrical storm secondary to ischemia was made. After ROSC, a correct ECG analysis showed a QTc interval of 509 ms and a run of polymorphic VT at 250 bpm (both variables increase the probability of degenerating into VF); the diagnosis was then changed to TDP due to drug-induced LQTS. Kay et al. described that TDP is preceded by a sequence of long RR interval of the dominant cycle followed by a short extrasystolic interval with R-on-T phenomenon. This sequence was observed in our patient (Figure 2). Amiodarone was immediately withdrawn, magnesium sulphate was administered and a temporary pacemaker was implanted, with ventricular capture at 80 bpm. This treatment increased heart rate and shortened the QTc to 480 ms, with favorable outcome.

During the next 48 hours the patient did not present further episodes of TDP and pacing was stopped. The QT interval gradually returned to normal values. After 7 days of hospitalization in an internal medicine ward, the patient was discharged with sinus rhythm

at 70 bpm, QTc of 440 ms and was followed-up in the outpatient clinic with favorable outcome. In conclusion, TDP amiodarone-induced LQTS is an infrequent but severe condition requiring timely electrocardiographic diagnosis and specific treatment.

**Carlos Ferrando¹, Federico Rivero¹,
Federico Machado²**

¹ Emergency Department, Hospital Maciel,
Montevideo Uruguay

² Cardiologist. Sanatorio SEMM-Mautone - Sanatorio Cantegril,
Punta del Este, Uruguay
e-mail: sanocuore@gmail.com

REFERENCES

1. Singh BN, Vaughan Williams EM. The effect of amiodarone, a new anti-anginal drug, on cardiac muscle. *Br J Pharmacol* 1970;39:657-67. <http://doi.org/4zpz>
2. Rosenbaum MB, Chiale PA, Halpern MS, Nau GJ, Przybyski J, Levi RJ, et al. Clinical efficacy of amiodarone as an antiarrhythmic agent. *Am J Cardiol* 1976;38:934-44. <http://doi.org/cgigdc>
3. Rosenbaum MB, Chiale PA, Haedo A, Lazzari JO, Elizari MV. Ten years of experience with amiodarone. *Am Heart J* 1983;106:957-64. <http://doi.org/d6vcrp>
4. Goldenberg I, Moss A. Long QT Syndrome. *J Am Coll Cardiol* 2008;51:2292-300. <http://doi.org/cbz6vs>
5. Medeiros-Domingo A, Iturralde-Torres P, Ackerman MJ. Clínica y genética en el síndrome de QT largo. *Rev Esp Cardiol* 2007;60:739-52. <http://doi.org/drhrnz>
6. Torsade de Pointes, Fibrilación Ventricular y Diagnóstico Diferencial de las Taquicardias de QRS Amplio. En: Chou's. *Electrocardiografía en la Práctica Clínica*. 6.ª ed. Editorial Amolca; 2011. Cap 18:440-55

Rev Argent Cardiol 2015;83:349-351. <http://dx.doi.org/10.7775/rac.v83.i4.4791>

Non-compaction peripartum cardiomyopathy: just a coincidence?

The prevalence of non-compaction cardiomyopathy (NCC) is low; yet, its diagnosis is progressively increasing as a consequence of advances and use of the different diagnostic imaging techniques. It is characterized by a thin, compacted external layer and an extensive non-compacted internal layer, with prominent trabeculation. Although its pathogenesis is still controversial, the American Heart Association includes this condition as a primary genetic cardiomyopathy. The interruption of the myocardial compaction process which normally occurs during intrauterine development may play a role in its pathogenesis. The clinical presentation of NCC is variable; subjects may be completely free of symptoms and the diagnosis is incidentally made or may present heart failure, arrhythmias, thromboembolism or sudden death. (1)

Peripartum cardiomyopathy (PPCM) is defined as the development of heart failure in the last month of pregnancy or within 5 months of delivery in the absence of another etiology and in the absence of demonstrable previous heart disease. Its prevalence is very low and varies in different regions from 1 per 100 live births in Zambia and Nigeria to 1 per 3000 live

births in the United States. Although the etiology of PPCM is unknown, many potential causes have been proposed, including malnutrition, hormonal abnormalities, infections, abnormal immune response and abnormal response to increased hemodynamic burden of pregnancy. It is more frequent in black women, and in those with hypertension, diabetes, multifetal pregnancies and >30 years. (2)

We report the case of a patient who developed signs and symptoms of heart failure in the immediate peripartum period with complementary tests and morphologic criteria of NCC.

A 30-year-old woman complained of progressive dyspnea four months after delivery, with edema of the lower extremities, fever and bloody sputum. She reported a family history of sudden death in a 15-year-old brother and a 3-year old nephew. She had had five pregnancies and five uneventful deliveries, the last one in September 2011. Two months before consultation (on the second month after delivery) she began presenting edema of the lower extremities and progressive dyspnea in FC III. A few days before seeking medical assistance, she complained of fever and bloody sputum. At physical examination, she looked severely ill and presented tachypnea, tachycardia and fever. Blood pressure was 120/80; 2+ pitting edema in the lower extremities and 2/3 jugular engorgement were observed. The apex beat was laterally displaced and was palpable in early diastole. The first heart sound and the second heart sound were normal and a gallop third sound was heard. Crackles were heard at both lung bases; vesicular breath sounds were decreased and percussion produced a dull tone at the right lung base. The electrocardiogram showed sinus tachycardia and signs of left ventricular hypertrophy. The hematocrit was 32%. A right pulmonary effusion was observed in contrast-enhanced computed tomography scan, with areas of consolidation of the right middle lobe and anterior segment of the right lower lobe, and filling defects in the segmental branches of the pulmonary artery. A diagnosis of heart failure and pulmonary embolism was made. Oxygen therapy was administered, anticoagulant drugs were started and negative fluid balance was indicated, with favorable response. Transthoracic echocardiography showed spheroid left ventricular dilatation with areas of non-compacted myocardium in the mid inferior, apical inferior, mid lateral and apical lateral segments (end-systolic noncompacted-to-compacted ratio: 2.8) with severe left ventricular dysfunction (ejection fraction = 29%). The right ventricle was moderately dilated but with normal systolic function. Diastolic filling had a restrictive pattern and moderate mitral regurgitation and tricuspid regurgitation were observed (Figure 1). Gadolinium-enhanced cardiac magnetic resonance imaging confirmed the echocardiographic diagnosis of NCC, with absence of myocardial edema and late enhancement (a patchy pattern at the level of the septum suggestive of non-ischemic fibrosis). Therapy

was started with bisoprolol, enalapril, spironolactone, ivabradine and vitamin K antagonists. In the months following hospital discharge, the patient remained in FC III and was referred to other center (year 2012) to evaluate the possibility of heart transplantation. Her immediate family was evaluated and seven new cases of NCC were detected by echocardiography. By mid 2014, the patient returned to our outpatient clinic with marked improvement of her general status, without edemas and with dyspnea in FC I-II. A new echocardiogram performed at that time showed left ventricular dilatation with moderate left ventricular dysfunction (ejection fraction 44%, two-dimensional global longitudinal strain: -15%), moderate diastolic dysfunction (pseudonormal mitral filling pattern), and mild mitral and tricuspid regurgitation (Figure 2).

Non-compaction cardiomyopathy is characterized by its genetic heterogeneity and lack of correlation between genotype and phenotype. This suggests that, beyond genetic abnormalities, other not completely known factors are involved. Sporadic and familial forms have been described, with different patterns of inheritance: autosomal dominant, autosomal recessive or X-linked. Despite the increasing number of series published since 1990, the real prevalence of NCC and its mid and long-term outcome are little known. (3) On the contrary, PPCM is recognized as a non-genetic cardiomyopathy in most cases; yet, some cases have been reported in association with familial dilated cardiomyopathy. A recent pathophysiological mechanism has been described. A genetic abnormality decreases the antioxidant capacity and increases cathepsin D expression (proteolytic activity) and prolactin cleavage into its antiangiogenic and proapoptotic forms. A small study has demonstrated beneficial effects of bro-

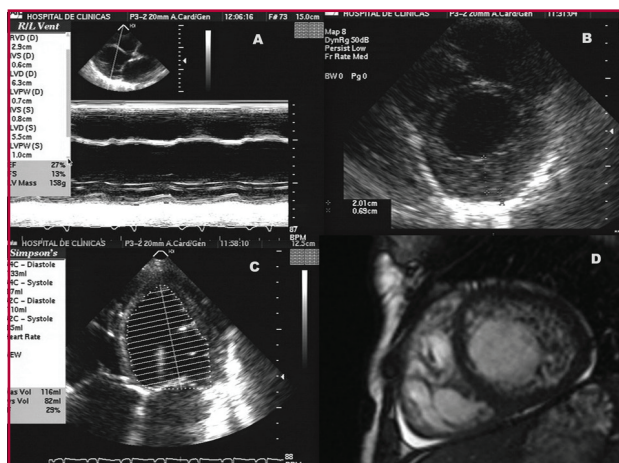


Fig. 1. Echocardiographic image showing left ventricular dilatation (A) and severe left ventricular dysfunction (B). Short-axis echocardiographic views (C) and magnetic resonance imaging (D) showing non-compacted myocardium.

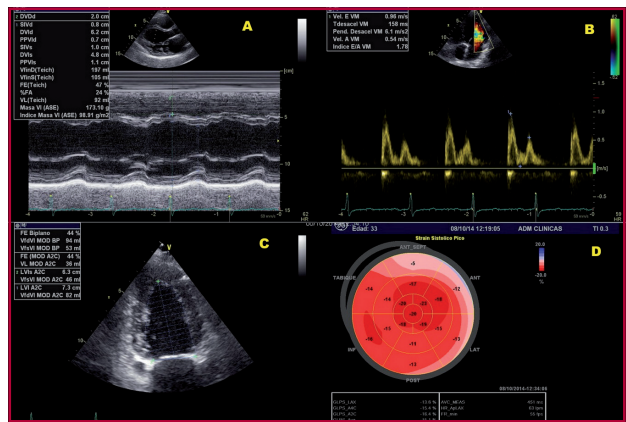


Fig. 2. Echocardiographic image showing left ventricular dilatation (A) with moderate diastolic dysfunction (B) and moderate left ventricular dysfunction (C)

mocriptine, a prolactin inhibitor. (4)

It seems clear that our patient had an asymptomatic form of NCC according to the morphological criteria described and the family history. However, there are some topics of interest to mention. Firstly, the patient had never complained of symptoms during her five previous pregnancies despite the hemodynamic burden associated. Symptoms (dyspnea and edema of the lower extremities) developed during the second month after delivery, when the hemodynamic overload had resolved, and, finally, systolic function and functional class improved in the following months. Although this may happen in patients with NCC, it is more common in those with PPCM. Since 2007, seven case reports of NCC in which the diagnosis was made during the peripartum period have been published. (5) Van Spaendonck-Zwarts et al. have recently described a higher prevalence of PPCM in women with history of familial dilated cardiomyopathy. (6) The interaction of metabolic phenomena characteristic of the pregnancy-delivery-puerperium period (probably due to imbalance between oxidative stress and antioxidant mechanisms) on a genetically predisposed myocardium might explain the occurrence of this condition in our patient.

Ariel K. Saad¹ MTSAC, Claudia N. Villalba², Manuel Vázquez Blanco³ MTSAC,

¹ Department of Cardiology, Hospital de Clínicas José de San Martín

² Department of Cardiology, Hospital de Pediatría "Prof. Dr. Juan P. Garrahan"

³ Chair of Internal Medicine.

Hospital de Clínicas José de San Martín
Ariel K. Saad - Av. Córdoba 2351 -
(C1120AAF) CABA, República Argentina
e-mail: aksaad@arnet.com.ar

REFERENCES

1. Almeida AG, Pinto FJ. Non-compaction cardiomyopathy. *Heart* 2013;99:1535-42. <http://doi.org/42p>
2. Elkayam U. Clinical characteristics of peripartum cardiomyopathy in the United States. Diagnosis, prognosis and management. *J Am Coll Cardiol* 2011;58:659-70. <http://doi.org/cgjd>

3. Oechslin E, Jenni R. Left ventricular non-compaction revisited: a distinct phenotype with genetic heterogeneity? *Eur Heart J* 2011;32:1446-56. <http://doi.org/d6vcrp>
4. Sliwa, K, Blauwet L, Tibazarwa K, Libhaber E, Smedema J, Becker A, et al. Evaluation of bromocriptine in the treatment of acute severe peripartum cardiomyopathy: A Proof-of-Concept Pilot Study. *Circulation* 2010;121:1465-73. <http://doi.org/cbz6vs>
5. Patel C, Shirali G, Pereira N. Left ventricular noncompaction mimicking peripartum cardiomyopathy. *J Am Soc Ecocardiogr* 2007;20:1009. e9-e12. <http://doi.org/drhnrz>
6. Van Spaendonck-Zwarts KY, van Tintelen P, van Veldhuisen DJ, van der Werf R, Jongbloed JD, Paulus WJ, et al. Peripartum cardiomyopathy as a part of familial dilated cardiomyopathy. *Circulation* 2010;121:2169-75.

Rev Argent Cardiol 2015;83:351-353. <http://dx.doi.org/10.7775/rac.v83.i4.5441>

Late surgical correction of anomalous origin of the left pulmonary artery and ventricular septal defect

Hemitruncus is defined as anomalous origin of one branch of the pulmonary artery from the ascending aorta with the other branch arising normally from the pulmonary trunk. (1) This acyanotic heart defect with increased pulmonary blood flow with manifestations of severe pulmonary artery hypertension (PAH) and heart failure should be corrected at early stages of life. We describe the case of a 9-month-old infant with late diagnosis of anomalous origin of the left pulmonary artery emerging from the aorta, associated with ventricular septal defect, who underwent successful corrective surgery.

A 9-month-old infant was admitted with heart failure. She had a history of hospitalizations due to recurrent pneumonias. She had signs of protein-energy malnutrition, marked hypernea, subcostal and low intercostal retractions, harsh vesicular breath sounds and rhonchi. Cardiovascular auscultation revealed loud P2, ventricular gallop, and an early and midsystolic murmur grade III/VI heard at Erb's point radiated to the left and right paraesternal borders. An early diastolic murmur of pulmonary regurgitation was heard at the pulmonic area (Graham Steell murmur). The amplitude of peripheral pulses was low. Chest X ray showed a cardiothoracic ratio of 0.68, bilateral hilar congestion, increased pulmonary blood flow specially in the right pulmonary field and peripheral vessel oligemia in the left pulmonary field. The electrocardiogram showed sinus rhythm, right axis deviation (+120°), increased R wave amplitude in V1-V2 and deep S waves in V5-V6 (right Sokolow-Lyon index). The echocardiogram defined the anomalous origin of the left pulmonary artery emerging from the ascending aorta, with severe PAH with supra-systemic pulmonary artery pressures, biventricular dilatation and moderate left ventricular dysfunction with ejection fraction of 43%. A diagnostic cardiac catheterization was performed which confirmed the severity of PAH estimated by transthoracic echocardiography (Figures 1 A and B). Vasoreactivity testing

demonstrated a discrete reduction of pulmonary artery pressures and pulmonary resistance index. The patient underwent corrective surgery considering the presence of refractory heart failure and severe but potentially reversible PAH. The procedure consisted of the reinsertion of the left pulmonary artery in the main pulmonary artery and closure of the ventricular septal defect with a fenestrated patch. During the postoperative period, the institutional protocol for PAH was initiated, which includes intravenous high-dose sildenafil and epoprostenol associated with furosemide, spironolactone, captopril and carvedilol for left ventricular dysfunction. The patient evolved with favorable outcome and is followed-up at the outpatient clinic. A computed tomography angiography performed after 6 months of surgery confirmed the effective surgical correction (Figure 2 A and B) and serial echocardiograms show normalization of ventricular dimensions, pulmonary artery pressures and left ventricular function.

The anomalous origin of one of the pulmonary arteries from the aorta was initially described by Fraentzel in 1868, and is commonly associated with other congenital heart defects as tetralogy of Fallot, ventricular septal defect, transposition of the great vessels and subvalvular aortic stenosis. (2)

The largest case series published on this heart disease is attributed to Kutsche and Van Mierop in 1988, who described 108 patients, 89 with anomalous origin of the right pulmonary artery and 19 of the left pulmonary artery emerging from the aorta. (3) Other authors report that the anomalous origin of the right pulmonary artery is 4 to 8 times more frequent than the involvement of the left pulmonary artery. (1)

The embryological development of these varieties of hemitruncus is different: anomalous origin of the right pulmonary artery is thought to be secondary to incomplete or delayed leftward migration of the right sixth aortic arch, while the defect of the left pulmonary artery is considered as failure in the development of the left sixth aortic arch and persistence of the fifth aortic arch. (4)

The pathophysiology of PAH in this congenital heart disease is due to two mechanisms: one of the pulmonary artery branches is subjected to systemic pressure from the ascending aorta and the remaining artery receives the entire output of the right ventricle. (1)

Estimating pulmonary artery pressures and pulmonary vascular resistance index is crucial to define the possibility of surgical correction. In the presence of ventricular septal defect, the traditional calculations by the Fick method may fail and other variables should be analyzed, as manifestations of heart failure, pulmonary venous flow velocity entering the left atrium and the presence of cardiomegaly in the chest X-ray. In these cases, the estimation of pulmonary artery flow and pulmonary vascular resistance index should be calculated for each pulmonary artery with cardiac

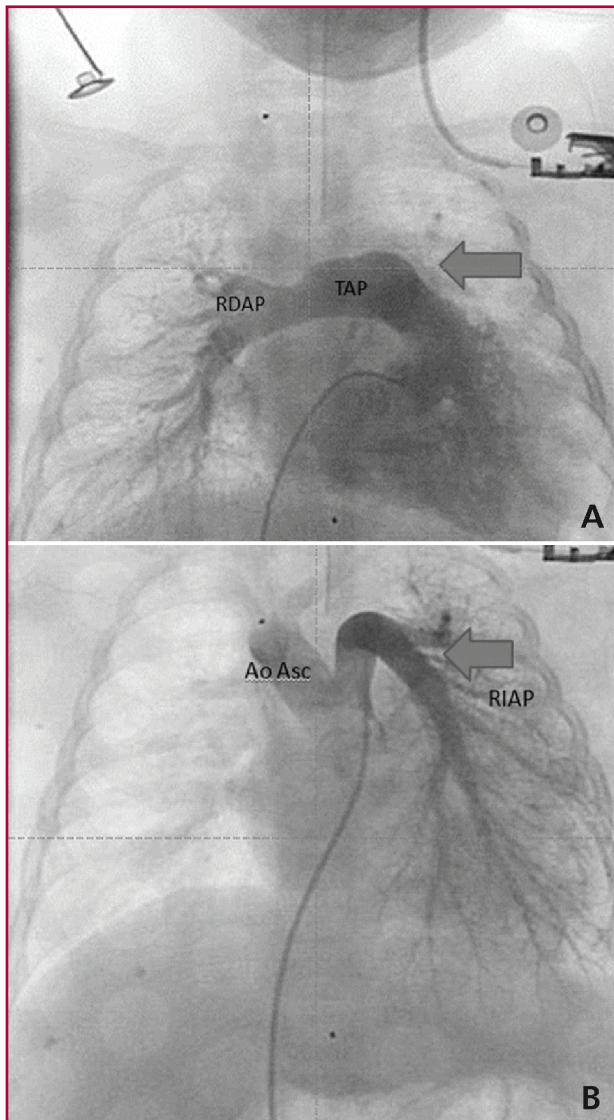


Fig. 1. A. Coronary angiography image showing the pulmonary artery trunk (TAP) emerging from the right ventricle. The arrow shows absence of the left pulmonary artery branch. RDPA: Right pulmonary artery **B.** Coronary angiography image with the left pulmonary artery (RIAP) emerging from the ascending aorta (Ao As). The arrow shows the left pulmonary artery branch.

magnetic resonance imaging.

Several techniques are described with favorable outcomes in terms of survival. Nathan et al. reported survival of 93% at 20 years in 16 patients operated on, and with almost no need of reinterventions. However, early and timely diagnosis is crucial in this rare congenital heart defect to prevent the development of irreversible PAH, as surgery is not recommended in these cases and is cause of death. (5)

The success achieved with corrective surgery in this patient is very important for our institution, considering that the diagnosis was late and nitric oxide was not available for the treatment of PAH in the postoperative period.

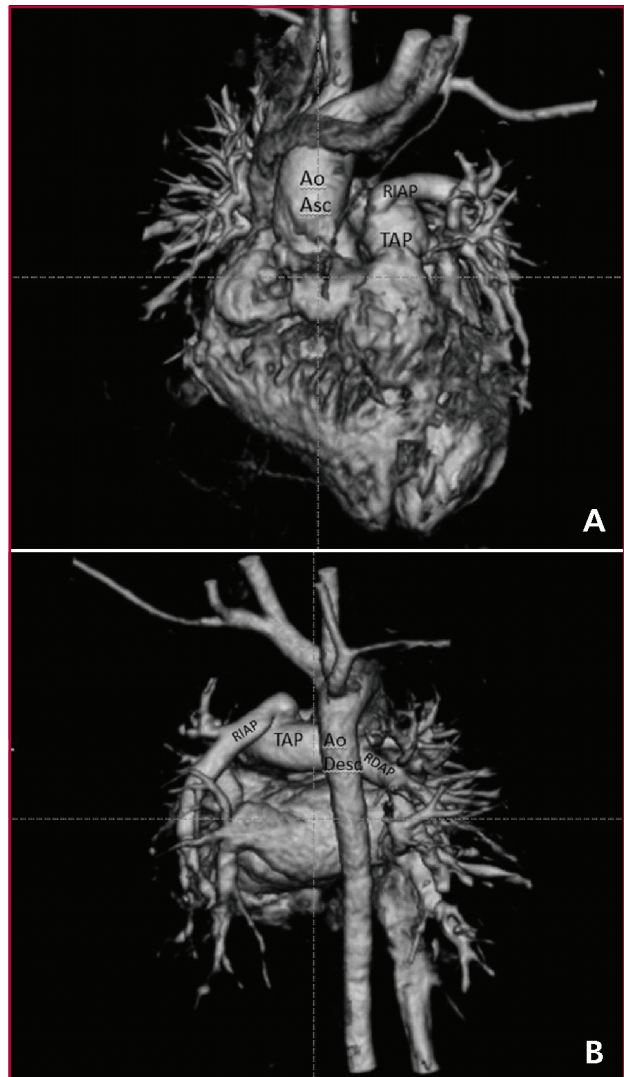


Fig. 2. A. Volume reconstruction of computed tomography coronary angiography (oblique view), showing the surgical correction with the left pulmonary artery branching emerging from the pulmonary artery trunk. Ao Asc: Ascending aorta. RIAP: Left pulmonary artery. TAP: Pulmonary artery trunk. **B.** Volume reconstruction of computed tomography coronary angiography (posterior view), showing the surgical correction with native right pulmonary artery branch emergence and the corrected origin of the left pulmonary artery from the pulmonary artery trunk. As Desc: Descending aorta. RDAP: Right pulmonary artery. RIAP: Left pulmonary artery. TAP: Pulmonary artery trunk

**Hiram Tápanes Daumy¹, Francisco Díaz Ramírez¹,
Maylin Peña Fernández², Lysmara Senra Reyes¹**

¹ Cardiocentro Pediátrico "William Soler". Havana, Cuba.
² Hospital Pediátrico "Juan Manuel Márquez". Havana, Cuba.
Hiram Tápanes Daumy. Cardiocentro Pediátrico "William Soler"
Ave. 43 N° 1418 esquina A Calle 18 - CP 11900
Ciudad de La Habana, Cuba
e-mail: hiram@cardiows.sld.cu, hiramtapanes@infomed.sld.cu

REFERENCES

1. Talwar S, Meena A, Ramakrishnan S, Choudhary SK, Airan B. Hemi-truncus with ventricular septal defect in a 6-year-old child. *Ann Pediatr Cardiol* 2013;6:194-6. <http://doi.org/42q>

2. Fraentzel O. Ein Fall von abnormer communication der aorta mit der arteria pulmonalis. *Virchows Arch Pathol* 1868;43:420-6. <http://doi.org/c47txp>
3. Kutsche LM, Van Mierop LH. Anomalous origin of a pulmonary artery from the ascending aorta: associated anomalies and pathogenesis. *Am J Cardiol* 1988;61:850-6. <http://doi.org/cm4dzk>
4. Aru GM, English WP, Gaymes CH, Heath BJ. Origin of the left pulmonary artery from the aorta: embryologic considerations. *Ann Thorac Surg* 2001;71:1008-10. <http://doi.org/c9t7rp>
5. Nathan M, Rimmer D, Piercey G, del Nido PJ, Mayer JE, Bacha EA, et al. Early repair of hemitruncus: excellent early and late outcomes. *J Thorac Cardiovasc Surg* 2007;133:1329-35. <http://doi.org/dmnx8m>

Rev Argent Cardiol 2015;83:353-355. <http://dx.doi.org/10.7775/rac.v83.i4.5338>

Efficacy of multielectrode Array catheter for ventricular tachycardia ablation in a patient with electrical storm

Ventricular arrhythmias are one of the major causes of mortality in patients with coronary artery disease. In this group of patients, ventricular tachycardia (VT) is produced by a reentrant mechanism due to the presence of a fibrotic scar, and may appear even decades after myocardial infarction (MI). (1) Despite the important advances in the treatment of MI, the risk of VT in the population with coronary artery disease is still an important issue in clinical practice. Antiarrhythmic agents and implantable cardioverter defibrillator (ICD) devices are the cornerstone in the management of ventricular arrhythmias. (2) These therapies are far from being infallible and may present significant adverse events. (3) Patients implanted with an ICD may experience significant physical and psychological deterioration due to repetitive delivery of shocks.

Catheter ablation of VT may have a significant impact in patient's quality of life by alleviating symptoms, reducing the requirement of antiarrhythmic drugs and the number of ICD shock deliveries. However, this procedure may result difficult because the arrhythmia is poorly tolerated in many occasions and hemodynamic decompensation make collection of point-by-point electrograms impossible.

The use of the multielectrode Array catheter as a diagnostic tool is becoming more frequent in our environment. (4) This noncontact device consists of 64 electrodes deployed on an inflatable mesh that is suspended in the selected heart chamber to treat the arrhythmia. The catheter records electrograms from multiple sites within a single cardiac chamber and is capable of determining the precise site of origin of the arrhythmia from a single run of tachycardia. We report the case of a 69-year-old male patient treated in our hospital, with history of hypertension, dyslipidemia, and former smoking. His usual creatinine levels were 1.4 mg/dl (creatinine clearance measured by MDRD of 56 ml/min/1.73 m²). Eighteen-years ago he presented myocardial infarction of the inferior wall and received medical treatment. In 2011 he complained of progressive angina and underwent myocardial revasculariza-

tion surgery requiring implantation of four bypass grafts. At that time, the echocardiogram revealed severe left ventricular dysfunction with abnormal contraction in the inferior and posterior wall. Six months later he was admitted to the emergency department with sustained VT with hemodynamic instability. An ICD device was implanted. During follow-up, three appropriate shocks were delivered due to VT: Amiodarone 400 mg/day and carvedilol 25 mg bid were initiated.

The patient was admitted to the emergency department due to nausea, dizziness, abdominal pain and dyspnea of one-week duration. He reported two shock ICD deliveries. He denied fever or fever-like symptoms. He did not complain of angina and did not modify his usual medication.

He was evaluated by a cardiologist due to heart failure and signs of low cardiac output. At the physical examination, the patient looked severely ill, with heart rate of 140 beats per minute, tachypnea, hypotension, poor distal perfusion and oxygen saturation of 75% breathing room air. He did not present fever. Crackles were heard over both lung bases and middle fields.

The electrocardiogram showed a regular tachycardia of 140 beats per minute with wide QRS complexes (Figure 1), that was interpreted as sustained VT with hemodynamic instability. As the ICD was programmed to treat VT with heart rates >150 beats per minute, therapy with external cardioversion with a 200 J biphasic shock was decided.

The laboratory tests were within normal ranges. The chest X-ray showed signs of pulmonary congestion. Interrogation of the ICD device showed that the patient had presented three appropriate shocks to treat VT within the past 48 hours.

Furosemide was administrated and a negative fluid balance was achieved; amiodarone and lidocaine were given intravenously. Coronary angiography was performed to rule out acute coronary syndrome, and no new coronary artery stenoses were observed. Blood and urine cultures were negative. The patient presented several episodes of VT with hemodynamic instability and other symptomatic, short-lasting episodes despite the treatment. During hospitalization, three ICD shocks were delivered in the range of VT detection.

A diagnosis of electrical storm in a drug-refractory patient with hemodynamic instability was made and VT catheter ablation was indicated using a multielectrode Array catheter. Ventricular tachycardia was induced by programmed stimulation from the right ventricle (RV) (Figure 2) causing hemodynamic instability and was rapidly reverted by electrical shock. Substrate mapping and propagation mapping could be performed using a very few tachycardia beats, allowing the identification of the site of arrhythmia origin. A scar was identified in the anterolateral region of the RV. The area of slow tachycardia conduction was de-

tected along one of the edges of the scar (Figure 3). Radiofrequency energy was delivered to that area using a 4-mm ablation catheter. Then, the VT could not be induced after programmed stimulation and isoproterenol infusion. Over the next 7 months of follow-up, VT was not detected by ICD interrogation. The patient is currently treated with beta blockers and amiodarone 100 mg/day.

Patients with an ICD device are exposed to multiple electrical shocks delivered by the device with adverse effects on health outcomes. Each shock, appropriate or not, increases mortality. (5) In many occasions high dose of antiarrhythmic drugs are required and may generate significant adverse effects. (3)

Radiofrequency catheter ablation may produce significant improvement in the quality of life of these patients. The procedure requires the induction of the arrhythmia in the electrophysiology laboratory. The patient has to tolerate the arrhythmia to allow collection of the necessary electrograms to determine the possible origin of the tachycardia. In several occasions, the arrhythmia produces hemodynamic instability in elder patients or in those with ventricular dysfunction, turning impossible mapping with the usual methods.

The multielectrode Array catheter consists of 64 electrodes deployed on an inflatable mesh and is suspended in the selected heart chamber to treat the arrhythmia. The device generates >3000 virtual electrograms in a single cardiac cycle. The map is updated 1200 times per second. Due to these properties, the system can collect the sufficient information to generate voltage and propagation maps within a single cardiac cycle. In this way, the site of origin of non-sustained arrhythmias or of those with hemodynamic impact can be determined instantly. (6)

We have reported the case of a fully pharmacologically treated patient with ICD, with symptoms due to ventricular arrhythmia, with some episodes of non-sustained ventricular tachycardia and other tachyarrhythmic episodes with hemodynamic instability. In this patient, the multielectrode catheter was a fundamental tool for rapid identification of the site of origin

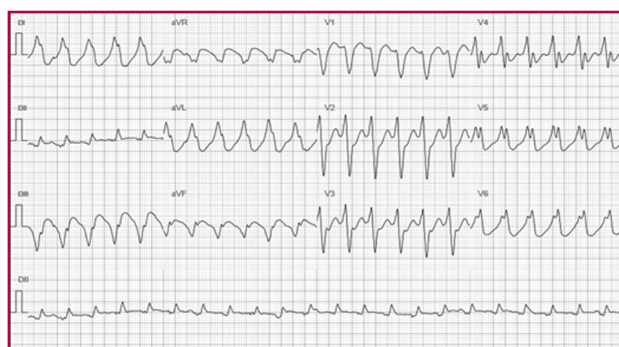


Fig. 1. 12-lead electrocardiogram showing regular tachycardia of 140 beats per minute with wide QRS complexes.

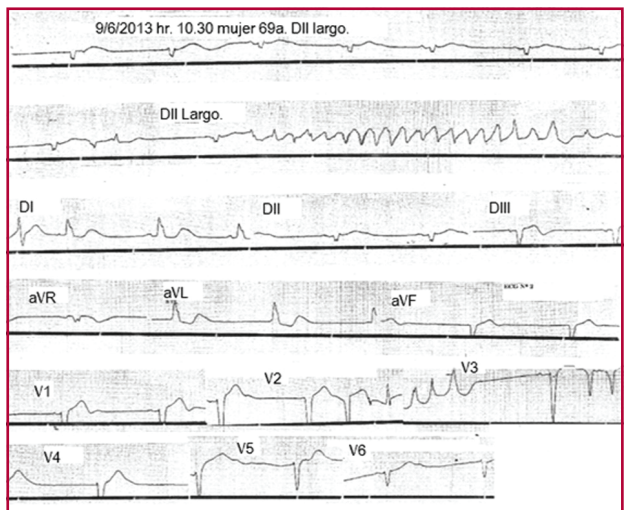


Fig. 2. Ventricular tachycardia induced in the electrophysiology laboratory with asynchronous right ventricular stimulation.

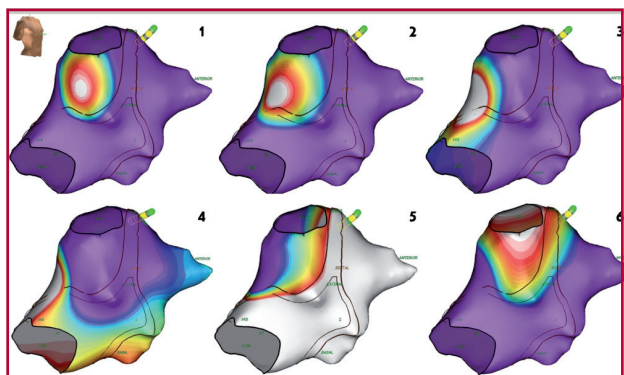


Fig. 3. Isopotential mapping showing the wavefront rotation area, as indicated by the white color. Slow conduction zone in the anterolateral area of the right ventricle (frames 1, 2 and 3).

of the arrhythmia within a couple of beats, reducing the risk of hemodynamic collapse in the electrophysiology laboratory.

**Germán Fernández¹, Gustavo F. Maid^{MTSAC, 1},
Matías Kamlofsky², Rodrigo Banega²,
Sebastián Maldonado¹, César A. Belziti^{1, MTSAC}**

¹ Department of Cardiology,
Hospital Italiano de Buenos Aires
² Saint Jude Medical

Dr. Germán Fernández, Servicio de Cardiología del
Hospital Italiano de Buenos Aires - (C1181ACH) Gascón 450
e-mail: german.fernandez@hospitalitaliano.org.ar

REFERENCES

1. El-Sherif N, Mehra R, Gough WB, Zeiler RH. Reentrant ventricular arrhythmias in the late myocardial infarction period. Interruption of reentrant circuits by cryothermal techniques. *Circulation* 1983;68:644-56. <http://doi.org/bh5p3q>
2. Área de Consensos y Normas de la SAC. Consenso de Prevención primaria y secundaria de Muerte Súbita Sociedad Argentina de Cardiología - Sociedad Uruguaya de Cardiología (con la colaboración del CONAREC). *Rev Argent Cardiol* 2012;80:165-84.

3. Preliminary report: effect of encainide and flecainide on mortality in a randomized trial of arrhythmia suppression after myocardial infarction. The Cardiac Arrhythmia Suppression Trial (CAST) Investigators. *N Engl J Med* 1989;321:406-12. <http://doi.org/czpkfc>
4. Azocar D, Dubner SJ, Labadet CD, Hadid C, Valsecchi MC, Domínguez AE y cols. Ablación por radiofrecuencia de arritmia ventricular frecuente guiada por catéter multielectrodo Array. *Rev Argent Cardiol* 2014;82:416-20. <http://doi.org/42r>
5. Moss AJ, Greenberg H, Case RB, Zareba W, Hall WJ, Brown MW, et al; Multicenter Automatic Defibrillator Implantation Trial-II (MADIT-II) Research Group. Long-term clinical course of patients after termination of ventricular tachyarrhythmia by an implanted defibrillator. *Circulation* 2004;110:3760-5. <http://doi.org/cpvfv4>
6. Miyamoto K, Tsuchiya T, Yasuoka C, Tanioka Y. A case of radiofrequency catheter ablation of ventricular tachycardia associated with an old myocardial infarction guided by a noncontact mapping system. *J Arrhythmia* 2009;25:36-41. <http://doi.org/42s>

Rev Argent Cardiol 2015;83:355-357. <http://dx.doi.org/10.7775/rac.v83.i4.5644>

Cardiac tamponade in disseminated cryptococcosis

Cryptococcosis is an opportunistic fungal disease caused by an encapsulated yeast, *Cryptococcus neoformans* (CN). The perfect state of the basidiomycetes is *Filobasidiella neoformans*, which has two varieties: *neoformans* and *bacillispora*. Five serotypes and two different varieties have been identified: CN var. *neoformans* (A, B and AD) and CN var. *gattii* (B and C). (1)

Cryptococcosis is an important cause of infection in patients with human immunodeficiency virus; it has no sex predilection though it is more common in men between 30 and 60 years, and, to a less extent, in children.

Exposure to pigeon feces or air-conditioning systems contaminated with bird droppings is a risk factor. Several infectious agents produce infective pericardial effusion; CN is one of them, with mortality between 15% and 30%. (2, 3)

We present a case report of cardiac tamponade in disseminated cryptococcosis (DC).

A 46-year-old male patient was admitted to the intensive care unit due to rapidly progressive dyspnea and consciousness deterioration. He had a history of dilated cardiomyopathy due to acquired immunodeficiency syndrome (AIDS) under antiretroviral therapy. He had had a previous hospitalization a short time ago with DC diagnosis, meningeal and lung involvement, severe hypoacusia and kidney dysfunction. At admission, the patient was confused and did not present fever (36.2 °C); his blood pressure was 70/40 mm Hg, he had jugular engorgement, poor distal perfusion and tachypnea (25 breaths per minute). Crackles were heard over both lung bases and a grade 1/6 systolic murmur was heard over the tricuspid area.

The electrocardiogram indicated sinus rhythm with a heart rate of 110 beats per minute and low QRS voltage in the frontal and precordial leads. The chest X-ray showed cardiac enlargement and diffuse redistribution of blood flow in both pulmonary fields. In

the laboratory tests, erythrocyte sedimentation rate was elevated (58 mm), the hematocrit was 30%, BUN 120 mg/dl, creatinine levels 2.2 mg/dl, and creatinine clearance 38.57 ml/min.

Doppler echocardiography showed mild left ventricular dilatation, normal wall thickness, global hypokinesia and severe left ventricular dysfunction with an ejection fraction of 24%. The left atrium was moderately dilated, with an estimated area of 29 cm². The dimensions of the right chambers were normal and the right ventricle had mild ventricular dysfunction. Opening of the trileaflet aortic valve was normal. The mitral valve had mild regurgitation and restrictive left ventricular filling pattern. The presence of mild tricuspid regurgitation allowed the estimation of systolic pulmonary artery pressure of 50 mm Hg. A severe circumferential pericardial effusion was observed and the pericardial layers were separated by 19 mm (posterior effusion), 17 mm (lateral effusion) and 6 mm (anterior effusion). Echocardiographic signs of cardiac tamponade were present, with early diastolic collapse of the right ventricular anterior wall and diastolic collapse of the right atrium, dilated inferior vena cava of 32 mm with inspiratory collapse <50% (Figures 1 and 2).

The patient required endotracheal intubation, mechanical ventilation and hemodynamic support with vasoactive drugs. He underwent emergency pericardiocentesis, and after 400 ml of blood stained fluid were drained, the hemodynamic parameters experienced immediate recovery.

Further examination of pericardial fluid was positive for CN antigen, and quantitative analysis was performed by latex test.

Microscopic examination with India ink stain and pericardial fluid culture were positive for CN.

The infectologists indicated fluconazole 200 mg for life because of the unfavorable outcome and disseminated form; the patient is currently taking this medication.

The incidence of cryptococcosis in AIDS patients varies among the different regions of the world, from 50-10% in Western Europe and in the United States, to 20% or more in Central Africa and Southeast Asia. In Argentina, the incidence would be 4.6% according to official public health agencies. (4) Infection is acquired by inhalation of air-borne yeast cells present in nature that easily reach the pulmonary alveoli. Neither person-to-person nor animal-to-human respiratory transmission has not been documented, but transmission via organ transplantation has been reported. Physicians should suspect this disease to make the diagnosis. (1)

Pericardial involvement occurs as pericarditis, asymptomatic pericardial effusion or cardiac tamponade. The prevalence of pericardial involvement ranges between 3% and 37%. (5)

The typical signs and symptoms of heart failure (HF) may be difficult to recognize in a population of

patients in whom the systemic symptoms of HF overlap with those of cryptococcosis and in whom the incidence of pulmonary disease is higher than that of heart disease. The clinical manifestations of HF appear during the late stages of the disease. Asthenia and discomfort as symptoms of low cardiac output may be easily attributed to AIDS. Jugular engorgement and edemas are usually absent. Only a minority of patients with asymptomatic ventricular dysfunction have sinus tachycardia at rest as single manifestation. (6) In cardiac tamponade, the clinical signs of hemodynamic impairment may be absent in patients with cachexia and low right ventricular filling pressures. (3)

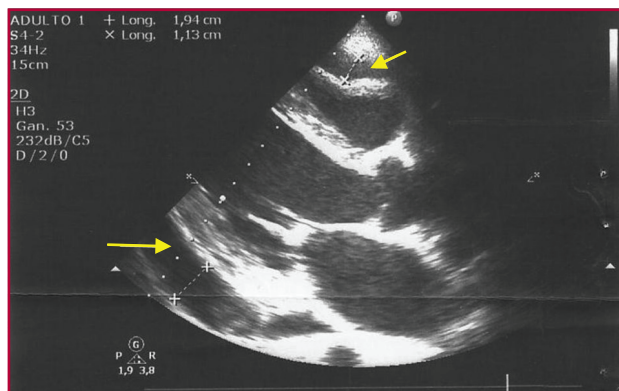


Fig. 1. Transthoracic echocardiography. Parasternal long-axis view. A severe circumferential pericardial effusion is observed, 16 mm posteriorly and 6 mm anteriorly, with early diastolic collapse of the right ventricular anterior wall

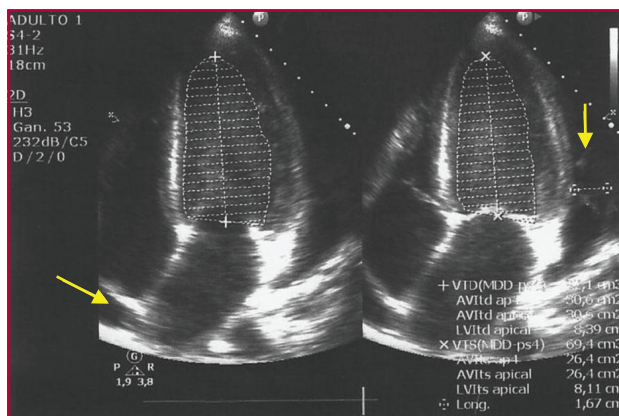


Fig. 2. Transthoracic echocardiography. Four-chamber apical view. Pericardial effusion is observed, 17 mm laterally, with diastolic collapse of the right atrium.

The diagnosis of cryptococcosis is based on direct observation of the etiological agent with India ink staining. Cultures should be prepared in Sabouraud medium or in other media not containing cycloheximide, and have optimal growth between 32 °C and 37 °C. Growth is inhibited at 40 °C. The histopathological findings are described as jelly-like areas with abundant cryptococci and minimal inflammation or granulomatous infiltrates, with minimal cryptococci and marked inflammatory reaction with lymphocytes, monocytes and giant cells. The presence of antigens or antibodies in serum or cerebrospinal fluid is positive in 77% to 99% of cases. A positive test indicates disseminated disease and high titers correlate with the severity of the disease and with the response to treatment.

Treatment depends on two factors: the anatomic site involved and host immune status. Azole derivatives are prescribed for 2 to 6 months in immunocompetent patients, but in patients with AIDS treatment is for life. (2)

Disseminated cryptococcosis is an uncommon disease and should be highly suspected to reach a diagnosis, as its association with AIDS increases mortality, particularly when associated with pulmonary artery hypertension and cardiac tamponade.

Ulises Godoy¹, Leandro Rodríguez Pardal¹, Juan Medrano¹, Miguel Curone²

¹ Department of Cardiology and ² Intensive Care Unit
Clínica y Maternidad Suizo Argentina. Buenos Aires, Argentina.
Av. Pueyrredón 1461 - (1118) Buenos Aires, Argentina
Phone number: 011 5239-6071 - e-mail: ulisesgodoy31@gmail.com

REFERENCES

1. De Kok E, Cirocco A, Ruiz A. Criptococosis diseminada: a propósito de un caso. *Dermatología Venezolana* 2004;42:22-4.
2. Arenas R. *Criptococosis. Micología médica ilustrada*. 3.a ed. México: McGraw-Hill Interamericana; 2008. p. 239-46.
3. Schuster M, Valentine F, Holtzman R. Cryptococcal pericarditis in an intravenous drug abuser. *J Infect Dis* 1985;152:842. <http://doi.org/bk79zc>
4. Negróni R. Las micosis en el SIDA. *Rev Arg Micol* 1990;13:3-14.
5. Welch K, Finkbeiner W, Alpers CE, Blumenfeld W, Davis RL, Smuckler EA, et al. Autopsy findings in the acquired immune deficiency syndrome. *JAMA* 1984;252:1152-9. <http://doi.org/ch6pgb>
6. Herskowitz A, Baughman K. Efecto de la infección por el HIV sobre el corazón. En: Braunwald E, editor. *Heart disease update*. Baltimore: WB Saunders Company 1996;1-11.