

## Superior Vena Cava Syndrome and Infectious Endocarditis Associated with Dual Chamber ICD Implantation

*Síndrome de vena cava superior y endocarditis infecciosa asociado al implante de DAI bicameral*

JAVIER URMENETA ULLOA, ISABEL MOLINA BORAO, MARUAN CHABBAR BOUDET

These images correspond to a 68-year-old male patient with a history of posteroinferior myocardial infarction, and out-of-hospital cardiopulmonary arrest due to an episode of ventricular fibrillation in November 2012, resuscitated without sequelae. The electrocardiogram showed inferoposterior hypokinesia with preserved LVEF. Coronary angiography ruled out significant lesions. After completing the study, a dual-chamber automatic cardioverter defibrillator (AICD) was indicated.

Six months after implantation, the patient presented with progressive symptoms of facial and cranial congestion, headache, and redness primarily associated with decubitus. CT scan and phlebography confirmed the diagnosis of superior vena cava syndrome (SVCS) due to significant stenosis. Initially, the approach was anticoagulant therapy and follow-up of the clinical course. During that period, the patient had self-limited fever bouts together with diaphoresis and chills, and was admitted with suspected endocarditis. The echocardiography showed an image consistent with vegetation on the ventricular lead. Blood cultures were positive for *Staphylococcus epidermidis*. Complete removal of the device was necessary due to poor clinical course—despite anticoagulant therapy (developing facial and upper thoracic edema)—and a diagnosis of endocarditis on the defibrillator lead. However, symptoms consistent with SVCS persisted and a second phlebography confirmed persistent severe stenosis at that level (Figure 1). In that scenario, percutaneous stent implantation in the SVC was performed without complications (Figure 2), followed by new AICD implantation in the contralateral thoracic region via the right subclavian artery, inserting a single lead through the implanted stent. Clinical course was favorable, and the patient is currently asymptomatic.

The incidence of SVCS in patients with cardiac electronic devices is very low (0.03-0.4%). (1) Predisposing factors include hypercoagulability, use of hormone therapy, multiple leads, systemic infection, and use of polyurethane wires. (2) Patients are usually asymptomatic because slow progression of the disease allows time for collateral circulation to develop. However, its absence may result in florid and invalidating symptoms, as was the case of our patient. Treatment is controversial, and many authors claim that the use of anticoagulation is the first therapeutic option. If the course is unfavorable, other treatment options should be considered, such as balloon angioplasty and stent implantation. (2, 3)

The association of several risk factors facilitates the development of SVCS. Our patient had two of the main factors associated with this syndrome: the endovascular implantation of two leads and the underlying infection in one of them.

Given the clinical and prognostic implications of both entities, we should always bear in mind this potential association in order to obtain a quick and accurate diagnosis, and apply an appropriate therapeutic strategy.

### Conflicts of interest

None declared

(See authors' conflict of interest forms in the web/ Supplementary Material).

Rev Argent Cardiol 2015;83:551. <http://dx.doi.org/10.7775.rac.v83.i6.6968>

Address for reprints: Dr. Javier Urmeneta Ulloa - Calle Félix Latassa, 28, 6to C - 50006, Zaragoza, España - e-mail: javierurmeneta@hotmail.com

Department of Cardiology, Hospital Universitario Miguel Servet, Zaragoza Zaragoza, Spain

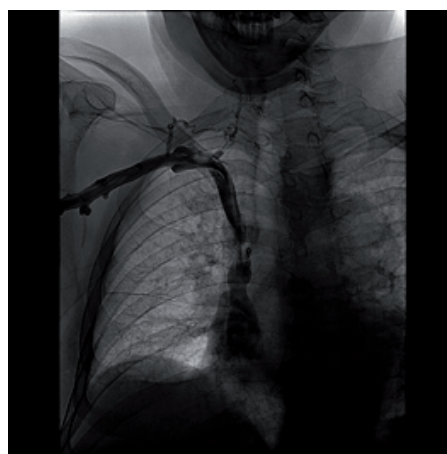


Fig. 1. Phlebography following device removal, confirming the persistent stenosis at the superior vena cava.

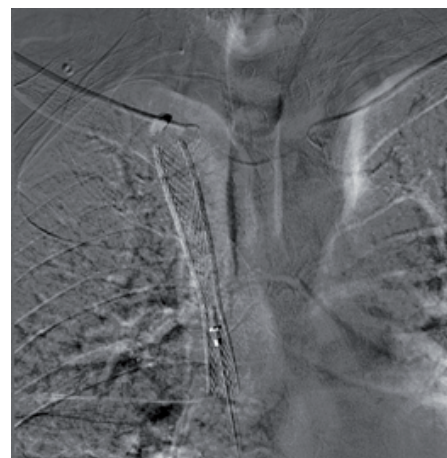

Fig. 2. Stent implantation in the superior vena cava.

### REFERENCES

1. Singh M, Talab SK. A case of pacing lead induced clinical superior vena cava syndrome: a case report. *Cases J* 2009;2:7477. <http://doi.org/b635w8>
2. Klop B, Scheffer MG, McFadden E, Bracke F, van Gelder B, et al. Treatment of pacemaker-induced superior vena cava syndrome by balloon angioplasty and stenting treatment of pacemaker. *Neth Heart J* 2011;19:41-6. <http://doi.org/cnwqh4>
3. Park HW, Kim W, Cho JG, Kang JC. Multiple pacing lead-induced superior vena cava syndrome: successful treatment by balloon angioplasty. *J Cardiovasc Electrophysiol* 2005;16:221-3. <http://doi.org/bcx4k9>