

## artículo original

# Clinical and radiographic evaluation the effect of ozone therapy on tissue surrounding implant retained mandibular overdentures

Iman M.S.Matar

Department of Prosthodontics, Faculty of Dentistry, Pharos University, Alexandria, Egypt

Ahlam M. El-Sharkawy

Department of Prosthodontics, Faculty of Dentistry, Alexandria University, Egypt

Nevein Sh.Mohamed

Department of Oral Surgery, Faculty of Dentistry, Alexandria University, Egypt

Mohamad N. Mawsouf

Ozone Therapy Unit. National Cancer Institute, Cairo University Egypt

### Keywords

ozone  
implants  
mandibular implant  
overdenture

### Abstract

**Objective:** to evaluate the effect of ozone on the tissue surrounding implant retained mandibular overdenture both clinically and radiographically **Material and Methods:** Sixteen systematically healthy completely edentulous male patients ranged from 40-60 years were participating in this study to receive mandibular implant overdenture retained by two implants in the canine area.

Eight patients for every group, group I: (control group) patients received two implants which following the conventional methods and group II: (test group) patients received two implants which following the conventional methods nevertheless; irrigation with ozonized water of 25µg/mL concentration was applied during the osteotomy procedure instead of saline. Ozone gas of 60 µg/mL concentration was applied topically in the performed osteotomy sites before the insertion of the implants. Clinical and radiographic evaluations were carried out for every patient at the time of loading with the prosthesis, then three, six and up to 12 months respectively. **Results & conclusion:** Ozone therapy accelerates and enhances the osseointegration of titanium implants; increases bone density in peri-implant interface and reduce the anticipated marginal bone loss.

### Suggestion on how to quote this paper:

M.S.Matar, Iman. (2016). Clinical and radiographic evaluation the effect of ozone therapy on tissue surrounding implant retained mandibular overdentures. *Revista Española de Ozonoterapia*. Vol. 6, nº 1, pp 51-62

## **Introduction:**

Oral implants have revolutionized the practice of dentistry. The use of dental implants in the treatment of fully edentulous patients has become an important addition in oral/dental rehabilitation.<sup>(1)</sup> With the advent of dental implants, the benefits and advantages of using an overdenture have become reality and miracle for edentulous patients.<sup>(2)</sup> Implants retained overdentures in the mandible provide predictable results with improved stability, retention, function and patient satisfaction compared with conventional dentures.<sup>(3, 4)</sup> Consequently, treatment with mandibular implant retained overdenture can solve long-term problems in edentulous patients.<sup>(5, 6)</sup>

The success of implants has been attributed to osseointegration or direct contact of the implant surface and bone without a fibrous connective tissue interface.<sup>(7,8)</sup> The high level of predictability and success of current implant therapies have been the result of the evolution of many techniques that promote osseointegration.<sup>(9)</sup> Post-operative stimulation with electromagnetic fields<sup>(10)</sup>, and low power laser has been found to encourage positive osteogenicity.<sup>(11)</sup> The use of Solcoseryl in combination with electric field stimulation promoted the formation of new bone.<sup>(12)</sup> Moreover, local administration of growth factor at the time of implant placement could enhance peri-implant bone reaction.<sup>(13)</sup>

Ozone therapy was first utilized in Germany in 1950`s, as a modern development application for treatment of wounds and other infections. Nowadays, there is growing evidence that it can be employed as a useful therapeutic agent in both dental and medical fields.<sup>(14)</sup> Ozone reacts as an antioxidant, able to promote homeostasis, enhance local oxygen supply and elicit bactericidal effect particularly on staphylococcal and streptococcal infections.<sup>(15)</sup> All the information studied has showed that ozone readily penetrates through the tissue, eliminates any bacterial, fungal and viral contamination.<sup>(16, 17)</sup>

In dentistry, medical ozone therapy can be added to the treatment protocols of many patients with maxillofacial problems.<sup>(18)</sup> The application of ozone in oral surgery has an attempt to disinfect the oral cavity prior to surgery.<sup>(19)</sup> Creating a sterile surgical environment in the oral cavity would be a desirable prerequisite for implant surgery. To get some way towards this goal, a sterile implant surface is achieved directly by applying ozone prior to and immediately after surgery. This would also promote healing and stimulate the immune system.<sup>(14)</sup>

Accordingly, with all the reported benefits of ozone, the use of ozone in implant surgery seems to be promising. However, the clinical application of ozone during this surgery and its exact mechanisms which affects the process of osseointegration, subjects for further study.

## **Material and Methods:**

### **Patient selection:**

Sixteen completely edentulous male patients were selected for this study from the outpatient clinic, Faculty of Dentistry, Alexandria University and Alexandria Dental Research Center to receive mandibular implant overdenture retained by two implants in the canine area. The age of the patients ranged from 40-60 years. All patients were free from any systemic diseases. They had enough bone height and width in the area in which the implants to be placed, and sufficient inter arch space.

### **Preoperative preparation\_**

Medical and dental history, intraoral examination, panoramic radiograph and study casts were made panoramic radiograph and study casts were made. A clear radiographic template was fabricated for each patient to determine the exact locations of the implants. It was constructed using plastic vacuum forming machine with embedded metallic marking balls at the desired implant locations (canine regions). The patient wore the radiographic template and a panoramic radiograph was taken which was used to confirm that the locations of the metal markers did not interfere with the important mandibular structures and also was used to calculate bone height available for the implants and the relation of the balls to the mental foramina. Bucco-lingual width of the available bone was determined by using ridge mapping procedure. Each patient received new maxillary and mandibular complete dentures constructed according to the conventional method.

### **Surgical phase**

It was planned for every patient to receive two endosseous root form implants (ENDURE IMTEC) \*in the mandibular canine area according to the two-stage surgical protocol.

#### **First surgical phase (osteotomy procedure):**

The patients were divided into two groups, eight patients for each as the following:

##### **Group I Implants (Control group):**

The implants were inserted in the canine regions by the conventional method following the protocol recommended by implant's manufacture. Profuse irrigation with saline was applied during the osteotomy procedure.

##### **Group II Implants (Test group):**

The implants were inserted in the canine regions following the conventional methods nevertheless; irrigation with ozonized water <sup>(19)</sup> of 25µg/ml concentration<sup>(20)</sup> was applied during the osteotomy procedure instead of saline. Figure (1) .Ozonized water was prepared by using the Longevity Ext 120 medical ozone generator\*.

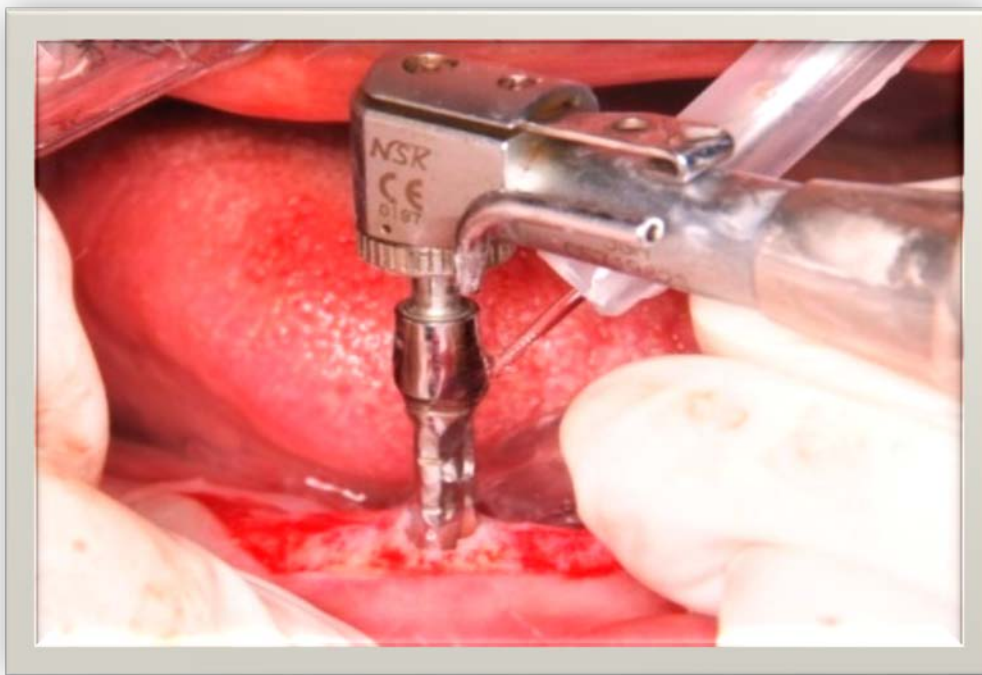


Figure (1): Drilling the osteotomy using ozonized water irrigation

\* IMTEC Co., Ardmore, Oklahoma, USA

\* Longevity Ext 120, Longevity Co.Canada

Ozone gas of 60 µg/ml concentration was applied topically in the performed osteotomy sites before the insertion of the implants. <sup>(21, 22, 23)</sup> It was done by filling several 50ml syringes with medical ozone gas, the needles were bended and directed inside the implant bed. The gas was delivered slowly for one minute <sup>(14)</sup>, under high suction to prevent its inhalation that may cause irritation of the pulmonary epithelium. <sup>(24)</sup> **Figure (2,3)**

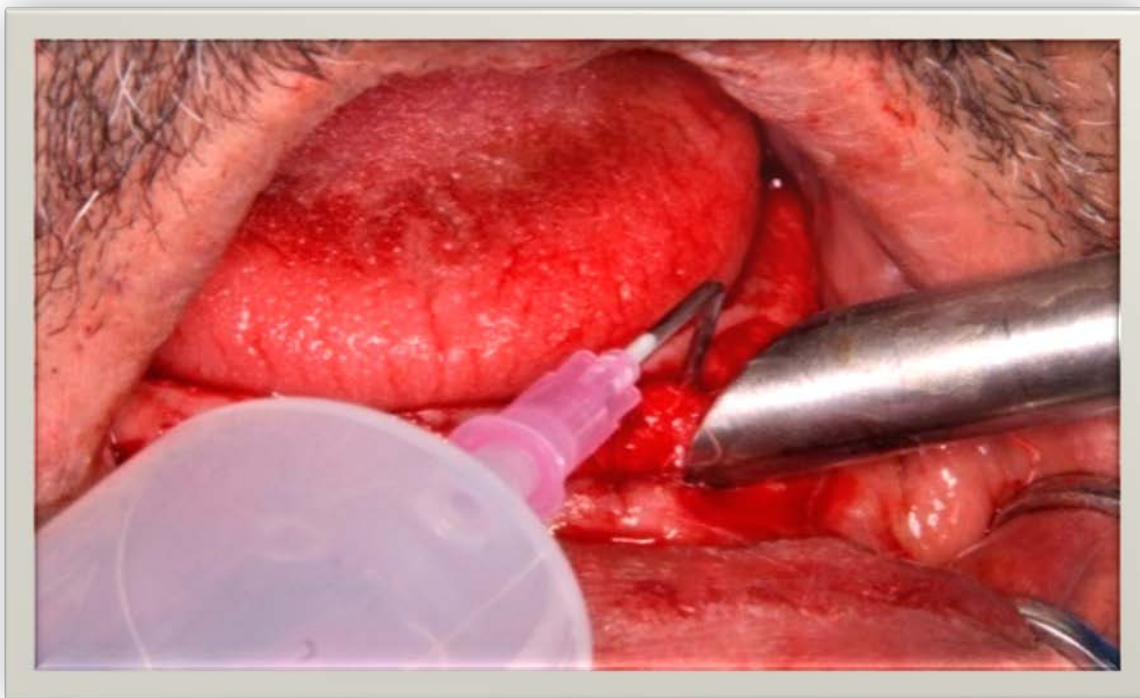


Figure (2): The osteotomy site exposed to medical ozone gas under high suction

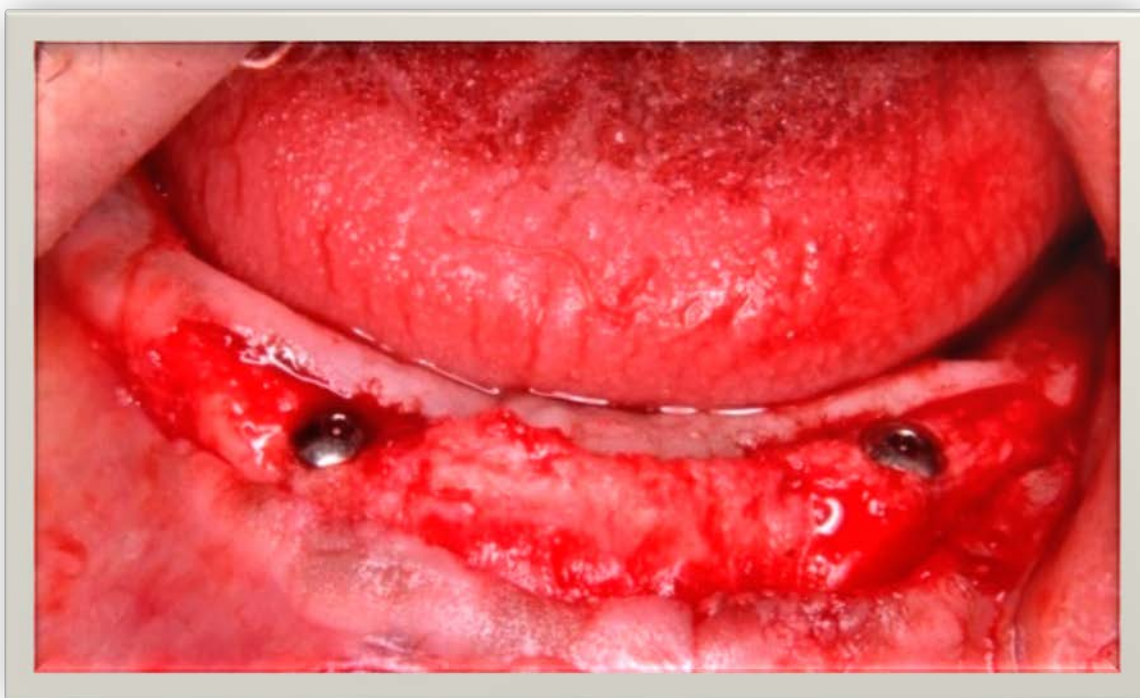


Figure (3): Insertion of two fixtures in first surgical phase surgery

The mucoperiosteal flap was repositioned and sutured over the implants and interrupted sutures to the rest of the flap using number 3-0 silk sutures. Post-operative drugs including antibiotics, anti-inflammatory and mouthwash were prescribed for all patients. The implants were unloaded for about three months after implant surgery.

**Second surgical phase (implants exposure):**

After the healing period of three months, the implants were uncovered using punch technique and healing abutments were connected.

**Prosthetic phase**

One week later, when the soft tissues attain sufficient seal around the implants, the healing abutments were removed and ball abutments were fixed to the implants **Figure(4)**. The metal housings with the rubber O-rings\*\*\* were attached to the fitting surface of the lower dentures using direct pick-up technique with an autopolymerized acrylic resin. **Figure (5)**

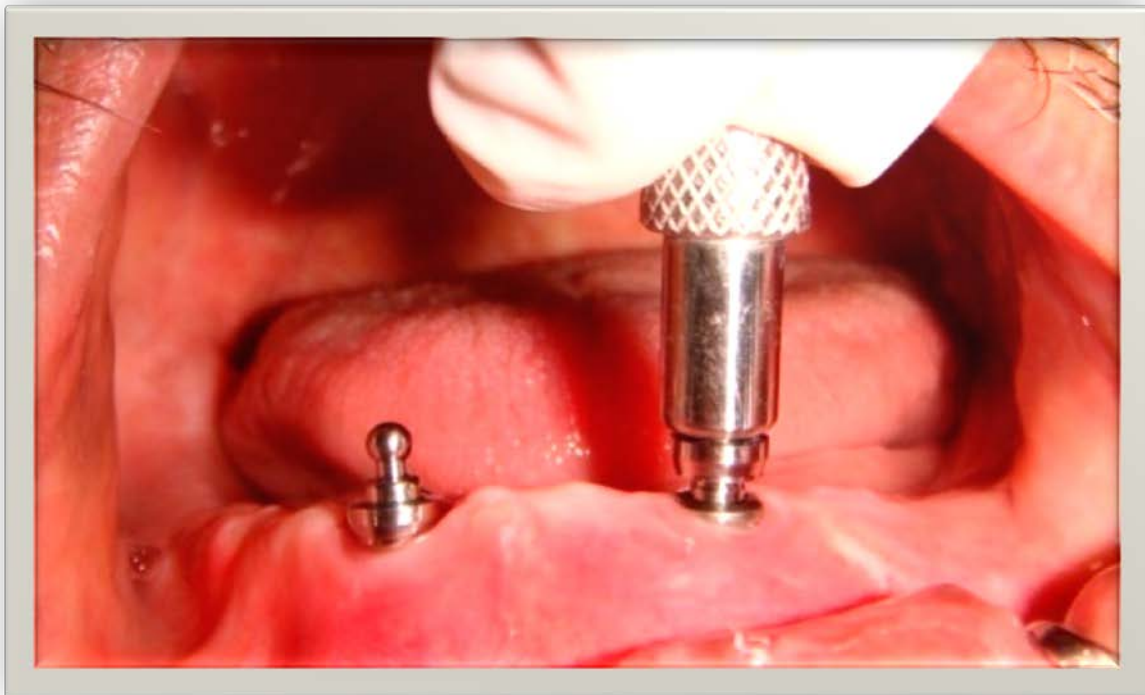


Figure (4): Ball abutments were screwed to their implant fixtures

---

\*\*\* O-Ring System IMTEC Co., Ardmore, Oklahoma, USA

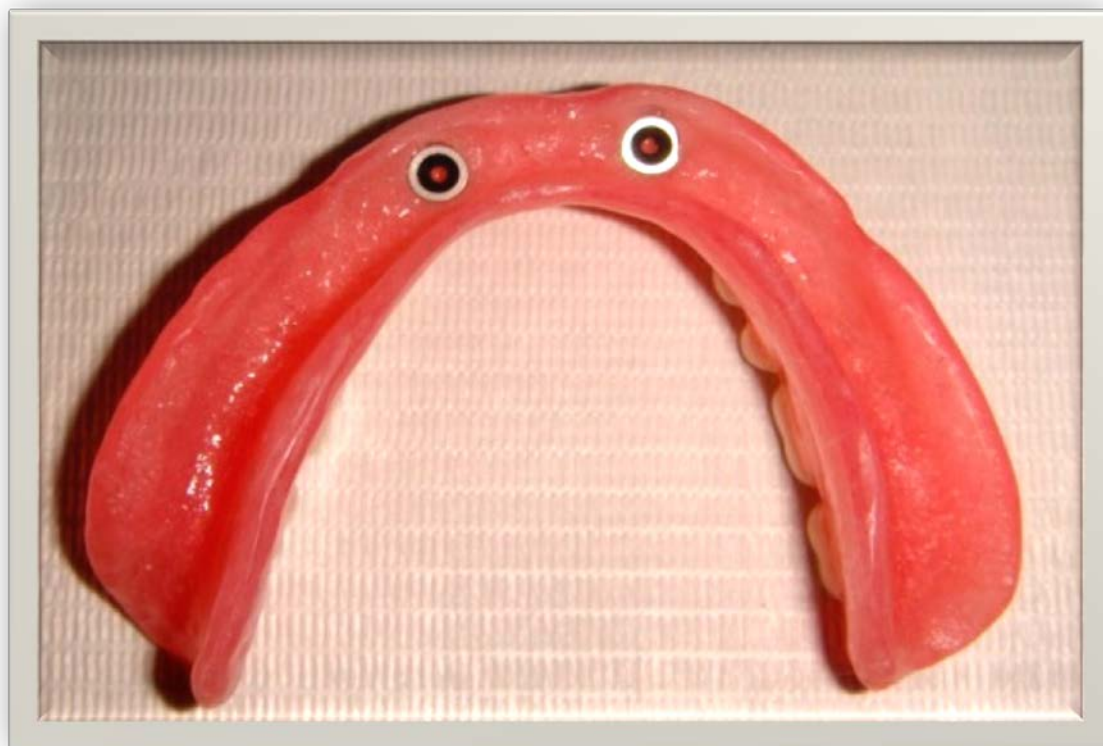

Figure (5): Metal housing and O-rings attached secured to the fitting surface of the denture

A clinical remount procedures and occlusal equilibration was completed to correct occlusal discrepancies and the denture was delivered to the patient. The patients were instructed how to take care of their implants and the denture to maintain high level of oral hygiene. Follow-up was performed every week for the first month after denture use. Then the patient was recalled for the evaluation of the implants both clinically and radiographically at the time of loading with the prosthesis, then three, six and up to 12 months respectively.

**Clinically assessment was performed using plaque index (PI), gingival index (GI) peri-implant probing depth (PPD) and implant mobility.**

**Radiographic assessment was performed to detect the marginal peri-implant bone level changes and the peri-implant bone density using direct standardized digital radiographs (RdioVisioGraphy) (RVG). The digital images were analyzed through all the follow up period with Image J program. Figure (6, 7)**

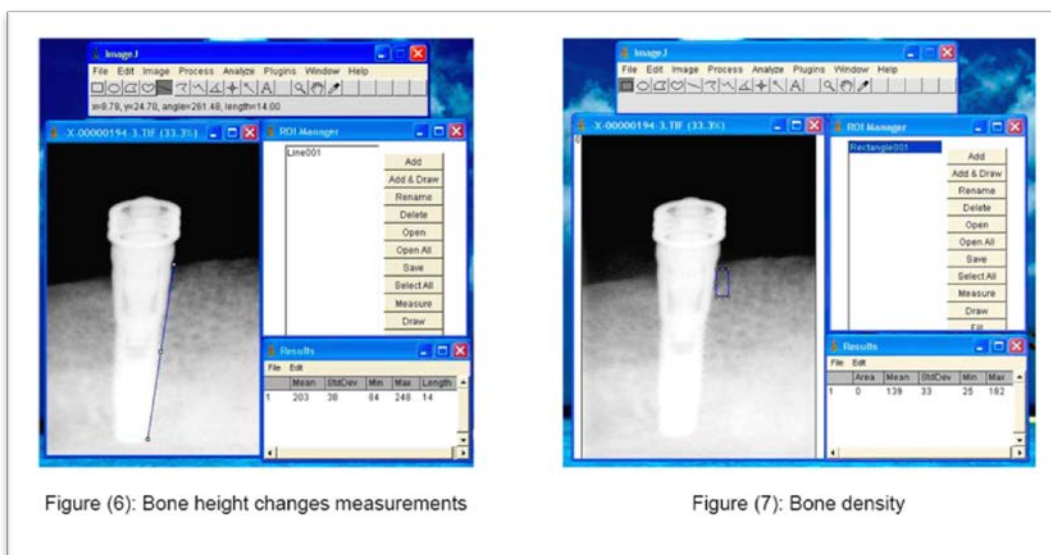


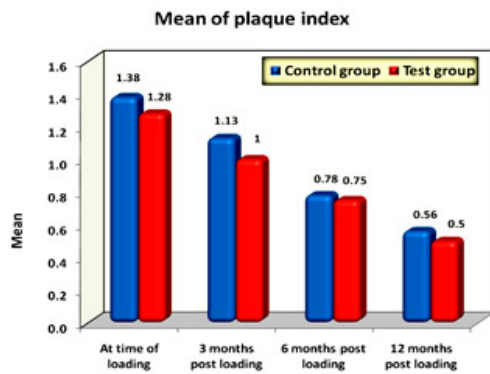
Figure (6): Bone height changes measurements

Figure (7): Bone density

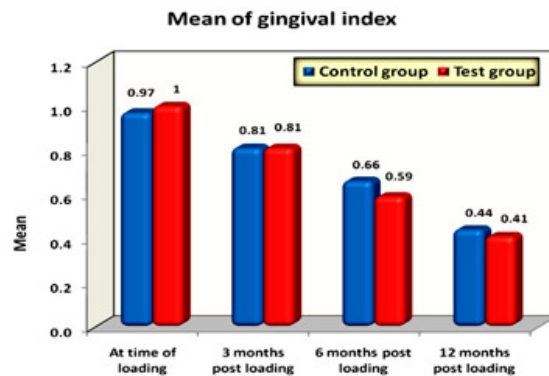
## Results:

**Clinical results:** as regard the peri-implant parameters showed: graph (1, 2, 3)

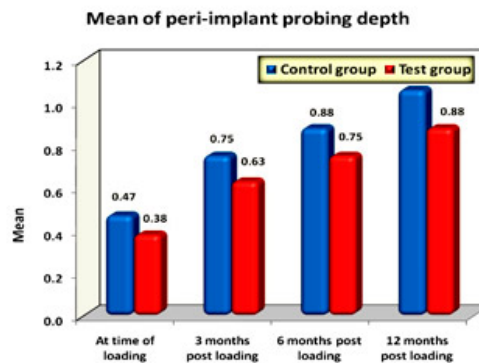
1. Significant decrease in plaque index (PI) and gingival index (GI) in both groups
2. Significant increase in peri-implant probing depth (PPD) in both groups
3. No significant difference was existed between the two groups as regards plaque index (PI), gingival index (GI) and peri-implant probing depth (PPD).
4. There was absence of implant mobility during the follow up period in both groups



Graph (1)



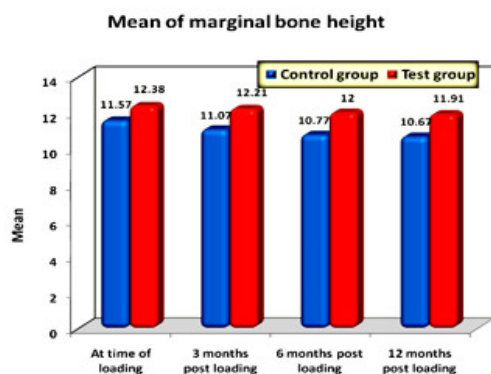
Graph (2)



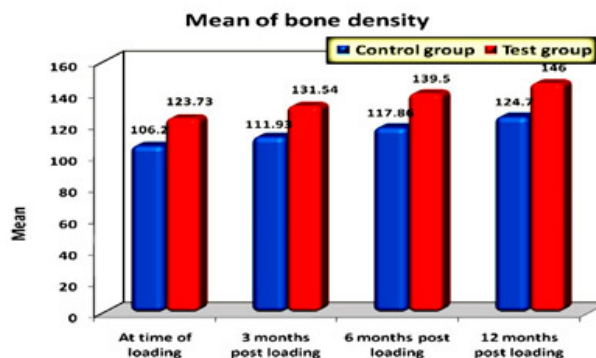
Graph (3)

## Radiographic results: graph (4, 5)

The radiographic results revealed that the marginal peri-implant bone loss in the two groups was within the conventional limits generally accepted for osseointegrated dental implants. Whereas, test group (ozonized group) showed better results in comparison to control group. In addition, there was a significant increase in the mean peri-implant bone density in both groups throughout the evaluation period. However, the mean scores of the measurements of the peri-implant bone density were higher in test group (ozonized group) in comparison to control group.



Graph (4)



Graph (5)

## Discussion:

Osseointegrated implant-supported overdentures have been used in the rehabilitation of the edentulous lower jaw with excellent results.<sup>(25)</sup> It naturally follows that research workers would direct their thinking toward methods of accelerating the biologic processes of formation and maturation of the tissues related to the implants, reducing the healing time and thus accelerating implant loading which is the actual promising approach for both patients and clinicians.<sup>(10)</sup>

Medical ozone is a mixture of ozone gas and pure oxygen prepared from pure oxygen.<sup>(26)</sup> Ozone therapy possesses many biological and physical characters. It has a powerful oxidant action. It can oxidize most bacteria, fungus and viruses leading to their destruction which can become an important and reliable adjuvant therapy for several diseases.<sup>(27)</sup> Ozone therapy has been used for debridement and cleaning of the wound and also, to promote epithelialization and healing.<sup>(19)</sup>

So this maneuver aimed to detect the effect of topical ozone therapy (gas and ozonized water) on osseointegration of endosseous implants clinically and, radiographically.

**The results** of the present study as regard the peri-implant parameters showed no significant difference between the two groups at the end of the study. In addition, no clinical **mobility** observed in any of the implants of both groups during the whole period of evaluation. This indicated that osseointegration was achieved and maintained during the evaluation period. This was confirmed by radiographs which show no peri-implant radiolucency around any of the evaluated implants.<sup>(28, 29)</sup>



Regarding the **marginal bone level changes**, the amount of mean marginal bone loss recorded in both groups in this study was within the accepted limits occurring with osseointegration which did not exceed 1mm, hence all the implants were considered successful<sup>(30, 31)</sup> It may be attributed to proper patient and implant selection, proper surgical protocol and adequate loading of the implant prosthesis in proper time and with suggested manner.

The results also showed significant difference between the test group (ozonized) and control group (non-ozonized) at the different times of observation (at the time of loading, three, six and twelve months). The mean of marginal bone loss in the test group (ozonized group) was registered less than that in control group (non-ozonized group) 0.47mm and 0.90 mm respectively at the end of the evaluation period. These results might be attributed to the influence of ozone therapy on peri-implant bone which promotes bone formation, maturation and remodeling. These were performed by activation of osteoblasts and osteosynthesis and decrease in osteoclastic activity.<sup>(32)</sup> Under the influence of ozone therapy, ozone leads to a higher expression of cytokines especially Transforming Growth Factor TGF- $\beta$ 1<sup>(33)</sup> which has the ability for regulation and coordination in the initial wound healing phase. TGF- $\beta$ 1 also, has a marked influence on cell proliferation (monocytes and fibroblasts), angiogenesis, synthesis of collagen and extracellular matrix.<sup>(34)</sup>

Moreover, ozone is relatively increase vascularity due to the increased expression of Vascular Endothelial Growth Factor (VEGF) by ozonation.<sup>(35)</sup> VEGF is considered the main growth factor of vascularization in the late phase of wound healing.<sup>(36)</sup> Therefore, increase vascularity by ozone enhanced the proliferation and differentiation of the osteoblasts responsible for peri-implant bone formation. Finally, Ozone promotes healing by its bactericidal effects<sup>(37)</sup> which are based on its controlled oxidative stress, with its direct destruction of almost all microorganisms.<sup>(38,39)</sup> Moreover, the presence of antioxidant enzymes in normal healthy cells not only protected from controlled oxidative mechanism of ozone therapy but also produce upregulation of antioxidant enzyme.<sup>(40)</sup> Besides, ozone oxidizes the toxic waste products of those microorganisms, rendering them nontoxic and can be easily excreted by liver and kidney.<sup>(41)</sup>

The results of this study showed a significant increase in **bone density** for both groups during follow up intervals. This increase in peri-implant bone density could be attributed to the effect of loading of the implants by an overdenture with O-ring attachment that permitted vertical movements leading to physiological stimulation of the ossification of supporting bone around implant.<sup>(42, 43)</sup>

It is worthy to mention that there was a significant difference in bone density between group I (control group) and group II (ozonized group) at the end of the year. The mean scores of the measurements of the peri-implant bone density were higher in the group with ozone therapy compared to the group with non-ozone therapy. This may be attributed to the positive influence of ozone therapy on the bone metabolism and improvement of reparative processes in bone by ozone usage.<sup>(44)</sup>

It is assumed that, ozone therapy improved the local environment in the peri-implant interface zone by its bactericidal activity, enhancing local oxygen supply and promoting hemostasis,<sup>(37,45,46)</sup> which may leads to enhancement of the proliferation of osteoblasts, therefore increasing the rate and amount of bone formation and mineralization on the peri-implant bone interface<sup>(47)</sup>.

## Conclusion:

Results of the present study suggest that ozone therapy accelerates and enhances the osseointegration of titanium implants; increases bone density in peri-implant interface and reduce the anticipated marginal bone loss.

## References:

- 1- Weber HP, Conchran DL. The soft tissue response to osseointegrated dental implants. *Prosthet Dent.* 1998; 79:79-89.
- 2- Naert I, De Clereq M, Theuniers G, Schepers E. Overdenture supported by osseointegrated fixtures for edentulous mandible. A 2.5 year report. *Int J Oral Maxillofac Impl.* 1988; 3:191-196.
- 3- Castellon P, Block MS, Smith MB, Finger IM. Immediate loading of the edentulous mandible: delivery of the final restoration or a provisional restoration which method to use. *J Oral Maxillofacial surg.*2004; 62: 30-40.
- 4- Gjengedal H, Dahl L, Lavik A, Trovik TA, Berg E, Boe OE, Malde MK. Randomized clinical trial comparing dietary intake in patients with implant-retained overdentures and conventionally relined denture. *Int J Prosthodont.* 2012;25:340–347.
- 5- Jacobs R, Van Steenberg he D, Nys M, Naert I. Maxillary bone resorption in patients with mandibular implant-supported overdentures or fixed prostheses. *J Prosthet Dent* 1993; 70:135-140
- 6- Mericske-Stein R, Zarb GA. Overdentures: an alternative implants methodology for edentulous patients. *Int J Prosthodont.* 1993; 6:203-208
- 7- Albrektsson T, Branemark PI, Hansson HA, Lindstrom J. Osseointegrated titanium implants. Requirements for ensuring a long-lasting, direct bone to implant anchorage in man. *Acta Orthop Scand.* 1981; 52:155-170.
- 8- Zechner W, Tangl S, Futst G, Tepper G, Thams U, Mailath G. Osseous healing characteristics of three different implant types. *Clin Oral Implants Res.* 2003; 14:150-157.
- 9- Roos J, Sennerby L, Lekholm U, Jemt T, Gronadahl K, AL-brektsson T. A quantitative and qualitative method for evaluating implant success: a 5 year retrospective analysis of the Branemark implant. *In J Oral Maxillofac Implants.*1997;12:504-514.
- 10- Matsumoto H, Ochi M, Abiko Y, Hirose Y, Kaka T, Sakaguchi K. Pulsed electromagnetic fields promote bone formation around dental implants inserted into the femur of rabbits. *Clin Oral Implants Res.*2000; 11:354-360
- 11- Guzzardella GA, Torricelli P, Giardino RNN. Osseointegration of endosseous ceramic implants after postoperative low-power laser stimulation: an in vivo comparative study. *Clin Oral Implants Res.* 2003;14:226-232.
- 12- Ochi M, Wang P, Ohura K, Takashima S, Kagami H, Hirose Y, et al. Solcoseryl, a tissue respiration stimulating agent, significantly enhances the effect of capacitively coupled electric field on the promotion of bone formation around dental Implants. *Clin Oral Implants. Res.* 2003;14: 294-302
- 13- Stenport FV, Johansson CB, Sauase T, Yamasaki Y, Oida S: FGF-4 and titanium implants: a pilot study in rabbit bone. *Clin Oral Impants Res.* 2003; 14:363-368.
- 14- Lynch E: *Ozone. The Revolution in Dentistry.* Quintessence Publishing Co., Belfast UK 2004.
- 15- Burgassi S, Zanardi I, Travagli V, Montomoli E, Bocci V. How much ozone bactericidal activity is compromised by plasma components? *J Appl Microbiol.* 2009; 106:1715-1721.
- 16- Bocci VA. Scientific and medical aspects of ozone therapy. State of the art. *Arch Med Res.* 2006; 37: 425-435.

- 17- Holmes J: Clinical reversal of root caries using ozone, double-blind, omized, controlled 18-mouth trial. *Gerodontology*.2003;20:106-114
- 18- Volozhin AI, Agapov VS, Shulakov VV, Smirnov SIV, Sashkina TI. Role of phagocytosis activity in the mechanism of therapeutic effect of medical ozone in patients with sluggish purulent inflammations of maxillofacial soft tissues. *J Stomatologiia*. 2001; 80: 22-24.
- 19- Viebahn R. The use of ozone in medicine. 4th rev. Ed. Karl F.Hug Publishers, Heidelberg 2002.
- 20- Bocci V. Ozone: A New Medical Drug. Springer, Netherlands 2005 pp31-35.
- 21- Ozone therapy applications and indications of medical ozone. Ozone Seminar Congress. Medical Society of ozone application. Munich, May 23-25 2003.
- 22- Stanley. B: Medical Ozone Therapy. *Consumer Health*. 1996;19:1-2.
- 23- Rakovsky S. and Zaikov G.: Application of ozone in medicine. *Chemical Technology* 2009; 3: 237-248.
- 24- Zhuowei Li, Robbert M. Tighe, Feifei Feng, Julie G. Ledford, and John W. Hollingsworth. Genes of innate immunity and the biological response to inhaled ozone. *J Biochem Mol Toxicol*.2013; 27(1):3-16.
- 25- Christensen GJ. Treatment of the edentulous mandible. *J Am Dent Assoc*. 2001; 132:231-233.
- 26- Akey O, and Walton T. liquid-phase study of ozone inactivation of Venezuelan equine encephalomyelitis virus. *Appl Environ Microbiol* 1985; 50: 882- 886
- 27- Iorio EL. Ozone therapy and oxidative stress evaluation. First International Congress of Aepromo."New Horizons for the ozone therapy" Spain. Friday5 and Saturday 6 June, 2009.
- 28- Smith DE, Zarb GA. Criteria for success of osseointegrated endosseous implants. *J Prosthet Dent*. 1989; 62: 567-572.
- 29- Misch CE. The implant quality scale: a clinical assessment of the health-disease continuum. *Oral Health*.1998; 88:15-20.
- 30- Naert I, Quirynen M, Theuniers G, van Steenberghe D. Prosthetic aspects of osseointegrated fixtures supporting overdentures. A 4-year report. *J Prosthet Dent*. 1991; 65: 671-680.
- 31- Lindquist LW, Rockler B, Carlsson GE. Bone resorption around fixtures in edentulous patients treated with mandibular fixed tissue-integrated prosthesis. *J Prosthet Dent* 1988; 5: 59-63.
- 32- Fatzad P, Andersson L, Nyberg J. Dental implant treatment in diabetic patients. *Imp Dent*. 2002; 11:262-267
- 33- Bocci, V., Luzzi, E., Corradeschi, F., Silvestri, S. "Studies on the biological effects of ozone: 6. Production of transforming growth factor by human blood after ozone treatment". *J Biol Regul Homeost Agents*. 1994; 8: 108-112.
- 34- Cromack DT, Porrás-Reyes B, Purdy JA, Pierce GF, Mustoe TA. "Acceleration of tissue repair by transforming growth factor beta1: identification of in vivo mechanism of action with radiotherapy-induced specific healing deficits". *Surgery* 1993; 113: 36-42.
- 35- Jazwa A, Loboda A, Golda S, Cisowski J, Szelag M, Zagorska A, Sroczynska P, Drukala J, Jozkowicz A, Dulak J. Effect of heme and heme oxygenase-1 on vascular endothelial growth factor synthesis and angiogenic potency of human keratinocytes. *Free Radic Biol Med*. 2006; 40:1250–1263.
- 36- Nissen NN, Polverini PJ, Koch AE, Volin MV, Gamelli RL, DiPietro LA. Vascular endothelial growth factor mediates angiogenic activity during the proliferative phase of wound healing. *Am J Pathol*. 1998; 152:1445–1452.
- 37- Bocci V, Borrelli E, Travagli V, Zanardi I. The ozone paradox: ozone is a strong oxidant as well as a medical drug. *Med Res Rev*. 2009; 29:646-682.

- 38- Bocci V, Luzzi E, Corradeschi F. Studies on the biological effects of ozone: Cytokine production and glutathione levels in human erythrocytes. *J Biol Regul Homeost Agents* 1993; 7: 133-138.
- 39- Stubinger S, Sader R, Philippi A. The use of ozone in dentistry and maxillofacial surgery: a review. *Quintessence Int.* 2006; 37: 353-359.
- 40- Guanache D, Zamora Z, Hernandez F, Mena K, Alonso Y, Roda M. Effect of ozone/oxygen mixture on systemic oxidative stress and organic damage. *Toxicol Mech Methods.* 2010; 20: 25-30.
- 41- Valentine GS, Foote CS, Greenberg A, Liebman JF. Active oxygen in Biochemistry. 8Th Ed. Blackie Academic and Professional. London 1995; pp. 60-90.
- 42- Romanos GE, TohCG, Siar CH. Histologic and histomorphometric evaluation of per-implant bone subjected to loading: an experimental study with *Macaca Fascicularis*. *Int J Oral Maxillofac Implants* 2002; 17: 44-51.
- 43- Barone A, Convanicl, Cornelini R. Buccolingual bone remodeling around implants placed into extraction Sockets. *J Periodontol.* 2003; 74: 268-273
- 44- Sanseverino, E. R Knee-joint disorders treated by oxygen-ozone therapy. *Europa Medicophysica* 1989; 25: 163-170.
- 45- Sunnen GV. Ozone in medicine: Overview and future directions. *Journal of Advancement in Medicine* 1988; 1: 159-174.
- 46- Travagli V, Zanardi I, Bocci V. Topical applications of ozone and ozonized oils as anti-infective agents: an insight into the patent claims. *Recent Pat Antiinfect Drug Discov.* 2009; 4: 130-142.
- 47- Joos U, Wiesmann H P, Szuwart T, Meyer U. Mineralization at the interface of implants. *Int. J. Oral Maxillofac. Surg.* 2006; 35: 783-790.