

Percutaneous Interventions in Patients with Fontan Circulation

Intervenciones percutáneas en pacientes con circulación de Fontán

MARÍA V. LAFUENTE¹, JOSÉ ALONSO², JOSÉ L. PIBERNUS³, FRANCISCO COMAS⁴, CLAUDIA N. VILLALBA^{MTSAC, 5}, MARIELA MOURATIAN⁶, HORACIO FAELLA^{MTSAC, 7}, PABLO GARCÍA DELUCIS⁸, ALBERTO SCIEGATA^{MTSAC, 9}, HORACIO CAPELLI^{MTSAC, 10}

ABSTRACT

Background: Total bypass surgery of the pulmonary ventricle is a palliative procedure with high incidence of complications requiring careful postoperative follow-up. Interventional catheterization plays an essential role in the early detection and possible treatment of complications.

Objective: The aim of this study was to describe the interventional catheterization procedures performed in patients with Fontan circulation.

Methods: Between 1999 and 2014, 85 patients with Fontan surgery underwent 154 interventional catheterization procedures, with mean postoperative follow-up of 7.05 years (± 4.8 years).

Results: Different interventional catheterizations were performed: 38 patients underwent closure at the fenestration level and 4 underwent reopening. Forty-four catheterization procedures were done in 37 patients for aortopulmonary collateral vessel embolization; 28 patients required embolization of veno-venous collaterals; in 13 patients, after angioplasty of pulmonary branches, 7 stents were implanted at the extracardiac conduit level, and after angioplasty, 3 stents were implanted in 4 patients; antegrade flow was occluded in 4 patients, in 2 patients the atrioventricular valve was closed and 5 patients underwent other procedures. No complications were associated with interventional catheterization procedures. Twenty percent of interventional catheterizations were performed immediately after surgery due to Fontan circulation dysfunction. Short-term mortality was associated with the severe complications characteristic of the disease ($p=0.0007$). Long-term mortality was 5%.

Conclusions: Patients with Fontan circulation required diverse catheterization procedures, both in the immediate postsurgical period as in the long-term follow-up. The most frequent cause for recatheterization was hemoptysis secondary to aortopulmonary collateral vessel circulation. In no case were there complications associated with the interventional catheterization procedure. Mortality was related with the need for catheterization in the immediate postoperative period to treat severe complications of the Fontan circulation. Interventional catheterization is essential in the management of patients with Fontan circulation.

Key words: Fontan - Fontan-Kreutzer - Right Heart Bypass - Interventional Catheterization

RESUMEN

Introducción: La cirugía de bypass total del ventrículo pulmonar es un procedimiento paliativo con una incidencia elevada de complicaciones, por lo que requiere un seguimiento minucioso. El cateterismo intervencionista tiene un papel fundamental en la detección precoz y eventual tratamiento de las complicaciones.

Objetivo: Describir los cateterismos intervencionistas a los que se sometieron los pacientes con circulación de Fontan.

Material y métodos: Entre 1999 y 2014 se identificaron 85 pacientes con cirugía de Fontan a quienes se les realizaron 154 cateterismos intervencionistas, con un tiempo medio de seguimiento posquirúrgico de 7,05 ($\pm 4,8$) años.

Resultados: Los cateterismos intervencionistas fueron variados: a nivel de la fenestración, se procedió al cierre en 38 pacientes y a la reapertura en 4. En 37 pacientes se realizaron 44 cateterismos para embolización de colaterales aortopulmonares; 28 pacientes requirieron embolización de colaterales venovenosas; en 13 pacientes, previa angioplastia de ramas pulmonares, se colocaron 7 stents a nivel del conducto extracardíaco y, previa angioplastia, en 4 pacientes se implantaron 3 stents; en 4 pacientes se ocluyó el flujo anterógrado, en 2 se cerró la válvula auriculoventricular y en 5 se realizaron otros procedimientos. No hubo complicaciones relacionadas con el cateterismo intervencionista. El 20% de los cateterismos intervencionistas se realizaron en el posquirúrgico inmediato por disfunción de la circulación de Fontan. La mortalidad temprana estuvo relacionada con las complicaciones graves e inherentes a la patología ($p = 0,0007$). La mortalidad alejada fue del 5%.

Conclusiones: Los pacientes con circulación de Fontan requirieron una gran diversidad de cateterismos intervencionistas, tanto en el posquirúrgico inmediato como en el seguimiento alejado. La causa más frecuente de recateterismo fue la hemoptisis secundaria a circulación colateral aortopulmonar. En ningún caso hubo complicaciones vinculadas al cateterismo intervencionista. La mortalidad estuvo relacionada con la necesidad de cateterismo en el posquirúrgico inmediato para tratar complicaciones graves de la circulación de Fontan. El cateterismo intervencionista es fundamental en el manejo de los pacientes con circulación de Fontan.

Palabras clave: Fontan - Fontan-Kreutzer - Bypass de ventrículo subpulmonar - Cateterismos intervencionistas

REV ARGENT CARDIOL 2016;84:228-234. <http://dx.doi.org/10.7775/rac.v84.i3.7676>

Received: 12/12/2015 – Accepted: 04/27/2016

Address for reprints: Dra. María Victoria Lafuente - Charcas 4091 - (1425) CABA - Tel. 011 4831-1524 - e-mail: viquilafuente@yahoo.com.ar

Department of Cardiology and Hemodynamics, Hospital Nacional de Pediatría "Prof. Dr. Juan P. Garrahan". Buenos Aires, Argentina
^{MTSAC} Full Member of the Argentine Society of Cardiology

Abbreviations

AV	Atrioventricular	IVC	Interventricular communication
IAC	Interatrial communication	ECG	Electrocardiogram

INTRODUCTION

Patients with Fontan surgery require careful follow-up and early detection of complications that alter normal circulation in this type of surgery, since it operates with an already fragile hemodynamic condition and with little reserve against overload situations. Interventional catheterizations are an essential tool in the management of immediate and long-term post-operative Fontan surgery.

The different options of endovascular treatment included in this work are fenestration closure or reopening, collateral embolization, treatment of lesions in the Fontan circuit, residual antegrade pulmonary flow occlusion, atrioventricular (AV) valve closure and other procedures.

Subpulmonary ventricular bypass is the surgical option for managing patients with univentricular heart physiology; however, it is a palliative surgery with high incidence of complications and events both in the immediate and long-term post-operative periods. The purpose of this study was to describe the different interventional catheterizations to which patients with Fontan circulation were subjected considering the clinical indication of the procedures.

METHODS

Among a total of 380 patients with Fontan surgery, a retrospective cohort study was performed including 85 consecutive patients undergoing 154 interventional catheterization procedures from 1999 to 2014, with mean postoperative follow-up of 7.05 years (± 4.8 years).

The different bypass techniques of the subpulmonary ventricle were extracardiac (n=78), atriopulmonary (n=4) and intracardiac lateral tunnel (n=1).

Follow-up

All patients were evaluated at our institution by physical exam, electrocardiogram (ECG), pulse oxymetry, thorax tele-X-ray, transthoracic color Doppler echocardiography and hemodynamic study depending on the findings.

Technique

Catheterizations were performed in the hemodynamics laboratory with biplanar Toshiba equipment under general anesthesia, mechanical respiratory assistance, continuous ECG cardiac monitoring, pulse oxymetry and non-invasive pressure assessment. After local antiseptic treatment of the puncture area, guidewire insertion was performed with the Seldinger technique. Mainly, a femoral approach was used and jugular or transhepatic access was chosen as alternative approach. Sodium heparin 100 IU/kg was administered prior to catheter insertion.

In all cases, a complete hemodynamic study was performed with pressure and gradient measurements and

blood samples for oxygen saturation in the different cardiac structures. Venous and arterial angiographies were also performed to evaluate collateral circulation, sites of stenosis, pulmonary branch distortions and obstructive lesions in systemic vessels. In all cases, stenoses in the pulmonary circuit were resolved and aortopulmonary collateral embolization was effected prior to fenestration closure. Subsequently, the corresponding occlusion test was done testing oxygen saturations, and arterial and/or venous pressures in the Fontan circuit.

To manage aortopulmonary collaterals and abnormal communications between the venous system and the pulmonary veins or the systemic atrium, a selective angiographic study was performed to establish with precision the anatomy, trajectory, diameter and length in order to choose the adequate occluder device, selecting a size 30-50% larger than the diameter of the vessel that had to undergo embolization. After occlusion, angiographic studies were repeated at 10 minutes to evaluate the results.

Statistical analysis

Data were stored in Excel 2003 Microsoft Office. Statistical analysis was performed with the Statistix 8.0 package. Frequency and/or percent distribution with respect to the total number of cases was established for all variables and, accordingly, values were expressed as fraction, mean and standard deviation or median. Fisher's exact test or the chi-square test was used to compare proportions. A p value < 0.05 was considered statistically significant.

Ethical considerations

The study was approved by the Institutional Ethics Committee.

RESULTS

A total of 154 interventional procedures were performed in 85 patients. Eighty-one percent of patients (n=69) required only one catheterization, 10.5% (n=9) required two, 3.5% (n=4) required three and 5% (n=3) required four. These procedures included diverse therapeutic interventions, as described below.

Fenestration management

Fenestration closure

Thirty-eight fenestrations were closed.

Thirty-one Amplatzer devices [2 for ductus ADO II, 4 for foramen ovale and 25 for interatrial communication (IAC)], 6 IAC devices of other brands (4 Helex, 2 Atriasept) and 2 CP covered stents were used.

The only patient receiving a cribriform Amplatzer device also required a second procedure due to residual short-circuit and a CP covered stent for definitive closure, and in another patient a CP covered stent was primarily used to occlude the fenestration.

Closure of permeable fenestration was indicated in patients with Doppler echocardiographic gradient below 10 mmHg, in case of cyanosis or with an ischemic neurological event.

Fenestration repermeabilization

In 4 patients the fenestration was repermeabilized and the indication for catheterization was due to Fontan system dysfunction, in 3 patients during the immediate postoperative period due to severe low cardiac output and in 1 patient with left heart hypoplastic diagnosis with protein-losing enteropathy in the long-term postoperative period.

In three cases only balloon fenestration dilatation was performed and in the remaining case a stent was also placed.

Collaterals

Aortopulmonary

Thirty-seven patients underwent aortopulmonary collateral embolization, and 7 of these patients required subsequent catheterizations to treat them. Gianturco coils were mainly used and in selected occasions microparticles above 700 microns were employed.

Hemoptysis was the clinical event in the 7 patients requiring other catheterization procedures. In most patients, collateral circulation was an eventual finding during the study protocol and in some patients for suspicion of its presence due to increased pulmonary vein velocity >0.8 m/s (Figure 1).

Venovenous:

The development of venovenous collateral circulation was the cause of cyanosis in 28 patients. Gianturco coils were mainly used for their closure and Plug-type devices were necessary in only 2 patients.

3- Procedures at the Fontan circuit level:

Interventions in the Fontan circuit were performed in 17 patients, both at the pulmonary branch level ($n=13$) as in the extracardiac conduit ($n=4$).

At the pulmonary branch level

Pulmonary branch stenoses were identified in 13 patients; effective percutaneous balloon angioplasty

was performed in 6 cases, while in 7 patients presenting recoil stent implantation was necessary to treat branch distortion (Figure 2).

The indications for these procedures were: system dysfunction with low cardiac output and persistent pleural effusion ($n=5$), cyanosis ($n=4$), prior pulmonary branch stenosis ($n=2$), protein-losing enteropathy ($n=1$) and plastic bronchitis ($n=1$).

At the extracardiac conduit level

In 4 patients, an extracardiac conduit intervention was performed due clinical signs of Fontan system failure.

Three stents were inserted at the extracardiac conduit level after undergoing balloon angioplasty. The indications were: persistent pleural effusion in one patient, cyanosis secondary to pulmonary fistulas to redirect the hepatic flow in another patient, and in one patient with dextroisomerism referred for study due to cyanosis, and in whom mild stenosis was verified in the inferior vena cava junction with the extracardiac conduit at the supra-hepatic vein level with Fontan dysfunction.

In one patient with arteriovenous fistulas who presented cyanosis, mild conduit stenosis was resolved with balloon angioplasty.

Antegrade flow

Pulmonary antegrade flow was occluded in 4 patients (3 with devices and 1 with coils). The clinical sign of pulmonary antegrade permeability was the presence of systolic murmur and the assessed data was pulmonary artery pulsatility with the Doppler study.

Atrioventricular valve closure

In two patients with left ventricular double input, it was necessary to occlude the right AV valve.

The first patient, with atriopulmonary surgery, who underwent right AV valve repermeabilization with circulation dysfunction, the AV valve was effectively closed with a Helex device.

The second patient, who underwent extracardiac conduit procedure that evolved to right ventricular failure, subaortic stenosis and sinus-node disease, was

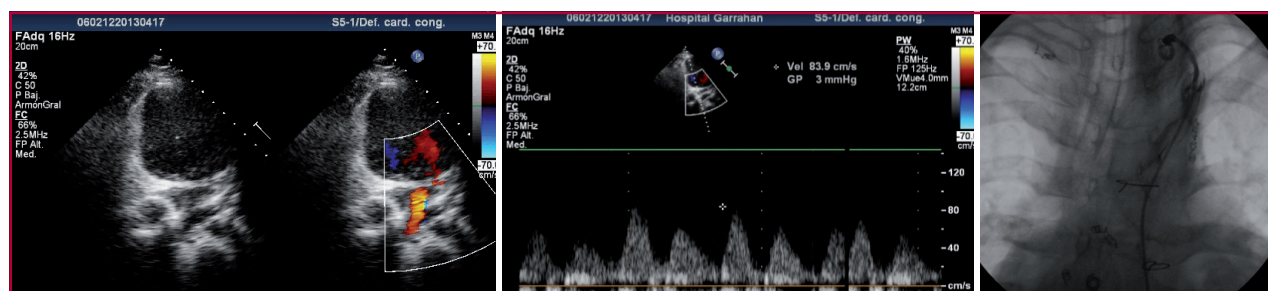


Fig. 1. A and B. Detection of increased velocity in the pulmonary veins by Doppler echocardiography. C. Angiographic confirmation and aortopulmonary collateral embolization.

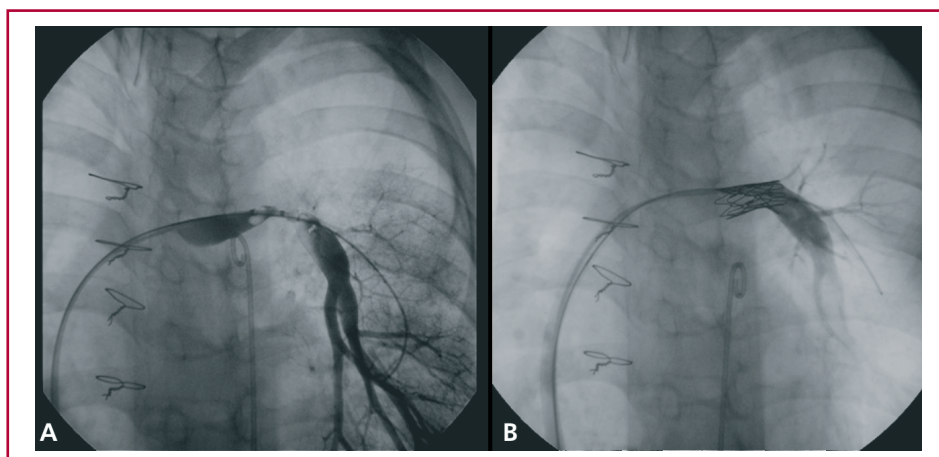


Fig. 2. Procedure on pulmonary branch stenosis. **A.** Severe stenosis of the left pulmonary branch. **B.** Angioplasty and stent implantation in the left pulmonary branch.

reoperated with surgical closure of the right AV valve, bulboventricular foramen enlargement and pacemaker implantation. Reopening of the AV valve was found at follow-up, needing two Amplatzer device implants to close it.

Other interventional procedures

Closure of residual short-circuits

In a patient undergoing lateral tunnel technique of the cava veins which evolved to cyanosis, dehiscence closure in the tunnel with a Helex device was partially successful.

Thromboexclusion

Right ventricular thromboexclusion was performed in a patient with diagnosis of pulmonary atresia and intact septum. In this case, the patient was studied for presenting cyanosis, and prior to fenestration closure with confirmed coronary circulation independent of the right ventricle, coils were implanted in the hypoplastic right ventricular chamber to occlude it.

Aortic coarctation

In one case with recoarctation identified in the context of a study for cyanosis, effective angioplasty was done in the recoarctation region.

Hepatic vein closure

A patient with right isomerism and suprahepatic veins connected to the atrium as fenestration progressed with cyanosis, presenting numerous venous collaterals connected to the right atrium by two suprahepatic veins, which were occluded with IVC Amplatzer No 10, plus two Plug No 8 and No12 devices (Figure 3).

Arteriovenous fistulas

A patient progressed with cyanosis due to the development of numerous diffuse fistulas predominantly at the base of the right lung. Several catheterizations were necessary for their treatment. In a first procedure, coils were used for the embolization of several

fistulas and concomitantly, the obstruction at the level of the extracardiac conduit was also treated. The following catheterization procedure was planned to redirect flow stent towards the right branch using a stent. Right mid and inferior lobe fistula embolization was performed using coils and two Plug II No 6 and No8 devices. In the last procedure, a Plug No 18 device was used to close the right inferior and mid lobar branches. The patient currently remains with 91-92% oxygen saturation (Figure 4).

Complications and mortality

No procedure-related complications were found in any of the diverse interventional catheterizations to which patients were subjected.

Eighty percent of catheterizations were performed in the long-term follow-up.

In 17 patients (20%), 20 interventional catheterizations were conducted in the immediate postoperative period due to Fontan circulation dysfunction, with severe cardiac output involvement, cyanosis, persistent effusions, and hemoptysis among other conditions (Figure 5). Six patients from this group died in the immediate postoperative period as a result of veno-occlusive disease of the pulmonary venous return, pulmonary thromboembolism, conduit thrombosis, diffuse brain edema, plastic bronchitis and in-hospital infection. Immediate postoperative mortality was associated with complications inherent to Fontan circulation ($p=0.007$) and not to the different types of interventional catheterizations that included most of the procedures described, mainly fenestration repermeabilization and procedures at the Fontan circuit level.

Long term mortality was 5% ($n=4$) and the causes identified were ventricular dysfunction, numerous diffuse arteriovenous fistulas and pulmonary thromboembolism in a patient with atrial flutter.

Fontan surgery survival in this group of patients was 96%, 92% and 84% at 5, 10 and 15 years, respectively.

DISCUSSION

Fontan surgery is a palliative procedure with a high incidence of adverse events as described during the follow-up of our population. (1, 2) Cardiac catheterization allows detecting complications and eventually

treating them, as reported by Kreutzer et al. (3, 4)

Fenestration management in the follow-up of patients with Fontan circulation is a controversial topic of discussion for teams treating these patients. Some propose a set of rules to be used as guidelines for fen-

Fig. 3. Multiple interventional catheterizations in a patient with dextroisomerism. **A.** Angiography showing the connection with the right atrium. **B.** Angiography of the Fontan circuit. **C.** Balloon occlusion. **D.** Amplatzer closure of suprahepatic veins. **E.** Angiography of two venous collaterals. **F.** Plug closure of two collaterals.

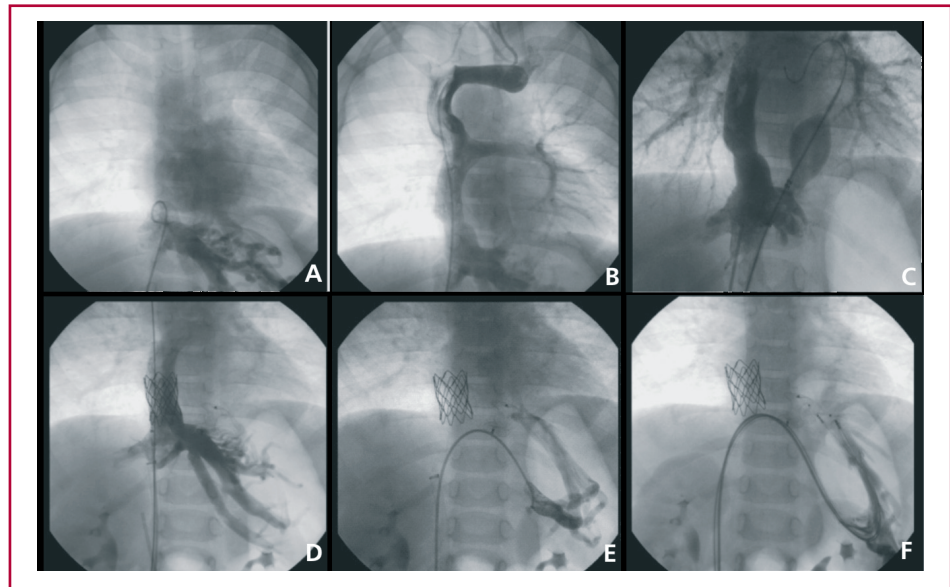
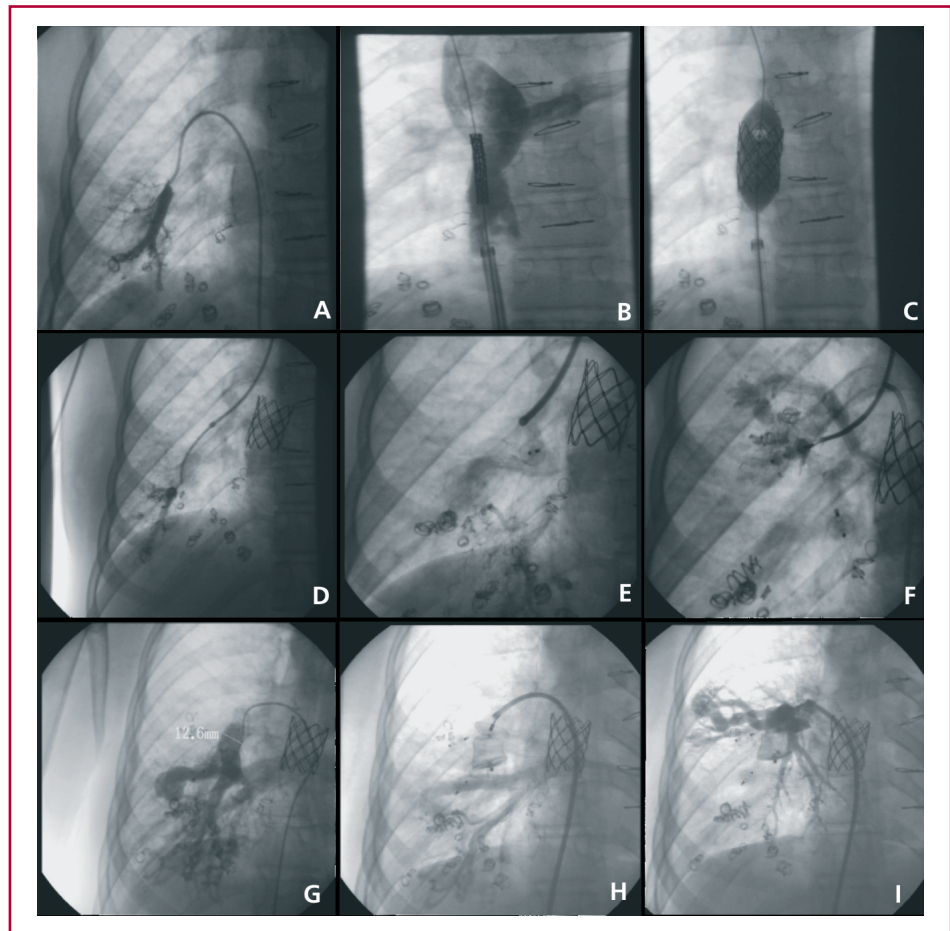


Fig. 4. Multiple interventional catheterizations in a patient with dextroisomerism. **A.** Angiography showing the connection with the right atrium. **B.** Angiography of the Fontan circuit. **C.** Balloon occlusion. **D.** Amplatzer closure of suprahepatic veins. **E.** Angiography of two venous collaterals. **F.** Plug closure of two collaterals.



estration management. (5-8) We consider fenestration closure in patients who had cyanosis or resting oxygen saturation <90% and in patients with a neurological ischemic event.

Fenestration repermeabilization in cases of Fontan circuit dysfunction improved patient condition in agreement with published reports. (9)

During the hemodynamic study, a significant number of patients presented, as additional finding, aortopulmonary collateral circulation that generates chronic volume overload and is the leading cause of hemoptysis. There are reports of massive bleeding (10, 11) and recurrence; (12) however, the incidence of hemoptysis in patients with Fontan circulation is unknown. Triedman et al. (13) found a prevalence of 30% aortopulmonary collaterals.

Veno-venous collateral embolization was one of the most frequently performed procedures. Although it improves oxygen saturation, (14) we need to continue the evaluation in the long-term follow-up, as some reports postulate lower survival in high-risk patients, as in the atriopulmonary technique, heterotaxies and pressures >18 mmHg in the Fontan circulation. The latter would benefit from the natural form of self-fenestration associated with the development of veno-venous collaterals. (15)

Procedures at the level of the Fontan circulation have allowed solving complex medical conditions such as low cardiac output, protein-losing enteropathy, plastic bronchitis, and cyanosis by diffuse arterio-

venous fistulas, as also reported by other authors. (9, 16-18)

Treatment of multiple, diffuse and microscopic arteriovenous fistulas is complex. Lack of liver factor could be a trigger for their formation; (19-21) in our group it was necessary to redirect hepatic flow by means of stent implantation. (18)

Fontan circulation has an unstable equilibrium and any variable that alters its normal functioning may result in its impairment, with system failure leading to conditions difficult to manage and with mortality risk both in the immediate and long-term postoperative follow-up. Patients with Fontan surgery were subjected to different procedures and the results obtained by our group (22) are encouraging and show that it is safe, effective and repeatable, in agreement with other authors. (3, 23) Cardiac percutaneous intervention has different and advanced devices tailored to meet the diverse complications and/or findings encountered during the hemodynamic study. (5, 6, 24)

Limitations

Due to its retrospective nature, the study has the inherent limitations of this methodology. It was possible to identify the clinical indications of interventional catheterization for this specific and special population. Concerning the management of fenestrations in the follow-up period, there are no specific guidelines and protocolized studies are difficult to perform since every patient requires unique management. Regarding other forms of collateral circulation diagnosis such as cardiac magnetic resonance imaging, this is not available in our area despite being a safe tool for the follow-up of this group of patients; however, clinical suspicion and Doppler echocardiography provide enough information to be alert to such diagnosis.

CONCLUSIONS

- Patients with Fontan circulation required a wide variety of interventional procedures, both in the immediate and long-term postoperative follow-up.
- The most common cause of recatheterization was hemoptysis secondary to aortopulmonary collateral circulation that required coil embolization.
- The clinical condition of cyanosis was the main reason for catheterization.
- No case presented with complications related to interventional catheterization.
- Mortality was associated with the need for immediate postoperative catheterization ($p=0.0007$) to treat severe complications of the Fontan circulation.
- Interventional catheterization is essential in the management of patients with Fontan circulation.

Conflicts of interest

None declared. (See authors' conflicts of interest forms in the website/Supplementary material).

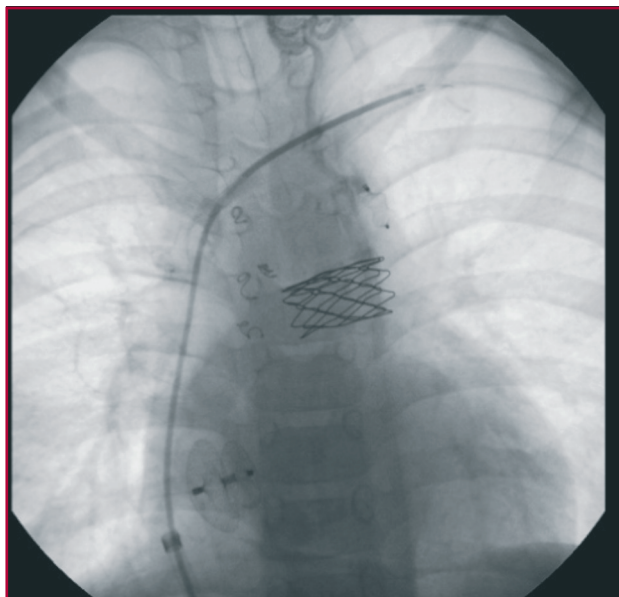


Fig. 5. Multiple procedures in the immediate postoperative period of a patient with low cardiac output, pleural effusion and cyanosis. Fenestration closure with Amplatzer, aortopulmonary collateral embolization with coils, veno-venous collateral occlusion with 8 mm Plug and stent in the left pulmonary branch.

REFERENCES

1. Lafuente MV, Di Santo M, Mouratian M, Villalba C, Sciegata A, Saad A et al. Total Right Heart Bypass: Long-Term Complications and Survival. *Rev Argent Cardiol* 2013;81:383-385. <http://doi.org/bf4h>
2. Deal B, Jacobs M. Management of the failing Fontan circulation. *Heart* 2012;98:1098-104. <http://doi.org/bf4j>
3. Kreutzer J. Cateterismo intervencionista en pacientes con circulación tipo Fontan. *Rev Argent Cardiol* 1996;64:379-88.
4. Kreutzer J, Graziano J, Stapleton G, Rome J. Late catheter interventions in hypoplastic left heart syndrome. *Cardiol Young* 2011;21:65-76. <http://doi.org/cg75rg>
5. Kotani Y, Chetan D, Saedi A, Zhu J, Grosse-Wortmann L, Coles JG, et al. Persistent fenestration may be a marker for physiologic intolerance after Fontan completion. *J Thorac Cardiovasc Surg* 2014;148:2532-8. <http://doi.org/bf4k>
6. Imielski BR, Woods RK, Mussatto KA, Cao Y, Simpson PM, Tweddell JS. Fontan fenestration closure and event-free survival. *J Thorac Cardiovasc Surg* 2013;145:183-7. <http://doi.org/bf4m>
7. Agnoletti G, Bordese R, Corletto A, Gabbarini F, Marini D. Interventional catheterization after total cavopulmonary connection: experience in 68 patients. *J Interv Cardiol* 2012;25:622-7. <http://doi.org/bf4n>
8. Atz AM, Trivison TG, McCrindle BW, Mahony L, Quartermain M, Williams RV, et al. Late status of Fontan patients with persistent surgical fenestration. *J Am Coll Cardiol* 2011;57:2437-43. <http://doi.org/bm92qw>
9. Kreutzer J, Lock JE, Jonas RA, Keane JF. Transcatheter fenestration dilation and/or creation in postoperative Fontan patients. *Am J Cardiol* 1997;79:228-32. <http://doi.org/bt2hw5>
10. Otilio JK, Tuuri R, Watson T, Titus MO. Massive hemoptysis in a post-Fontan procedure patients. *Pediatr Emerg Care* 2013;29:212-4. <http://doi.org/bf4p>
11. Bédard E, Lopez S, Perron J, Houde C, Couture C, Vaillancourt R, et al. Life-threatening hemoptysis following the Fontan procedure. *Can J Cardiol* 2008;24:145-7. <http://doi.org/dq28zm>
12. Suda K, Matsumura M, Sano A, Yoshimura S, Ishii T. Hemoptysis from collateral arteries 12 years after a Fontan-type operation. *Ann Thorac Surg* 2005;79:e7-8. <http://doi.org/bjz773>
13. Triedman JK, Bridges ND, Mayer JE Jr, Lock JE. Prevalence and risk factors for aortopulmonary collateral vessels after Fontan and bidirectional Glenn procedures. *J Am Coll Cardiol* 1993;22:207-15. <http://doi.org/fbqpzt>
14. Lluri G, Levi DS, Aboulhosn J. Systemic to pulmonary venous collaterals in adults with single ventricle physiology after cavopulmonary palliation. *Int J Cardiol* 2015;189:159-63. <http://doi.org/bf4q>
15. Poterucha JT, Johnson JN, Taggart NW, Cabalka AK, Hagler DJ, Driscoll DJ, et al. Embolization of veno-venous collaterals after the Fontan operation is associated with decreased survival. *Congenit Heart Dis* 2015;10:E230-6. <http://doi.org/bf5c>
16. John AS, Johnson JA, Khan M, Driscoll DJ, Warnes CA, Cetta F. Clinical outcomes and improved survival in patients with protein-losing enteropathy after the Fontan operation. *J Am Coll Cardiol* 2014;64:54-62. <http://doi.org/f2sthg>
17. Avitabile C, Goldberg, Dodds K, Dori Y, Ravishankar, Rychik J. A multifaceted approach to the management of plastic bronchitis after cavopulmonary palliation. *Ann Thorac Surg* 2014;98:634-40. <http://doi.org/bf5d>
18. Dori Y, Sathanandam S, Glatz AC, Gillespie MJ, Rome JJ. Catheter approach to redirect hepatic venous return for treatment of unilateral pulmonary arteriovenous malformation after Fontan. *Catheter Cardiovasc Interv* 2014;84:86-93. <http://doi.org/bf5f>
19. Srivastava D, Preminger T, Lock JE, Mandell V, Keane JF, Mayer JE Jr, et al. Hepatic venous blood and the development of pulmonary arteriovenous malformations in congenital heart disease. *Circulation* 1995;92:1217-22. <http://doi.org/bf5f>
20. Field-Ridley A, Heljasvaara R, Pihlajaniemi T, Adatia I, Sun C, Keller R, et al. Endostatin, an inhibitor of angiogenesis, decreases after bidirectional superior cavopulmonary anastomosis. *Pediatr Cardiol* 2013;34:291-95. <http://doi.org/bf5g>
21. Kavarana M, Jones J, Stroud R, Bradley S, Ikonomidis J, Mukherjee R. Pulmonary arteriovenous malformations after the superior cavopulmonary shunt: mechanisms and clinical implications. *Expert Rev Cardiovasc Ther* 2014;12:703-13. <http://doi.org/bf5h>
22. Alonso J, Lafuente V, Ramírez Aguilar R, Pibernus J, Sciegata A, Comas F, et al. Manejo de la cianosis en pacientes con circulación tipo Fontan-Kreutzer. *Revista Argentina de Cardioangiología* 2013;4:92-8.
23. Kaulitz R, Ziemer G, Paul T, Peuster M, Bertram H, Hausdorf G. Fontan-type procedures: residual lesions and late interventions. *Ann Thorac Surg* 2002;74:778-85. <http://doi.org/fg3kzm>
24. McMahan CJ, El Said HG, Vincent JA, Grifka RG, Nihil MR, Ing FF, et al. Refinements in the implantation of pulmonary stents: impact on morbidity and mortality of the procedure over the last two decades. *Cardiol Young* 2002;12:445-52. <http://doi.org/dwjbh6>