

ISSN: 2340-3438

Edita: Sociedad Gallega de
Otorrinolaringología.

Periodicidad: continuada.

Web: www.sgorl.org/revista

Correo electrónico:

actaorlgallega@gmail.com

SGORL PCF
Sociedad Gallega de Otorrinolaringología
y Patología Cervicofacial



Acta Otorrinolaringológica Gallega

Caso clínico

Anterior unilateral non-arteritic ischemic optic neuropathy after cervical oncologic surgery. *A unique case and a review of the literature*

Neuropatia óptica isquémica anterior não arterítica unilateral após cirurgia oncológica cervical.

Caso único e revisão da literatura

Ângela Reis-Rego¹, Ana Nóbrega Pinto¹, Mariline Santos¹, David Afonso Dias², Telma Susana Feliciano¹, Cecília de Almeida e Sousa¹.

¹ ENT department, Centro Hospitalar do Porto (Portugal).

² Ophtalmology department, Centro Hospitalar do Porto (Portugal).

Recibido: 1/2/2017 Aceptado: 30/3/2017

Abstract

This article presents a unique clinical case in the literature and bibliographic review on the subject. The main purpose is to highlight non-arteritic anterior ischemic optic neuropathy (NA-AION) as a rare but possible cervical surgery complication that must be explained to patients before the procedures, especially those at risk.

Keywords: non-arteritic anterior ischemic optic neuropathy, blindness, head and neck surgery, patient safety, informed consent.

Resumo

Este artigo apresenta um caso clínico único na literatura e respectiva revisão bibliográfica. O objectivo principal é destacar a neuropatia óptica isquémica anterior não-arterítica (NOIA-NA) como uma complicação cirúrgica rara, mas possível, que deve ser explicada aos pacientes antes dos procedimentos otorrinolaringológicos da cabeça e pescoço, especialmente àqueles em risco.

Palavras-chave: Neuropatia óptica isquémica anterior não arterítica, cegueira, cirurgia de cabeça e pescoço, segurança do paciente, consentimento informado.

Correspondencia: Ângela Reis-Rego
Centro Hospitalar do Porto (Portugal).
Correo electrónico: angelareisrego@gmail.com

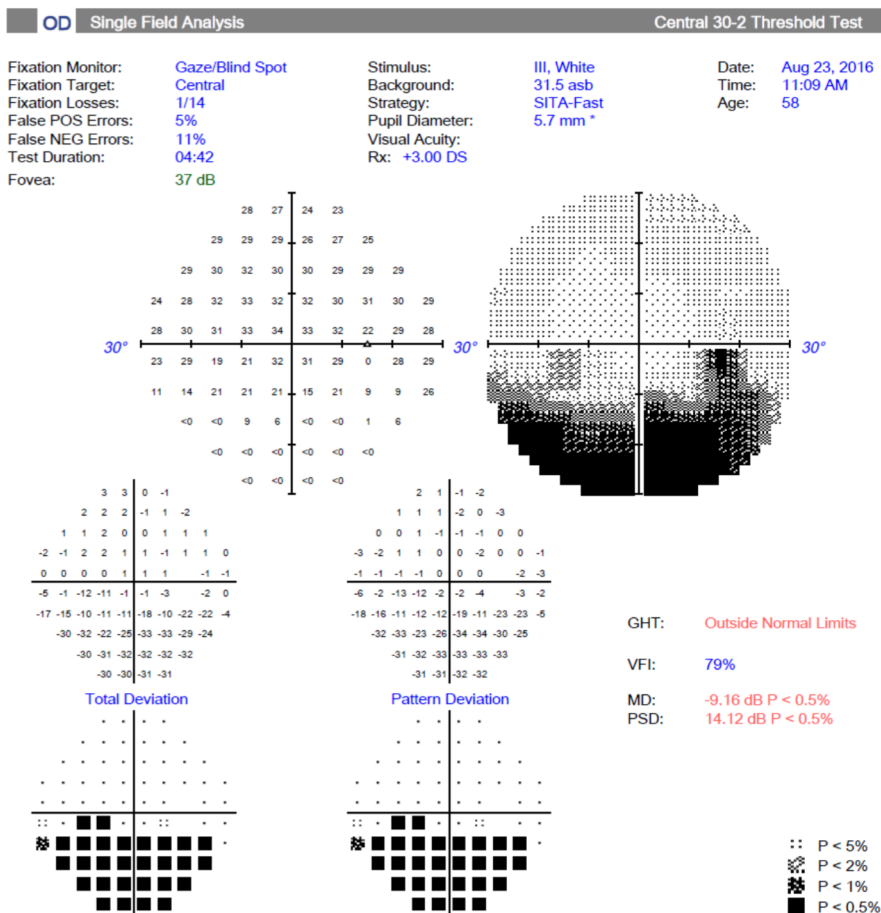
Introduction

The loss of vision after non-ocular surgery is very rare, with an incidence between 0.003% - 0.008%¹. NA-AION corresponds to the minority of cases of vision loss after non-ocular surgery and is triggered by: prolonged surgery time, hypotension, anemia, arteriosclerosis, hypertension, diabetes, cervical lymphedema and hypercoagulability^{1,2}.

Case Report

Herein we present the case of a 58-year-old male, non-smoker for 20 years with hypotensive tension profile and no other relevant background. He came to our ENT department, a tertiary referral centre, with 3 month long persistent dysphonia, with no other associated symptoms. A locally invasive laryngeal neoplasia was diagnosed. He underwent total laryngectomy with functional bilateral cervical ganglion dissection, complicating at day 12 with bilateral cervical hematoma drained surgically at the 16th day after laryngectomy. On the 17th day, he developed painless visual restriction of the right eye in the lower nasal quadrant with papillary edema and peri-papillary hemorrhages in the upper quadrants, with no other neurological alterations; NA-AION was diagnosed (figure 1). The patient initiated AAS 100 mg 1 id, with no improvement. During his internment, a daily and asymptomatic hypotensive profile was recorded as the only precipitating factor of NA-AION, including during both surgeries. He was referred for external consultation of ophthalmology after hospital discharge. At present, the ocular disease is stable and the cervical ecodoppler realized was normal.

Figure 1: Right eye campime-try showing visual restriction of the right eye in the lower nasal quadrant.



Discussion

NA-AION after head and neck surgery is often bilateral, directly related to jugular resection, and occurs preferentially in the immediate postoperative period^{3,4}. Only 5 cases have been described so far, all of them bilateral, and in all but one, there was a jugular compromise, with total or near total visual loss. In these cases, there were considerable blood losses and operation times between 6 to 13 hours³⁻⁷. On the contrary, our patient lost 650 ml of blood without hemodynamic repercussion on a 3 hour 45 minutes procedure with 12mg/dl hemoglobin before and 10.8 mg/dl after the procedure; in the decompression surgery hemoglobin levels were 11.1 mg/dl before and 9.4 mg/dl after the procedure and 10.7 mg/dl on discharge. In the present case, we propose that cervical decompression surgery may have caused an increase in intra-ocular pressure, triggering ischemia, a mechanism facilitated by the hypotensive profile of the patient. This mechanism is supported by the fact the patient underwent other two orthopedic operations with general anesthesia, without any complications.

Conflict declaration: The authors declare no conflicts

References

- 1- Agostini T, Lazzeri D, Agostini V, Mani R, Shokrollahi K. Ischemic optic neuropathy and implications for plastic surgeons: report of a new case and review of the literature. *Ann Plast Surg.* 2011;66(4):416-420.
- 2- Kitaba A, Martin DP, Gopalakrishnan S, Tobias JD. Perioperative visual loss after nonocular surgery. *J Anesth.* 2013;27(6):919-926.
- 3- Gotte K, Riedel F, Knorz MC, Hormann K. Delayed anterior ischemic optic neuropathy after neck dissection. *Arch Otolaryngol Head Neck Surg.* 2000;126(2):220-223.
- 4- Suarez-Fernandez MJ, Clariana-Martin A, Mencia-Gutierrez E, Gutierrez-Diaz E, Gracia-Garcia-Miguel T. Bilateral anterior ischemic optic neuropathy after bilateral neck dissection. *Clin Ophthalmol.* 2010;4:95-100.
- 5- Aydin O, Memisoglu I, Ozturk M, Altintas O. Anterior ischemic optic neuropathy after unilateral radical neck dissection: Case report and review. *Auris Nasus Larynx.* 2008;35(2):308-312.
- 6- Strome SE, Hill JS, Burnstine MA, Beck J, Chepeha DB, Esclamado RM. Anterior ischemic optic neuropathy following neck dissection. *Head Neck.* 1997;19(2):148-152.
- 7- Wilson JF, Freeman SB, Breene DP. Anterior ischemic optic neuropathy causing blindness in the head and neck surgery patient. *Arch Otolaryngol Head Neck Surg.* 1991;117(11):1304-1306.