

Revista Electrónica Nova Scientia

Evaluación de tres diferentes posiciones de los puertos de entrada para la funduplicatura de Nissen laparoscópica en conejos

Evaluation of three different positions of laparoscopic ports for Nissen fundoplication in rabbits

Carlos Arturo Rodríguez-Alarcón¹, José Ángel Maciel-Salas¹, Ramón Rivera-Barreno¹, Hugo Staines-Orozco², Jhon Didier Ruiz-Buitrago³, Carlos Andrés Hernández-López³ y Diana Marcela Beristain-Ruiz¹

¹ Departamento de Ciencias Veterinarias, Universidad Autónoma de Ciudad Juárez, Ciudad Juárez, Chihuahua, México

² Departamento de Ciencias Médicas, Universidad Autónoma de Ciudad Juárez, Ciudad Juárez, Chihuahua, México

³ Facultad de Medicina Veterinaria y Zootecnia, Universidad CES, Medellín, Antioquia, Colombia

México - Colombia

Diana Marcela Beristain Ruiz. E-mail: diana.beristain@uacj.mx

Resumen

Introducción: La cirugía laparoscópica pediátrica establece nuevos desafíos para los cirujanos; Consecuentemente, existe la necesidad de una formación adecuada antes de realizar los procedimientos directamente en los pacientes. Han sido diseñados diferentes modelos para el entrenamiento quirúrgico, incluyendo simuladores virtuales y animales vivos. Sin embargo, el entrenamiento con modelos animales es el método más apropiado para la instrucción quirúrgica, puesto que reproduce condiciones quirúrgicas similares. El objetivo de este estudio fue establecer la localización adecuada de los puertos de entrada para la funduplicatura de Nissen en cadáveres de conejos, tanto para fines experimentales como de enseñanza.

Método: el estudio fue llevado a cabo usando seis cadáveres de conejo Nueva Zelanda. La ubicación de los trocares fue establecida por dos veterinarios y un pediatra con experiencia en cirugía laparoscópica. El modelo fue evaluado por cuatro cirujanos pediatras. Se utilizó un trocar de 5 mm, y se insertó un laparoscopio de 5 mm con 30 ° conectado a una micro-cámara. Se insufló el abdomen (a una presión de 6-8 mm Hg). La colocación de trocares secundarios se realizó con visualización directa. Para establecer la ubicación de los trocares se consideraron varios factores como la anatomía del estómago y esófago del conejo, la realización de la funduplicatura laparoscópica de Nissen en conejos con instrumental laparoscópico convencional y la longitud de los instrumentos laparoscópicos pediátricos. Se realizaron tres abordajes con el fin de establecer una vista satisfactoria de la zona quirúrgica. A cada posición nueva de los puertos se les asignó una puntuación: un punto cuando existió cruce de los instrumentos, un punto cuando los órganos estaban demasiado lejos para manipular y un punto cuando estaban muy cerca para manipular. La posición se consideró ideal cuando el valor fue cero. Para estimar el grado de concordancia entre observadores se utilizó el coeficiente Kappa de Fleiss para 4 observadores.

Resultados: Fue posible obtener un valor de cero en el último abordaje. La posición de los trócares quedó establecida de la siguiente manera: el puerto del telescopio fue colocado en la línea media 1,6 cm caudal a la cicatriz umbilical (2.0 cm insuflado) y con los puertos secundarios situados ligeramente laterales a las terceras glándulas mamarias. Para establecer la localización exacta de estos trócares se implantó un punto 1,5 cm caudal al puerto del telescopio. Después de formar un ángulo de 90 °, se midieron 3,3 cm en cada lado. Estas últimas medidas se tomaron con el conejo insuflado.

Discusión o Conclusión: En esta investigación se establecieron las posiciones apropiadas de los puertos de trabajo, sin causar fatiga de la articulación de la muñeca del cirujano y con un espacio adecuado para un movimiento confortable. Además, se reducirá el uso de conejos vivos para el establecimiento de los puertos en investigaciones futuras, abrazando el concepto de las tres “Rs” en la experimentación con animales. Con este modelo se obtuvo una excelente visión del campo quirúrgico sin interferencia entre el instrumental y el telescopio.

Palabras Clave: laparoscopia, modelos quirúrgicos animales, funduplicatura de Nissen, conejos, cirugía.

Recepción: 16-07-2016

Aceptación: 03-09-2016

Abstract

Introduction: Paediatric laparoscopic surgery provides new challenges for surgeons; therefore there is a need for adequate training before performing procedures directly on patients. Several different models were designed for training, including both virtual simulators and live animals. However, training with animal models is the most appropriate method for surgical instruction, as it reproduces similar surgical conditions. The objective of this study was to establish the best localization of surgical ports for Nissen fundoplication in rabbit cadavers for both experimental and teaching purposes.

Method: The research was conducted using six New Zealand white rabbit cadavers. The location of the trocars was established by two veterinary and one paediatric with experience in laparoscopy surgery. The model was evaluated by four paediatric surgeons. A 5 mm trocar was used, and a laparoscope of 5 mm and 30° attached to a microcamera was inserted. The abdomen was insufflated (to a pressure of 6-8 mm Hg). The placement of secondary trocars was conducted with direct visualization. Diverse factors were considered to establish the location of the trocars such the anatomy of the rabbit stomach and esophagus, laparoscopic Nissen fundoplication performed in rabbits with conventional laparoscopic instruments, and the length of paediatric laparoscopic instruments. Three approaches were repeated in order to locate a satisfactory view of the surgical area. Every position of the ports received a score: one point was scored when the

instrumentation was crossed, one point when the organs were too far away to manipulate, and one point when the organs were too close to manipulate. The position was considered ideal when a zero value was obtained. Fleiss Kappa coefficient for 4 raters was used to estimate the level of concordance between observers.

Results: It was possible to obtain a value of zero in the latter approach. The position of the trocars was established in the following way: the telescope port positioned at midline 1.6 cm caudal to the umbilical scar (2.0 cm with insufflation), and with the secondary ports placed slightly lateral to the third mammary glands. To establish the exact location of these trocars a point was established at 1.5 cm caudal to the telescope trocar. After forming an angle of 90° , 3.3 cm were measured on each side. These last measures were taken with the abdomen insufflated.

Discussion or Conclusion: In this research was established the appropriate positions of the working ports, without causing fatigue of the operator's wrist joint and with adequate space for comfortable movement. In addition, this would also reduce the use of live rabbits for the establishment of the ports in future research, accepting the concept of the three "Rs" for animal experimentation. With these models was obtained an excellent view of the surgical field without interference between the instruments and telescope.

Keywords: laparoscopy, surgical animal models, Nissen fundoplication, rabbits, surgery

Introduction

Laparoscopic surgery requires the development of fast, effective and reliable learning techniques, that initially it should be practiced outside of the operating room. Laparoscopic surgery has led to the development of techniques for surgeons to improve their skills. Several models for teaching and practice have been used, including inanimate simulators, cadavers (human and animal) and live anaesthetised animals, progressing to finally operating on true patients, which initially should always be under the direct supervision of expert surgeons (Usón *et al.*, 2006).

The use of anaesthetised animal models has the advantage of working on living tissue that may bleed, similar to a real situation. But these procedures are expensive and require special equipment and qualified personnel (Reznick *et al.*, 2006). However, until technology advances to achieve a high degree of realism with simulation that is cost-effective, surgery with animal models is the most appropriate procedure for surgical learning (Gomez-Fleitas, 2005; Rodriguez-Garcia *et al.*, 2006).

It is necessary to develop animal models realistic for training laparoscopic surgeons, which can simulate the situations experienced in endosurgery. Laparoscopy differs from traditional surgery, because surgeons need to acquire motor coordination for using a new surgical instrument, do not have direct tactile sensation with tissues, and need to guide their maneuvers via a two-dimensional view of a three-dimensional field (Menezes, 2012).

The rabbit is currently used as a model for teaching paediatric surgery (Hernández *et al.*, 2012). Its size closely resembles surgical conditions of infants (Simforoosh *et al.*, 2011).

Paediatric laparoscopy has progressed slowly because the instrumentation is more precise and must be adapted to the size of the paediatric patient. This involves a steep learning curve (Álvarez-Zapico, 2001). However, currently about 60% of paediatric surgeries are performed laparoscopically and 80% of paediatric surgeons are familiar with these techniques (Ure *et al.*, 2000).

The objective of this study was to establish working ports for the introduction of paediatric laparoscopic equipment to perform Nissen fundoplication in rabbits for experimental and teaching purposes. The goal was to ensure that the surgeon had an excellent view of the surgical field, without interference between the instruments and the lens. The results are not intended for use in paediatric surgery. Instead, this research was performed so that investigators will not need to spend time finding the appropriate location for the ports in future research.

Materials and methods

This study was approved by the Ethics and Animal Welfare of the Universidad Autónoma de Ciudad Juárez (CBE.ICB/001.01-25)

To conduct this study, six New Zealand white rabbit cadavers were used (each weighed 2.5 to 3.5 kg). These cadavers were collected from the surgical practices of the medicine students. Animals were handled and euthanized (Sodium Pentobarbital at 100 or > mg/kg IV) according to the Mexican Official Norm: Technical specifications for the production, care and use of laboratory animals (NOM 062-ZOO 1999). Only rabbits without previous abdominal surgery were included. A 5 mm trocar was introduced by the Hasson technique, and a laparoscope of 5 mm and 30° attached to a microcamera was inserted through the trocar. The abdomen was insufflated (to a pressure of 6-8 mm Hg). The placement of secondary trocars was conducted with direct visualization. The position of the trocars was established by two veterinary surgeons and one paediatric surgeon with experience in laparoscopy. The model was evaluated by four paediatric surgeons.

To establish the exact location of the ports some factors were considered: 1) the anatomy of the rabbit stomach and esophagus (Rodríguez-Alarcón *et al.*, 2010; Halabi *et al.*, 2012), 2) laparoscopic Nissen fundoplication performed in rabbits with traditional laparoscopic instruments, and 3) the length of paediatric laparoscopic instruments.

Several approaches were repeated in order to find an adequate view of the surgical area. As an initial procedure, a telescope trocar was inserted 0.4 cm caudal to the umbilicus. Then we inserted the telescope trocar every 0.4 cm until achieving an adequate image. Once an adequate image was obtained, ports were established. Trocars were inserted 0.5 cm caudal and 0.5 cm lateral to the telescope trocar on each side. This created a space of 0.5 cm both medially and caudally, which allowed for an angle of 45° between the two laparoscopic forceps, therefore establishing adequate distance from the instruments to the surgical site without the instruments crossing in the path of the telescope. Each position of the trocars received a score: one point was scored when the instrumentation was crossed, one point when the organs were too far away to manipulate, and one point when the organs were too close to manipulate. The maximum score was 2 points and the location was considered ideal when a zero value was obtained.

Fleiss Kappa coefficient was used to estimate the level of concordance between observers. The Fleiss Kappa coefficient result must be interpreted as follows: values ≤ 0 indicates no

agreement, values $\geq 0.01 \leq 0.20$ indicate none to slight concordance, values $\geq 0.21 \leq 0.40$ indicate fair concordance, values $\geq 0.41 \leq 0.60$ indicate moderate concordance, values $\geq 0.61 \leq 0.80$ indicate a substantial concordance, values $\geq 0.81 \leq 1.00$ indicate a perfect concordance between the observers (McHugh, 2012).

Results

In the first two approaches a crossing of instruments occurred and in addition the distance was very close to the surgical field. Therefore a value of 2 points was obtained in the evaluations of pediatric surgeons. However, it was possible to obtain a value of zero in the latter approach. We established that the best trocar location for laparoscopic Nissen fundoplication in rabbits was with the telescope port positioned at midline 1.6 cm caudal to the umbilicus (with insufflation the distance was 2.0 cm) (Figure. 1), and with the secondary ports placed slightly lateral to the third mammary glands. To establish the exact location of these ports a point was established at 1.5 cm caudal to the telescope port. After forming an angle of 90° , 3.3 cm were measured on each side. These last measures were taken with the rabbit model abdomen insufflated (Figure.1).

In this research, the Fleiss Kappa for 4 raters was 1.00 that means a perfect concordance.

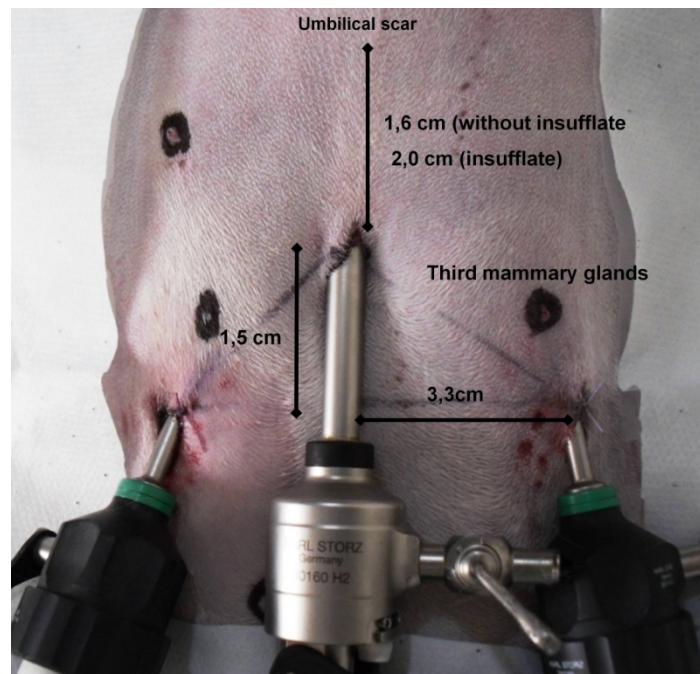


Figure 1- Establishing the measures for the ports. The middle port is a 5 mm to the telescope. The side ports are a 3mm for laparoscopic forceps.

Discussion

This study is the first to describe the position of the ports using only three trocars and laparoscopic paediatric equipment in an insufflated rabbit cadaver. A previous investigation had already described the trocar position for Nissen fundoplication in the rabbit (Luks *et al.*, 1995). However, Luks *et al.* (1995) surgery was different because it was a gasless laparoscopy. Another difference was that, Luks *et al.*, used five trocars and in our model only 3 trocars were used. We used fewer trocars because we did not use a liver retractor, and instead, the liver lobules were separated with the same forceps used for dissection.

Optimal trocar positioning is essential in laparoscopic procedures because this helps achieve an ergonomically correct body position. Incorrect trocar placing could cause fatigue of the wrist joint and lack of space for comfortable movement (Ballesteros *et al.*, 2007; Marhuenda *et al.*, 2011; Pérez-Duarte *et al.*, 2012).

Actually there is no uniform consensus about port placements for laparoscopic procedures; neither in human surgery nor in animal models. The placement of ports is currently established by the surgeon's preference based on personal practice. In an adult human, for example, the target organ should be located 15–20 cm from the optical trocar. Generally, the two remaining trocars are placed in the same 15–20 cm arc at 5–7 cm on either side of the optical trocars. This permits the instruments to work at a 60°–90° angle with the target organ and avoids problems from the target organs being too far or too near the ports (Trejo *et al.*, 2007; Supe *et al.*, 2010). To facilitate optimal instrument manipulation along with satisfactory visualization during laparoscopy, trocars are usually placed in a triangular fashion, termed triangulation (Supe *et al.*, 2010). In our research, placing the telescope trocar at 1.5 cm from the umbilicus allowed us to comply with these points. In addition, in the present investigation, the ports were introduced keeping in mind the "base-ball diamond" concept previously mentioned in other studies^{19,20} (Kaur, 2008; Modi *et al.*, 2013). First, the telescope was fixed in between the working instruments. Second, half of each instrument was placed inside the surgical site and half was kept outside, maintaining an elevation angle of 30°. Third, the manipulation angle was set to 60°, and fourth, the azimuth angle was set 30°. The definition of the diverse angles is listed below, as described by Kaur in 2008:

- Elevation Angle: It is the angle between the instrument and the body of the patient.
- Manipulation Angle: It is the angle between the two working instruments.

- Azimuth Angle: It is the angle between an instrument and the telescope.

These ergonomic characteristics should also be followed when using surgical animal models. In this study we described the best trocar placement for laparoscopic Nissen fundoplication in the rabbit, in order to avoid fatigue when investigating or practicing, using rabbit models. In this investigation, the position of the ports allowed an adequate view of the surgical area. Additionally, the port distances described allowed the laparoscopy instruments to arrive adequately at the area of the fundoplication, without crossing of the instruments and interference with the telescope, which allowed the surgery to be performed correctly (Figure 2).

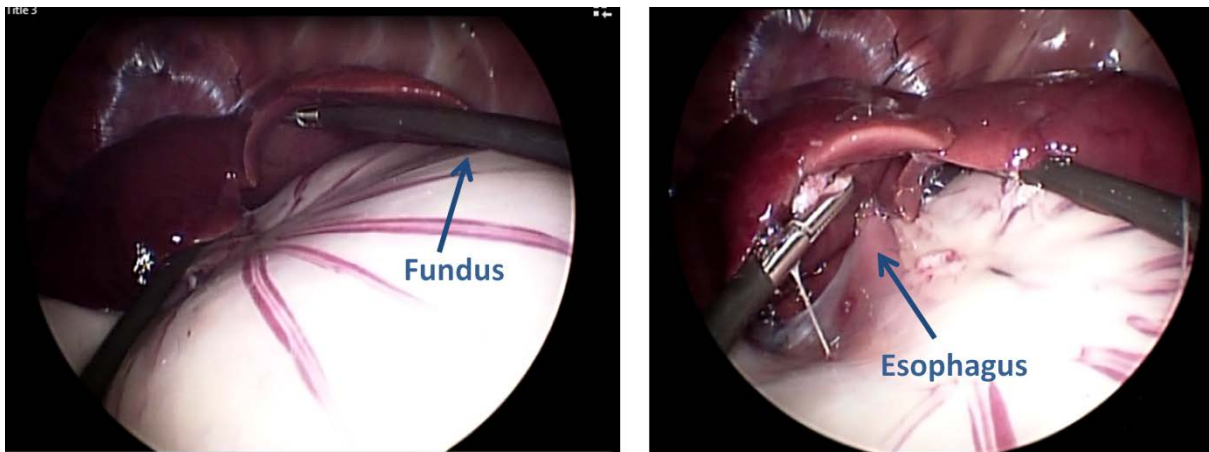


Figure 2- In photography laparoscopic forceps perfectly come into contact with the gastric fundus and esophagus can be observed. We can also observe how instrumental never cross with one another and not have interference with the telescope.

Conclusion

We established the proper position of trocar ports for laparoscopic Nissen fundoplication in rabbits: The telescope trocar located at midline 1.6 cm caudal to the umbilicus (with insufflation the distance was 2.0 cm). The secondary ports positioned slightly lateral to the third mammary glands. To establish the precise location of these ports a point was established at 1.5 cm caudal to the telescope port. After forming an angle of 90° , 3.3 cm were measured on each side (Figure. 1).

The results of this investigation will help, when using the rabbit as a model for teaching paediatric laparoscopic Nissen fundoplication, as surgeons learning this procedure will not have to take time to find the most appropriate site for placement of trocars and instruments.

Acknowledgments

This project received support from PROMEP-SEP (Secretariat of Public Education, Mexico) The authors also gratefully acknowledge the indispensable contributions of colleagues and personal of Experimental Surgery Center of the Autonomous University of Juarez.

Competing interests statement

None of the authors of this paper has a financial or personal relationship with other people or organizations that could inappropriately influence or bias the content of the paper.

Referencias

Álvarez-Zapico, J. A. (2001). Current status and indications of minimally invasive surgery in pediatrics. *Bol. Pediatr.* 41, 190-194.

Ballesteros, P. M., B. J. Domínguez, C. J. Zarco, D. B. Fernández, M. C. Martínez, M. M. Fernández, M. F. Vaquero (2007). An experimental study using pigs for the dissection and suturing of aortic grafts by means of laparoscopy. *Angiología.* 59, 427-432.

Gomez-Fleitas, M. (2005). The need for changes in surgical training: an unresolved problem in endoscopic surgery. *Cir. Esp.* 77, 3-5

Halabi, M. T., Bahamondes, F. Cattaneo, G. Arado, L. Flores E. (2012). Rabbit stomach: animal model for experimental surgery. *Int. J. Morphol.* 30, 82-87.

Hernández, A. J., Ibarra, C. I., Chaparro, A. I., Castellano, E. E., Imery, G. A., Cantele, H. E., Troconis, E. (2012). El conejo como modelo experimental de entrenamiento en cirugía laparoscópica pediátrica *Arch. Venez. Puer. Ped.* [online] 75, 6-10.

Kaur, G. (2008). Role of OT table height on the task performance of minimal access surgery. *World. J. Laparosc. Surg.* 1, 49-55.

Luks, F. I., Peers, K. H., Deprest, J. A., Lerut T. E. (1995). Gasless laparoscopy in infants: the rabbit model. *J Pediatr Surg.* 30(8), 1206-1208.

Marhuenda, C., Giné, C., Asensio, M., Guillen, G., Martínez-Ibañez V. (2011). Robotic surgery: first pediatric series in Spain. *Cir. Pediatr.* 24, 90.

McHugh, M. L.. (2012). Interrater reliability: the kappa statistic. *Biochem Med.* 22, 276-282.

Menezes, C. L. M. (2012): Rabbit corpse (*Oryctolagus cuniculus*) preservation with modified Larssen solution for training in videolaparoscopic surgery. Master Dissertation. Postgraduate program, Veterinary Sciences of Veterinary Faculty Universidade Federal do Rio Grande do Sul. Porto Alegre, Brazil. (in Portuguese)

Modi, Y. S., Kuswaha, M. R., Dave, S. P. (2013): Awareness of Ergonomic Guidelines regarding laparoscopic surgeries, its Practice among Surgeons and Comfort level during and after surgery. Gujarat. Med. J. 68, 31-34.

Nom, Norma Oficial Mexicana. "062-ZOO-1999." (2001) Especificaciones técnicas para la producción, cuidado y uso de los animales de laboratorio.

Pérez-Duarte, F. J., Sánchez-Margallo, F. M., Martín-Portugués, I. D. G., Sánchez-Hurtado, M. Á., Lucas-Hernández, M., Usón-Gargallo J. (2012). Ergonomy in laparoscopic surgery and its importance in surgical training. Cir. Esp. 90, 284-291.

Reznick, R. K., Macra, E. H. (2006). Teaching surgical skills--changes in the wind. N. Engl. J. Med. 355, 664-2669.

Rodríguez-Alarcón, C. A., Pérez E., Martín, U., Rivera, R., Hernández, A., Vivo, J., Beristain, M., Usón J. (2010). Morphometry of the abdominal esophagus and stomach of the rabbit. Laparoscopic surgery applications. Int. J. Morphol. 28, 27-31.

Rodriguez-Garcia, J. L., Turienzo-Santos, E., Vigal-Brey, G., Brea-Pastor A. (2006). Surgical training with simulators in training centers. Cir. Esp. 79, 342-348.

Simforoosh, N., Khazaeli, M., Nouralizadeh, A., M. H. Soltani, M. H., Samzadeh, M., Saffarian, O., Rahmani J. (2011). Laparoscopic animal surgery for training without sacrificing animals; introducing the rabbit as a model for infantile laparoscopy. J. Laparoendosc. Adv. Surg. Tech. A. 21, 929-933.

Supe, A.N., Kulkarni, G. V., Supe, P. A. (2010). Ergonomics in laparoscopic surgery. J Minim Access Surg. 6:31-36.

Trejo, A., Jung, M. C., Oleynikov, D., Hallbeck M. S. (2007). Effect of handle design and target location on the insertion and aim with a laparoscopic surgical tool. Appl. Ergon. 38, 745-53.

Ure, B.M., Bax, N. M., van der Zee D. C. (2000). Laparoscopy in infants and children: a prospective study on feasibility and the impact on routine surgery. J Pediatr. Surg. 35, 1170-1173.

Usón, J., Sánchez, F.M., Díaz-Guemes, M.I., Loscertales-Matín de Agar, B., Soria-Galvez F. & Sánchez-Gijón P. Animal models in urological laparoscopic training. Actas. Urol. Esp. 30, 443-450 (2006).

