

Aortic Valve Reconstruction with Autologous Pericardium

This is the case of a 15-year old patient with history of rheumatic fever at the age of 8 years, who in the first control visit to a cardiologist presented trivial aortic regurgitation with a normal aortic valve and one year later evolved with fast progression of the aortic regurgitation. During the last 6 months, the patient developed impaired functional capacity due to exercise-induced dyspnea and was referred to the cardiovascular surgeon by the attending cardiologist.

Color-Doppler echocardiography showed a dysplastic aortic valve, with thickened cusps, right and left commissural fusion and lack of coaptation, resulting in severe aortic regurgitation. The jet width was > 70% of the left ventricular outflow tract and the left ventricle was severely dilated (LVDD 60 mm) with preserved systolic function and reverse flow in the descending aorta.

The patient underwent aortic valve reconstruction with autologous pericardium.

The procedure was performed using the traditional technique: complete sternotomy, cardiopulmonary bypass (CPB), cannulation of the ascending aorta, venous drainage in the right atrium and antegrade HTK cardioplegia.

The full length of the anterior pericardium was harvested using harmonic scalpel to free pericardial attachments. The harvested pericardium was then treated with a 0.6% glutaraldehyde solution for 10 min (Figure 1A).

After aortotomy, the native bicuspid aortic valve (fibrotic, with commissural fusion and retraction) was resected, preserving the aortic annulus and the commissures. The distance between each commissure was then measured using a gauging apparatus specifically developed for this technique and the size of each cusp was individually determined (Figure 1B).

These parameters were then transferred to a self-

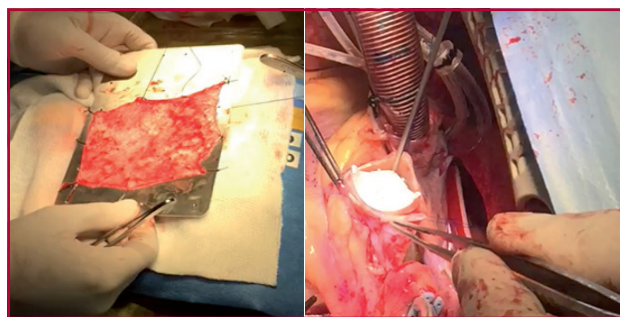


Fig. 1. A. Intraoperative image of glutaraldehyde-treated autologous pericardium. **B.** Gauging apparatus to measure intercommissural distance.

developed template designed to cut the pericardium into the three future aortic cusps which were sutured with 5/0 running Prolene stitches. The new valve reconstructed with autologous pericardium presented a coaptation zone >1 cm with no evidence of prolapse. Once the valve was reconstructed, the aortotomy was closed. After aortic-cross clamp removal and CPB discontinuation, intraoperative transesophageal echocardiography showed that the new tricuspid aortic valve, reconstructed with autologous pericardium, had an adequate surface of coaptation with no signs of valve regurgitation (Figure 2).

Aortic valve replacement with biologic or mechanical valve prosthesis is the conventional surgical treatment of aortic valve disease, as well as the indication of transaortic valve implant for a rapidly growing group of patients. However, the challenge in the discussion focuses on the child-adolescent or young population. The advantage of bioprostheses in aortic position is that they do not require patient anticoagulation; however, the structural damage and the need for early reoperation make this approach unsuitable for the young population. On the contrary, mechanical heart valve prostheses require lifelong anticoagulation therapy and international series have reported an incidence of major complications of 1-2%.

There are many techniques of aortic valve reconstruction currently available, depending on the morphology of the diseased valve, as commissurotomy, cusp resuspension, plication of cusp free edge, annuloplasty, decalcification, or cusp enlargement with pericardium, among others. Aortic valve preservation techniques, as the Yacoub or Tirone David procedures, are other possible options that can be used depending on the characteristics of the valve. The Ross procedure is a very good option in the young population due to its excellent hemodynamic profile and because the patients do not need anticoagulation therapy. However, the procedure requires a highly experienced surgical team and the pulmonary autograft may result in calcification, dilatation or dysfunction after 10 years.

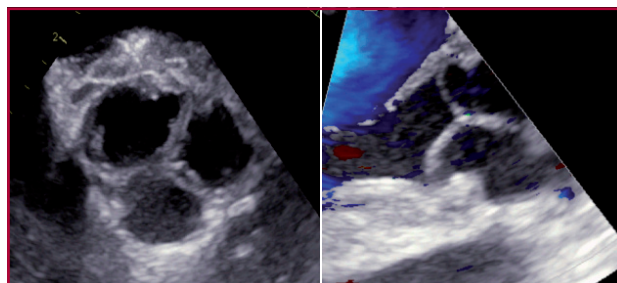


Fig. 2. Transesophageal echocardiography shows adequate cusp coaptation without aortic regurgitation.

The use of autologous pericardium is possible due to the biological stabilization with glutaraldehyde. This technique has been used for more than 30 years and many authors have developed different surgical approaches for partial or complete valve reconstruction. Carpenter et al. have reported that preservation with glutaraldehyde prevents calcification of aortic and mitral valve prostheses. (1)

Duran et al. presented their 16-year experience with reconstruction of the aortic valve with autologous pericardium treated with 0.5% buffered glutaraldehyde solution for 10 min. They used plastic measurement instruments to gauge and cast the pericardium to reconstruct the new aortic cusps. (2)

Based on these initial experiences, Ozaki et al. developed a new technique for aortic valve reconstruction with autologous pericardium which constitutes an attractive therapeutic option for some scenarios. The results presented are particularly encouraging in over 400 cases undergoing this technique, without conversions to prosthetic valve replacement and no in-hospital cardiovascular mortality. (3) This technique has also been used in patients with unicuspid, bicuspid or tetracuspid aortic valves. (4)

The main benefit of the procedure was the excellent hemodynamic results at early and mid-term due to the characteristics of the new valve (19.8 ± 10.2 mmHg 1 week after surgery and 13.8 ± 3.7 mmHg 3.5 years after surgery) with good quality of life without need for anticoagulation. (3) This characteristic has significant relevance in dialysis patients due to dialysis-related complications. (5)

In agreement with Ozaki et al., we did not perform internal or external aortic ring annuloplasty because our patients had normal aortic annulus. It is debatable whether this will have any impact on long-term outcome, as Lansac et al. have described. (6) The long-term results will be available in the future.

Conflicts of interest

None declared.

(See authors' conflicts of interest forms on the website/Supplementary material).

**Guillermo Vaccarino, Cristian Kreutzer,
Daniel Killinger, Benjamín Chiostrì,
Christian Gil, Gustavo Bastianelli**

Hospital Universitario Austral, Pilar, Buenos Aires, Argentina.
gvaccari@cas.austral.edu.ar

Rev Argent Cardiol 2018;86:49-50. <http://dx.doi.org/10.7775/rac.v86.i1.11479>

REFERENCES

1. Chachques JC, Vasseur B, Perier P, Balansa J, Chauvaud S, Carpentier A. A rapid method to stabilize biological materials for cardiovascular surgery. *Annals New York Academy Sciences* 1988; 529:184-6. <http://doi.org/fnbpmr>
2. Al Halees Z, Al Shahid M, Al Sanei A, Sallehuddin A, Duran C. Up to 16 years follow-up of aortic valve reconstruction with pericar-

dium: a stentless readily available cheap valve? *Eur J Cardiothorac Surg*. 2005;28:200-5. <http://doi.org/dzt7s7>

3. Ozaki S, Kawase I, Yamashita H, Uchida S, Nozawa Y, Takatoh M, et al. A total of 404 cases of aortic valve reconstruction with glutaraldehyde-treated autologous pericardium. *J Thorac Cardiovasc Surg* 2014;147:301-6. <http://doi.org/cmjb>

4. Ozaki S, Kawase I, Yamashita H, Uchida S, Nozawa Y, Takatoh M, et al. Reconstruction of Bicuspid Aortic Valve With Autologous Pericardium. *Circulation Journal*, 2014;78:1144-51. <http://doi.org/f528gr>

5. Kawase I, Ozaki S, Yamashita H, Uchida S, Nozawa Y, Matsuyama T, et al. Aortic valve reconstruction with autologous pericardium for dialysis patients. *Interact CardioVasc Thorac Surg* 2013;16:738-42. <http://doi.org/f4wzs2>

6. Lansac E, Di Centa I, Sleilaty G, Lejeune S, Berrebi A, Zacek P, et al. Remodeling root repair with an external aortic ring annuloplasty. *J Thorac Cardiovasc Surg*. 2017;153:1033-42. <http://doi.org/gbhjhs>

Severe Pulmonary Stenosis as Vascular Manifestation of Von Recklinghausen Disease in Adults

Neurofibromatosis type 1 (NF1), also known as Von Recklinghausen disease, is the most common neurocutaneous syndrome estimated to occur in approximately 1 out of every 3,300 infants. Despite the most frequent clinical manifestations are café au lait spots and cutaneous neurofibromas, the presence of multi-system involvement may lead to diverse clinical manifestations. (1, 2)

The cardiovascular manifestations include systemic hypertension and pulmonary artery hypertension, stenosis of the renal artery, congenital heart defects, hypertrophic cardiomyopathy and less frequently pheochromocytoma. In the National Neurofibromatosis Foundation International Database, among 2,322 patients with definite NF1, 2.3% presented cardiovascular abnormalities. Class II flow defects are the most common defects in the great vessels, and include pulmonary valve stenosis, pulmonary subvalvular stenosis and coarctation of the aorta. (3, 4) The diagnosis is commonly made during childhood and in young adults. (3-5)

We present a 71 year-old female patient who sought medical care due to class II-III dyspnea. At physical examination, an intense systolic murmur was heard at the pulmonic area accompanied by thrill. A particularly striking feature was the presence of large, soft, brownish-colored tumors on the face and trunk (Figure 1).

Two-dimensional echocardiography and Doppler ultrasound demonstrated the presence of severe pulmonary valve stenosis with a 100 mmHg gradient, mild subvalvular gradient in end-systole and mild dilation of the right chambers. Such findings correlated with those seen at cardiac magnetic resonance imaging, providing key information about the absence of other heart defects associated with the underlying disease (Figure 2).

The biopsy of a skin lesion showed well-circumscribed lesions composed of spindle-shaped cells with myxoid collagenized stroma, a typical finding of the disease. (5)

The patient underwent pulmonary valvuloplasty. The right femoral vein was accessed and the pulmonary valve was crossed with a 0.035" guidewire over which a pigtail catheter was advanced. The gradient across the pulmonary valve was 112 mmHg. Valvuloplasty was performed with a 20 mm balloon catheter (Cristal Ballon™) introduced over an extra support guidewire. A residual 2 mmHg gradient and a 20 mmHg infundibular gradient were recorded after the procedure.

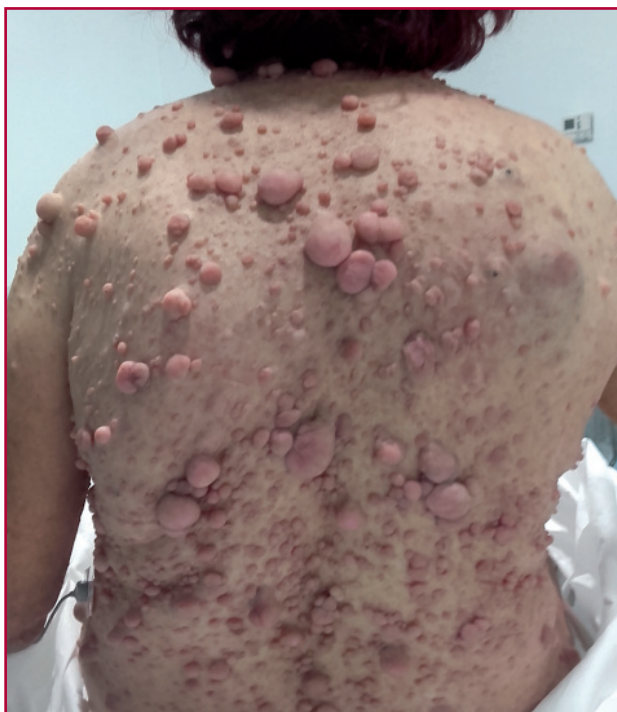

Fig. 1. Cutaneous neurofibromas.

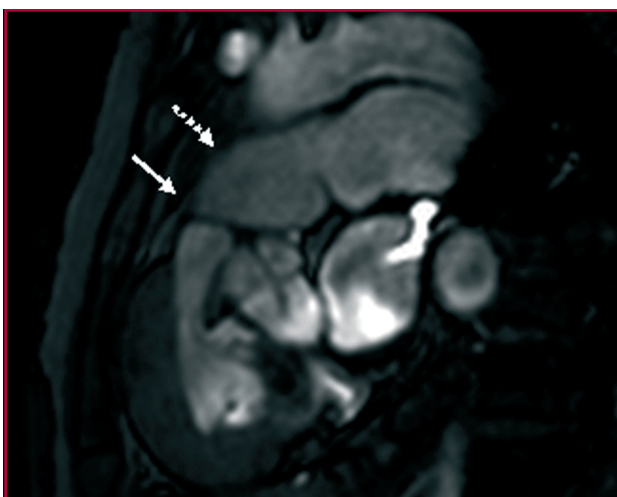

Fig. 2. Cardiac magnetic resonance imaging. Arrow: Area of valve stenosis. Dotted arrow: Poststenotic dilation of the pulmonary arteries.

The patient evolved with significant clinical improvement and was discharged on the following day.

Neurofibromatosis type 1 is a disease that can be identified during physical examination due to the presence of specific skin lesions. Once the disease is diagnosed, as cardiologists we should look for the presence of cardiovascular abnormalities and indicate surgery or percutaneous intervention depending on the case.

Conflicts of interest

None declared.

(See authors' conflicts of interest forms on the web/Supplementary material).

**Gabriel Dionisio, Leandro Puerta,
Alicia P. Terragno, Tomás Valverde,
Noemí León, Rolando Sequeiros**

Department of Hemodynamics and Interventional Cardiology.
Clínica Modelo Lanús.
gfdionisio75@gmail.com

Rev Argent Cardiol 2018;86:50-51. <http://dx.doi.org/10.7775/rac.v86.i1.11601>

REFERENCES

1. Ray AC, Karjyi N, Roy AN, Dutta AK, Biswas A. Seizure, spinal schwannoma, peripheral neuropathy and pulmonary stenosis - A rare combination in a patient of Neurofibromatosis 1. *Ann Indian Acad Neurol.* 2012;15:51-3. <http://doi.org/gcb2wb>
2. Listernick R, Charrow J. Neurofibromatosis Type 1 in childhood. *J Pediatr.* 1990;116:845-53. <http://doi.org/chtcc9>
3. ncecik F, Hergüner ÖM, Ahiç Erdem S, Altunba ak . Neurofibromatosis type 1 and cardiac manifestations. *Turk Kardiyol Dern Ars.* 2015;43:714-6. <http://doi.org/cmvd>
4. Lin AE, Birch PH, Korf BR, Tenconi R, Niimura M, Poyhonen M, et al. Cardiovascular malformations and other cardiovascular abnormalities in neurofibromatosis 1. *Am J Med Genet.* 2000;95:108-17. <http://doi.org/ds7qsp>
5. Tedesco MA, Di Salvo G, Natale F, Pergola V, Calabrese E, Grassia C, et al. The heart in neurofibromatosis type 1: an echocardiographic study. *Am Heart J.* 2002;143:883-8. <http://doi.org/dd4f56>

Giant Aneurysm of the Right Coronary Artery

Coronary artery aneurysm is defined as a dilatation exceeding 50% of the reference vessel diameter and is termed giant if the diameter exceeds the reference vessel diameter by four times or if it is >8 mm². Giant coronary aneurysms are rare in adults and are generally due to atherosclerosis, (1) while Kawasaki disease is the most common cause in infants. They can also be due to infections or may be congenital or develop after a coronary artery intervention. Coronary aneurysms are more frequently encountered in the right coronary artery, followed by the left anterior descending artery. (2) The natural history of this disease is still unclear, (3) as the few publications in the medical literature do not provide definite conclusions. Nevertheless, as any other aneurysm, those in the coronary arteries can undoubtedly complicate with thrombosis, embolization or rupture.

We report the case of a 70-year old male patient who was a former smoker and with history of hypertension and dyslipidemia. He was admitted due to inferior wall myocardial infarction that was not reperused with thrombolytic therapy because he arrived at the hospital beyond the therapeutic window. The patient evolved with chest pain which he described as oppressive, accompanied by sweating and dyspnea exacerbated by postural changes, orthostatic hypotension and presyncope. On interrogation, he reported presyncope episodes and dyspnea of some months' duration. Transthoracic echocardiogram revealed a rounded image containing fluid that compressed the right heart. Computed tomography angiography showed a 103 x 90 mm diameter image with well-defined borders and homogeneous content with intravenous contrast enhancement. Cardiac magnetic resonance image demonstrated that the rounded image containing fluid corresponded to the right coronary artery (Figure 1).

Coronary angiography demonstrates the presence of diffuse left coronary artery ectasia and a giant aneurysm of the right coronary artery. Figure 2 shows contrast material leak from the right coronary artery filling the aneurysm.

The patient underwent surgery. The intraoperative findings were similar to those described in imaging studies. Under cardiopulmonary bypass, the procedure consisted of aneurysm resection, plication of the edges, ligation of the right coronary artery and saphenous vein aortocoronary bypass graft to the posterior descending coronary artery. The patient evolved without complications or recurrent symptoms.

The aneurysm histopathology demonstrated the presence of fragments of fibrous tissue and laminar fibrin deposition with neutrophil accumulation.

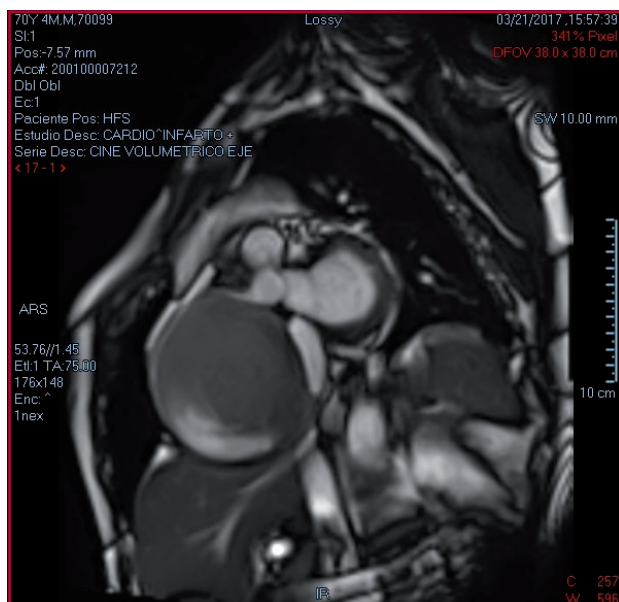


Fig. 1. Cardiac magnetic resonance image showing a rounded image containing fluid that corresponds to the right coronary artery

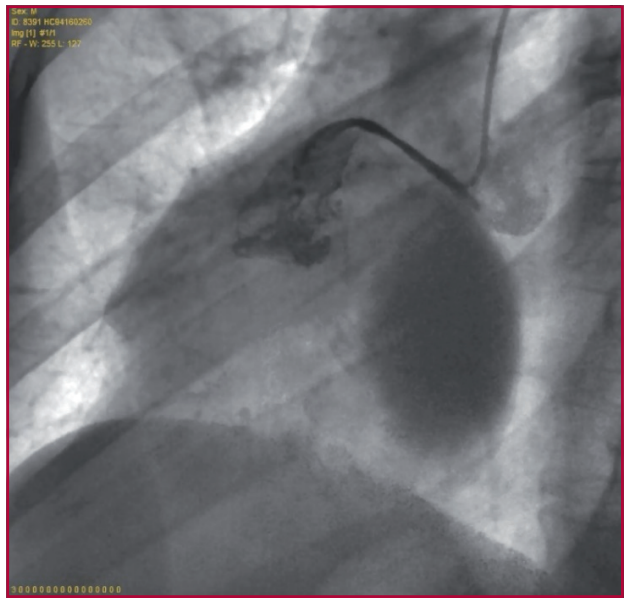


Fig. 2. Coronary angiography showing contrast material leak from the right coronary artery

The incidence of coronary artery aneurysms is about 1.4%; (4) they are mostly asymptomatic and are incidentally diagnosed in patients with ischemic heart disease. Surgery has excellent results in symptomatic patients with complicated aneurysm or with symptoms due to significant coronary artery stenosis. (5) In our case, the symptoms could not only be attributed to significant coronary artery stenosis but also to compression of the right heart due to the huge aneurysm size. Surgery was the adequate strategy as the patient had favorable outcome without recurrent symptoms. Atherosclerosis seems to be the etiology of the aneurysm considering patient's age, cardiovascular risk factors and diffuse coronary artery ectasia associated with non-significant coronary artery stenosis and the histopathologic finding of fibrous tissue with non-specific chronic inflammatory infiltrates. Yet other causes cannot be ruled out.

Conflicts of interest

None declared.

(See authors' conflicts of interest forms on the web/Supplementary material).

**Guillermo Giacomi, Alberto Fucaraci,
 Alejandro Delacasa, Marcelo Martínez Peralta,
 Pablo M. Rodríguez**

HIGA "Dr Oscar Allende", Mar del Plata, Buenos Aires, Argentina

Rev Argent Cardiol 2018;86:51-52. <http://dx.doi.org/10.7775/rac.v86.i1.12311>

REFERENCES

1. Robinson FC. Aneurysms of the coronary arteries. *Am Heart J* 1985;109:129-35.<http://doi.org/c6n2gx>

2. Topaz O, DiSciascio G, Cowley MJ, Goudreau E, Soffer A, Nath A, et al. Angiographic features of left main coronary artery aneurysms. *Am J Cardiol.* 1991;67:1139-42. <http://doi.org/b75tf5>
3. Robertson T, Fisher L. Prognostic significance of coronary artery aneurysm and ectasia in the coronary artery surgery study (CASS) registry. En: Shulman ST, ed. *Kawasaki disease. Proceedings of the second international symposium.* New York: A.R. Liss; 1987. p. 325-39.
4. Daoud AS, Pankin D, Tulgan H, Florentin RA. Aneurysms of the coronary artery: report of ten cases and review of literature. *Am J Cardiol* 1963;11:228-37. <http://doi.org/dvvd6>
5. Aintablian A, Hamby RI, Hoffman I, Kramer RJ. Coronary ectasia: incidence and results of coronary bypass surgery. *Am Heart J* 1978;96:309-15. <http://doi.org/dtxr7h>

High Defibrillation Thresholds in a Patient with Hypertrophic Cardiomyopathy and Implant of a Subcutaneous Defibrillator Electrode

Defibrillation testing during implantation or replacement of an implantable cardioverter defibrillator (ICD) implies inducing, detecting and terminating ventricular fibrillation (VF) as a measure of testing the device to estimate its ability to prevent sudden arrhythmic death. (1)

Threshold measurement or defibrillation testing are considered as part of the procedure during device implant to detect failures in the system or high defibrillation thresholds. Both conditions are rare and occur in less than 5% of the devices implanted and in 10% of the cases during the first implant. (2)

Defibrillation testing is currently recommended in patients undergoing implantation of a subcutaneous ICD (class I), is reasonable in patients undergoing a right-pectoral transvenous ICD implantation (class IIa) (1) and expert consensus recommends it for secondary prevention.

We report the case of a 25 year-old patient with hypertrophic obstructive cardiomyopathy diagnosed in the first months of life. He presented NYHA functional class II dyspnea during childhood and was treated with atenolol and verapamil, and at the age of 12, a dual chamber pacemaker was implanted to relieve symptoms.

In 2010 the patient presented exertion dyspnea as a consequence of atrial lead displacement which produced asynchronous ventricular pacing, and was referred to our center for lead replacement.

The echocardiogram did not show paradoxical septal motion and ventricular pacing produced moderate to severe mitral regurgitation. During sinus rhythm without ventricular pacing, septal thickness was 35 mm, posterior wall thickness 14 mm, the heart valves were normal and a left ventricular outflow tract gradient of 23 mmHg was recorded that increased to 45 mmHg with the Valsalva maneuver. The exercise stress test demonstrated abnormal blood pressure response and the 24-hour Holter monitoring showed sinus rhythm and isolated monomorphic ventricular premature beats.

As the patient presented high risk of sudden death, a dual-chamber ICD was implanted at the age of 20. Alejandro leads were extracted to prevent interferences. During defibrillation testing, the device failed to revert VF after two electrical shocks with maximum output (31 Joules) even after changing the polarity. For this reason, a high output ICD was implanted and VF was terminated with a rescue shock of 41 Joules.

The patient was followed-up at our institution. Four years later, he consulted due to electrical storm with 25 episodes of sustained ventricular tachycardia that were reverted with ventricular overdrive pacing or shock.

A few months later, the pacemaker battery became exhausted and the pacemaker was replaced by a high output generator. During defibrillation testing, the device failed to rescue after two shocks with maximum output and external rescue shocks were required. The change in shock polarity was not successful.

In a new procedure, an additional subcutaneous defibrillation lead (SQ 6996, Medtronic, Minneapolis, MN), was implanted and VF was induced and rescued by the device with 31 J. (Figure 1), with a safety margin of 41 J (maximum output).

The aim of this review is to analyze the possible options to manage this situation. The alternatives are to rule out situations that increase defibrillation threshold (ischemia, antiarrhythmic drugs); repositioning the right ventricular lead in case of a first procedure, use of high output defibrillators; placing a defibrillator lead via the azygous vein or coronary sinus leading towards the posterior lateral aspect of the left ventricle; inserting a subcutaneous defibrillator lead (SQ 6996, Medtronic, Minneapolis, MN); or as a last option, implanting epicardial patches by thoracotomy. We decided to implant a subcutaneous lead as it was the less aggressive approach for the patient.

Defibrillation threshold testing during the implantation of an ICD is useful to evaluate if the device senses and reverts the induced VF. Both ICD func-

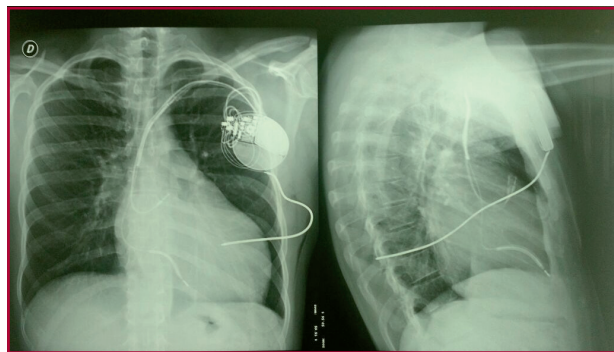


Fig. 1. Posteroanterior and lateral chest x-ray. The subcutaneous defibrillator catheter is tunneled posterior to the heart (SQ 6996, Medtronic, Minneapolis, MN).

tions, sensing and termination of the arrhythmia, are essential to prevent arrhythmic sudden death. The need for evaluating these parameters in patients undergoing implant for primary prevention is currently under discussion. (1)

We presented a young patient with hypertrophic cardiomyopathy and high defibrillation thresholds who needed generator replacement due to battery exhaustion. During the procedure, the device failed to rescue the induced VF despite using a high output defibrillator and making different changes in shock configuration (SVC coil to canister, RV coil to canister and turning off the activated canister or coils). The effectiveness of current defibrillator devices is greater when the RV coil serves as the anode, reducing the defibrillation threshold by 16%. Thus, the polarity change is justified in case of high thresholds when the RV coil is used as cathode. (2)

Some studies have demonstrated that patients with wide QRS with hypertrophic cardiomyopathy, non-ischemic dilated cardiomyopathy, those treated with amiodarone and candidates for cardiac resynchronization therapy have a trend toward higher defibrillation thresholds. (3) Other predictors associated with high defibrillation thresholds are FC III-IV, history of VF, coronary artery bypass surgery and low ejection fraction. (2)

Russo et al. reported that the use of only high-output defibrillator devices (41 J) was not enough to obtain an adequate security margin in 48% of the cases, as happened in our case. (4)

There are several options available when an adequate safety margin cannot be achieved during defibrillation testing. In some cases, implanting a defibrillation coil through selective cannulation of the azygos vein to the posterior wall of the heart provides a suitable shocking vector for effective defibrillation. The procedure is safe, without significant complications when the appropriate material is available, but requires experienced operators. (5)

The implant of a subcutaneous defibrillation lead is another option and we chose this approach for our patient. The 6996SQ (Medtronic, Minneapolis, MN) defibrillation lead is currently available in our country. This unipolar 7.5 French lead contains a 25-cm shocking coil lead that is implanted via a 10.5 French sheath through a subcutaneous tunnel and is positioned posteriorly. Many studies have demonstrated that this lead reduces the defibrillation threshold when it is added to an intravenous system. (6) The better efficacy can be attributed to the fact that the greater surface of the coil length directed posteriorly provides more homogeneous energy shock to the heart. (7-8)

Conflicts of interest

Dr. Claudio Muratore discloses that he works for Medtronic. (See authors' conflicts of interest forms on the web/Supplementary material).

**Eliana Aversa, Andrés Cronshey,
Juan Manuel Vergara, Carolina Menéndez,
Hector Mazzetti, Claudio Muratore**

Servicio de Electrofisiología - Hospital Juan A. Fernández
Cervino 3356 - (1425) CABA - e-mail: eliana-aversa@yahoo.com

Rev Argent Cardiol 2018;86:53-54. [http:// dx.doi.org/10.7775/rac.86.i1.10873](http://dx.doi.org/10.7775/rac.86.i1.10873)

REFERENCES

- 2015 HRS/EHRA/APHS/SOLAECE expert consensus statement on optimal implantable cardioverter-defibrillator programming and testing. *Heart Rhythm* 2016;13.
- Shukla HH, Flaker GC, Jayam V, Roberts D. High defibrillation thresholds in transvenous biphasic implantable defibrillators: clinical predictors and prognostic implications. *Pacing Clin Electrophysiol* 2003;26:44-8.
- Nagai T, Kurita T, Satomi K, Noda T, Okamura H, Shimizu W, et al. QRS prolongation is associated with high defibrillation thresholds during cardioverter-defibrillator implantations in patients with hypertrophic cardiomyopathy. *Circ J* 2009;73:1028-32.
- Russo AM, Sauer W, Gerstenfeld EP, Hsia HH, Lin D, Cooper JM, et al. Defibrillation threshold testing: Is it really necessary at the time of implantable cardioverter-defibrillator insertion? *Heart Rhythm* 2005;2:456-61.
- Cesario D, Bhargava M, Valderrábano M, Fonarow GC, Wilkoff B, Shivkumar K. Azygos vein lead implantation: a novel adjunctive technique for implantable cardioverter defibrillator placement. *J Cardiovasc Electrophysiol* 2004;15:780-3.
- Cooper JA, Latacha MP, Soto GE, Garmany RG, Gleva MJ, Chen J, et al. The azygos defibrillator lead for elevated defibrillation thresholds: implant technique, lead stability, and patient series. *Pacing Clin Electrophysiol* 2008;31:1405-10.
- Gradaus R, Block M, Seidl K, Brunn J, Isgro F, Hammel D, et al. Defibrillation efficacy comparing a subcutaneous array electrode versus an "active can" implantable cardioverter defibrillator and a subcutaneous array electrode in addition to an "active can" implantable cardioverter defibrillator: Results from active can versus array trials I and II. *J Cardiovasc Electrophysiol* 2001;12:921-7.
- Verma A, Kaplan AJ, Sarak B, Oosthuizen R, Beardsall M, Higgenbottam J, et al. Incidence of very high defibrillation thresholds (DFT) and efficacy of subcutaneous (SQ) array insertion during implantable cardioverter defibrillator (ICD) implantation. *J Interv Card Electrophysiol*. 2010;29:127-33.

Pulmonary Artery Endarteritis in Patent Ductus Arteriosus

Pulmonary artery endarteritis is a rare disorder. Patent ductus arteriosus (PDA) is a known risk factor for pulmonary artery endarteritis, and occasionally, the endovascular infection may lead to the detection of a hitherto undetected silent PDA. We report an adult patient with pulmonary artery endarteritis secondary to silent PAD as underlying congenital heart defect.

A 21-year-old woman, with no relevant personal or family history of disease, visited the outpatient clinic due to palpitations, sharp chest pain, dry cough, chills and night sweats of two months duration. The patient was admitted to the internal medicine ward. She was lucid and afebrile, with normal blood pressure levels and respiratory rate, and normal oxygen saturation at ambient air. A grade 5/6 holosystolic ejection mur-

mur was heard in the pulmonic area and hypoventilation was detected at the left pulmonary base with few crepitant rales. Fundoscopy was normal. The chest X-ray showed opacification with air-bronchogram at the base of the left hemithorax. The laboratory tests revealed mild microcytic (MCV 74 fl) anemia (hematocrit 34%), mild leukocytosis (10,600/mm³), high erythrocyte sedimentation rate (46 mm in the first hour) and elevated quantitative CRP (25.7 mg/L). Doppler echocardiography showed the presence of PDA with left-to-right shunt between the descending aorta and the left pulmonary artery (PA) and a jet stream impacting over the main PA. A 15 mm-long multilobed mobile mass suggestive of vegetation was found on the wall of the main PA (Figure 1 A-C). Blood cultures were positive for *Streptococcus sanguinis* (a member of the viridans *Streptococcus* group) with intermediate susceptibility to penicillin and susceptible to cefotaxime. The diagnosis was mural pulmonary artery endocarditis associated with PDA and complicated by septic pulmonary embolism.

The patient evolved with fever and the chest x-ray showed consolidation at the base of the right lung which was interpreted as a new septic pulmonary embolism. A new Doppler echocardiogram detected two small masses in the anterior wall of the main PA which were considered residual vegetations (Figure 1 D). The patient was treated with ceftriaxone-gentamicin for 14 days and then with ceftriaxone alone until completing a six-week treatment, after which she was discharged with good favorable outcome.

Nine months later, the PDA was closed with an Amplatzer device at the catheterization laboratory of our institution.

Ductus arteriosus is a vascular structure connecting the junction of the main and left PA to the descending aorta just distal to the origin of the left subclavian artery. After birth, the duct closes functionally in 12 to 18 hours and anatomically in two to three weeks. If it remains open beyond 3 months of life in full-term infants and beyond 1 year in premature infants, it is termed persistent PDA because the incidence of spontaneous closure beyond these time limits is very low. (1) Patent ductus arteriosus seems to occur sporadically, accounts for 6% to 11% of all congenital heart defects and its incidence is approximately 0.02% to 0.05% in full-term infants. (1, 2) However, the incidence will be up to 0.2% (1 in 500), if the estimates of silent PDAs are included (see below). The female to male ratio is approximately 2:1. (1)

Patent ductus arteriosus is an uncommon clinical finding in adult primary care patients. (2) It may not be detected in childhood if the shunt volume is small and may come to be diagnosed for the first time in adults, (1) but this is the exception rather than the rule. (3) The magnitude of the defect and its physiological significance condition the clinical spectrum of PDA presentation, which may range from a "silent" or "clinically silent" PDA, which is incidentally dis-

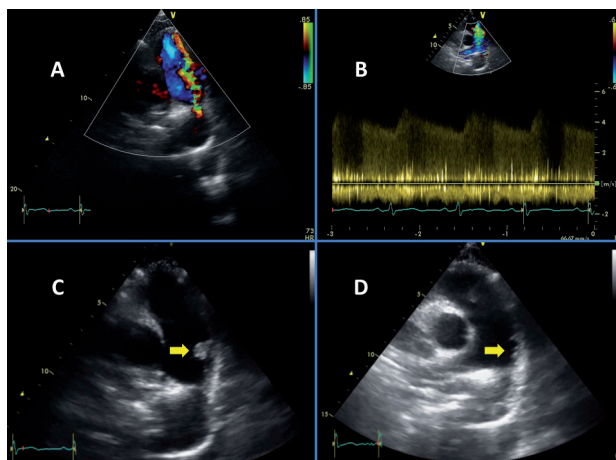


Fig. 1. A. Main pulmonary artery. Doppler color image shows blood flow corresponding to a patent ductus arteriosus coming from the left pulmonary artery. B. Spectral Doppler signal showing continuous flow through the patent ductus arteriosus. C. Main pulmonary artery. A 15 mm-long multilobed mobile vegetation is seen on the vessel wall in the area where the blood jet coming through the ductus is impacting (arrow). D. Echocardiography during antibiotic therapy. The size of the vegetation has dramatically decreased (arrow) as a result of detachment and subsequent pulmonary embolism.

covered on an echocardiogram for other purposes, to patients who present with congestive heart failure, pulmonary hypertension (PAH) and Eisenmenger syndrome, volume overload, infective endocarditis (IE), atrial fibrillation, or recurrent pneumonia. (2, 3)

The association between PDA and IE was described in the first half of the 20th century. Most investigators agree that it is a rare complication nowadays, with a declining incidence estimated in 0.14%-0.4% per year. (3) When IE complicates PDA, vegetations usually occur on the pulmonary artery end of the ductus, and embolic events are usually of the lung rather than the systemic circulation (4) Before the widespread use of antibiotic therapy and the introduction of Doppler echocardiography, IE was the most common cause of death in PDA patients, but over the past decades, mortality has decreased significantly due to early diagnosis and effective antibiotic therapy. (3)

The manifestation of IE in patients with silent PDA implies that the risk of endarteritis may be associated not only with the size of the defect but with turbulent flow and endothelial injury, which can predispose to the development of vegetations even in small PDAs, with diameters between 1.5 and 2.5 mm. (2) There are not many case reports of IE with silent PDA and it requires a high index of suspicion to detect a small and asymptomatic PDA in a patient with IE. (3)

In this case, the patient did not have symptoms during childhood and adolescence, and the diagnosis of the underlying congenital heart defect was made in the setting of the complication with pulmonary endarteritis in the absence of other predisposing situations or procedures. Even if the murmur was preexistent

but not detected, the patient did not present with clinical manifestations or echocardiographic abnormalities impacting on the hemodynamic behavior associated with PDA on admission.

As the natural history of small or silent PDAs has not been well characterized, (3) the indication of percutaneous closure to eliminate the risk of complications, especially PAH and IE, is controversial. (3, 5) Yet, percutaneous PDA closure after endarteritis is a class I indication due to the high risk of recurrence, despite the benefit of the intervention in secondary prevention has not been systematically evaluated and the recommendation has a level of evidence C. (4, 6, 7)

Percutaneous closure with an occluder device (Amplatzer Duct Occluder) or coils is the best option in adults, with a high rate of success (90-95%) and rare complications in the absence of other conditions requiring surgical repair. (4-6)

Antibiotic prophylaxis of IE is recommended in adult patients with cyanotic heart defects undergoing dental procedures (class IIa recommendation), (5, 7) but this conduct due to the risk of untreated shunts, such as PDA, is under review. Although the evidence favoring this recommendation is limited, antibiotic prophylaxis would not be indicated after successful PDA repair and absence of residual shunting. (6) Yet, it is recommended during the first six months after percutaneous or surgical closure until complete closure is documented, (1, 7) or lifelong in case of residual defect. (4)

Patent ductus arteriosus is an uncommon finding in adults. In undetected cases, pulmonary endarteritis is a potential and serious complication with favorable outcome if the diagnosis is rapidly made and the appropriate treatment is indicated. Percutaneous closure can be performed at a later stage to prevent recurrence, has minimal complications and PDA closure is achieved in most cases.

Conflicts of interest

None declared.

(See authors' conflicts of interest forms on the web/Supplementary material).

REFERENCES

1. Anilkumar M. Patent ductus arteriosus. *Cardiol Clin.* 2013;31:417-30. <http://doi.org/f49j78>
2. Cassidy HD, Cassidy LA, Blackshear JL. Incidental discovery of a patent ductus arteriosus in adults. *J Am Board Fam Med* 2009;22:214-8. <http://doi.org/fr9s66>
3. Fortescue EB, Lock JE, Galvin T, McElhinney DB. To close or not to close: the very small patent ductus arteriosus. *Congenit Heart Dis* 2010;5:354-65. <http://doi.org/d3z3cr>
4. Schneider DJ and Moore JW. Patent Ductus Arteriosus. *Circulation* 2006;114:1873-82. <http://doi.org/fpc98q>
5. Warnes CA, Williams RG, Bashore TM, Child JS, Connolly HM, Dearani JA, et al. ACC/AHA 2008 guidelines for the management of adults with congenital heart disease: a report of the American College of Cardiology/American Heart Association Task Force on Practice Guideline. *J Am Coll Cardiol.* 2008;52:e143-263. <http://doi.org/dmcg7q>
6. Baruteau AE, Hascoët S, Baruteau J, Boudjemline Y, Lambert V, Angel CY, et al. Transcatheter closure of patent ductus arteriosus: past, present and future. *Arch Cardiovasc Dis* 2014;107:122-32. <http://doi.org/f5xz4b>
7. Habib G, Lancellotti P, Antunes MJ, Bongiorni MG, Casalta JP, Del Zotti F, et al. 2015 ESC Guidelines for the management of infective endocarditis: The Task Force for the Management of Infective Endocarditis of the European Society of Cardiology (ESC). *Eur Heart J* 2015;36:3075-128. <http://doi.org/b472>

**Marina Quarleri¹, César Sánchez¹,
Natalia Maddalena¹, Marina Penalba¹,
Cecilia Garbarino, Luis Morita²**

¹ Department of Internal Medicine,
Hospital General de Agudos "Dr. Cosme Argerich".

² Department of Cardiology,
Hospital General de Agudos "Dr. Cosme Argerich".

Phone: (011) 15-5109-1956
e-mail: marina_quarleri@yahoo.com.ar