

Looking for Perfection in the Evaluation of Mitral Regurgitation

Buscando la perfección en la evaluación de la insuficiencia mitral

MARTA L. NACKE¹, JORGE I. PARRAS², FRANCISCO G. FAZIO¹, ENRIQUE M. ASSAF¹

ABSTRACT

Background: Currently, there is no single echocardiographic parameter for assessing the severity of mitral regurgitation. Two conceptually similar methods have been published. One method is the mitral valve to LVOT velocity time integral ratio (MOTVTI), and the other the mitral E wave peak velocity to LVOT velocity time integral ratio (EVTI).

Objectives: Our goals were to compare the ability of both methods to diagnose severe mitral regurgitation and establish the best cutoff points for the diagnosis.

Methods: We included patients with and without mitral regurgitation. The area under the ROC curve for MOTVTI and EVTI was analyzed to compare their diagnostic ability and estimate the best diagnostic cutoff points.

Results: A total of 135 patients were included in the study, 51 with various degrees of mitral regurgitation and the rest as controls. Patients with severe mitral regurgitation had an effective regurgitant orifice area of 0.73 ± 0.34 cm², vena contracta of 8.3 ± 2.2 mm and regurgitant volume of 99 ± 42 ml. The analysis showed an area under ROC curve of 0.83 (95% CI: 0.75 to 0.89) for MOTVTI and 0.92 (95% CI: 0.86 to 0.96) for EVTI, without significant differences. The best cutoff point was > 1.84 for MOTVTI (sensitivity 80%, specificity 94%) and > 6.25 for EVTI (sensitivity 100%, specificity 79%).

Conclusions: Both methods are useful for the diagnosis of severe MR and have similar diagnostic capacity. The best cutoff points differ from those originally published.

Key words: Heart Failure - Echocardiography - Diagnostic.

RESUMEN

Introducción: Actualmente no existe un único parámetro ecocardiográfico para la evaluación de la gravedad de la insuficiencia mitral (IM). Dos métodos conceptualmente similares han sido publicados. Uno relaciona la integral velocidad/tiempo (IVT) mitral con la del tracto de salida del ventrículo izquierdo (MOTIVT), y el otro divide la velocidad pico de la onda E por el IVT del tracto de salida del ventrículo izquierdo (EIVT).

Objetivos: Nuestros objetivos fueron comparar la capacidad para diagnosticar IM grave de ambos métodos y establecer los mejores puntos de corte para dicho diagnóstico.

Materiales y Métodos: Incluimos pacientes con y sin IM. Se analizó el MOTIVT y el EIVT y se realizó un análisis del área bajo la curva ROC para comparar la capacidad diagnóstica de ambos y estimar los mejores puntos de corte diagnósticos.

Resultados: Incluimos 135 pacientes, 51 con distintos grados de IM y el resto controles. Los pacientes con IM grave tuvieron un orificio regurgitante de 0.73 cm² (DS 0.34), vena contracta de 8.3 mm (DS 2.2) y volumen regurgitante de 99 ml (DS 42). El análisis mostró un área bajo la curva ROC de 0.83 (IC 95% 0.75 a 0.89) para MOTIVT y 0.92 (IC 95% 0.86 a 0.96) para EIVT, sin diferencias significativas entre ambos. El mejor punto de corte fue > 1.84 para MOTIVT (sensibilidad 80%, especificidad 94%) y > 6.25 para EIVT (sensibilidad 100%, especificidad 79%).

Conclusiones: Ambos métodos son útiles para diagnosticar IM grave y tienen similar capacidad diagnóstica. Los mejores puntos de corte difieren de los publicados originalmente.

Palabras claves: insuficiencia mitral - Ecocardiografía - Diagnóstico.

Abbreviations

EROA	Effective regurgitant orifice area	MR	Mitral regurgitation
EVTI	Mitral E wave velocity to left ventricular outflow tract velocity time integral ratio	RF	Regurgitant fraction
LVOT	Left ventricular outflow tract	RV	Regurgitant volume
MOTVTI	Mitral valve to left ventricular outflow tract velocity time integral ratio	VC	Vena contracta
		VTI	Velocity time integral

REV ARGENT CARDIOL 2017;85:511-515. <http://dx.doi.org/10.7775/rac.v85.i6.12553>

Received: xx/xx/2017 - Accepted: 7/8/2017

Address for reprints: Dra. Marta L. Nacke - E-mail: luciananacke@gmail.com

¹ Staff Cardiologist. Division of Echocardiography. Hospital Escuela de Agudos Dr. Ramón Madariaga

² Staff Cardiologist. Division of Echocardiography. Instituto de Cardiología de Corrientes Juan F. Cabral

INTRODUCTION

Mitral regurgitation (MR) is an increasingly prevalent disease worldwide, despite the decreased incidence of rheumatic disease. (1) This implies greater responsibility at the time of establishing the severity of MR by echocardiography.

Despite echocardiography is the recommended diagnostic method to assess MR, there is currently no unique echocardiographic parameter to estimate its severity (either organic or functional). However, in all cases, a careful analysis of MR severity is necessary to determine the therapeutic conduct.

Guidelines suggest an integrative approach of the multiple parameters described to assess MR. (2-4) The most usual methods are quantitative [effective regurgitant orifice area (EROA), regurgitant volume (RV), regurgitant fraction (RF) and vena contracta (VC)], qualitative (jet area, jet density and jet contour), and volumetric [mitral flowgram, mitral/aortic velocity time integral (VTI) and pulmonary vein flowgram].

Two conceptually similar methods have been published based on the typically increased E wave velocity due to regurgitant volume in the mitral flowgram of patients with severe MR.

Tribouilloy et al. (5) described the mitral valve VTI to left ventricular outflow tract (LVOT) VTI ratio (MOTVTI), indicating that a value > 1.3 identifies severe MR.

Moreover, Lee et al (6) have recently simplified this method establishing the mitral E wave velocity to LVOT VTI ratio (EVTI), and concluded that a value ≥ 8 was associated with severe MR.

However, as no sensitivity or specificity values have been reported, the reason for associating these cutoff points is still not clear and also, the diagnostic capabilities of both methods have not been compared.

Thus, the aim of this study was twofold: to compare the diagnostic ability of these two echocardiographic methods to assess the severity of MR and to determine their best diagnostic cutoff point.

METHODS

Study population

Inclusion criteria

- Hospitalized or ambulatory patients with echocardiographic diagnosis of any degree of severity primary or secondary MR, treated at Instituto de Cardiología de Corrientes Juana F. Cabral and Hospital Escuela de Agudos Dr. Ramón Madariaga between October 2015 and April 2016.
- Patients without MR (control group).

Exclusion criteria

- Patients presenting a concomitant left heart valve disease, classified as major or mild, those with valve prostheses, congenital heart diseases, mitral valve repair or mitral devices (such as mitral clip) and dynamic obstruction of the LVOT.

Study protocol

This was a prospective, observational, multicenter study,

evaluating the severity of MR according to the European Association of Cardiovascular Imaging recommendations. (2)

Classical variables were analyzed for the diagnosis of MR, as well as the relationship between MOTVTI and EVTI (Figures 1 and 2).

Mitral regurgitation was classified as severe with effective regurgitant orifice area (EROA) ≥ 0.4 cm² (0.2 cm² for ischemic valves), regurgitant volume (RV) ≥ 60 ml (30 ml for ischemic valves) and vena contracta (VC) width ≥ 7 mm.

Vena contracta assessment as well as the necessary measurements for the proximal isovelocity surface area (PISA) method were performed in 4 chamber view.

Statistical analysis

A Microsoft Excel 2013 database was built including patient information (clinical characteristics, risk factors and echocardiographic data).

The population was divided into four groups according to the presence or absence and severity (mild, moderate, severe) of MR, and echocardiographic data were compared.

Qualitative variables were expressed in percentages and compared with the chi-square test, while quantitative variables were expressed as mean and standard deviation (SD) and analyzed with Student's t test or non-parametric tests, as appropriate.

Sensitivity and specificity values were calculated for each method and the area under the ROC curve was analyzed comparing the diagnostic ability of the methods and to estimate the best cutoff point.

A p value < 0.05 was considered statistically significant.

Ethical considerations

The study was evaluated and approved by the Ethics Committee of both institutions.

RESULTS

Baseline characteristics

A total of 135 patients were included in the study, 51 with various degrees of MR and the rest as controls. Mild MR was diagnosed in 29 (56.8%) patients, moderate in 12 (23.5%) and severe in 10 (19.7%). Mean age

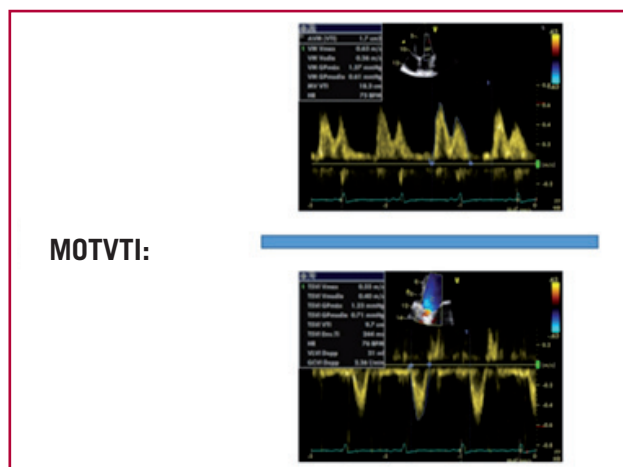


Fig. 1. MOTVTI: Relationship between mitral valve velocity time integral and left ventricular outflow tract volume time integral.

was 57 ± 17 years and 58% were men. Baseline characteristics are detailed in Table 1.

Echocardiographic data

Prolapse was the cause for MR in 26% of cases and in the rest it was secondary to ventricular dilatation or ischemia. Mean ejection fraction was $55 \pm 15\%$.

The E wave of the mitral flowgram increased proportionally to the increased severity of MR, same as the mitral VTI. Patients with severe MR had mean EROA of 0.73 ± 0.34 cm², VC of 8.3 ± 2.2 mm and RV of 98 ± 42 ml. Echocardiographic data are summarized in Table 2.

The area under the ROC curve was 0.83 (95% CI 0.75-0.89) for MOTVTI and 0.92 (95% CI 0.86-0.96) for EVTI, with no significant differences between

both methods ($p=0.19$) (Figure 3)

The best cutoff point was >1.84 for MOTVTI (sensitivity 80%, specificity 94%) and >6.25 for EVTI (sensitivity 100%, specificity 79%).

DISCUSSION

The results of this study show that EVTI is another echocardiographic parameter in addition to those described in the guidelines, which can be used to diagnose MR with good sensitivity and specificity.

Despite multiple parameters for MR have been evaluated for decades (1-4, 7, 8), there is no “gold standard” method. Moreover, their diagnostic capacity may be influenced by various characteristics such as jet direction (principally when it is eccentric), presence of multiple regurgitant jets, regurgitant orifice geometry, image quality and ultrasound machine configuration adjustments (color gain, pulse repetition frequency, Nyquist limit, depth for image acquisition), (9-11) making it necessary to find a reliable, reproducible and simple method to evaluate a patient with MR.

Color Doppler has its limitations. It can be misleading in acute severe regurgitations, evidencing apparently small jets due to limited atrial compliance.

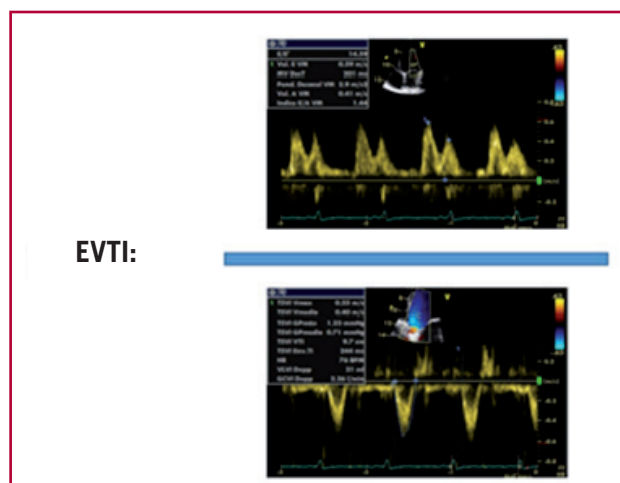

Fig. 2. EVTI: Relationship between the mitral flowgram E wave velocity and the left ventricular outflow tract velocity time integral.

Table 1. Baseline patient characteristics

	With MR	Controls	p
N° of patients	51	84	
Age, years	62±16	53±17	0.005
Female gender (%)	55	61	0.5
Hypertension (%)	67	49	0.043
Dyslipidemia (%)	25	37	0.17
Smoking (%)	18	45	0.01
Diabetes (%)	12	18	0.34

Table 2. Patient echocardiographic characteristics

Variable	Controls (n=84)	Mild MR (n=29)	Moderate MR (n=12)	Severe MR (n=10)	p
FC, median	I	II	II	II	0.0001
LVDD, mm	49±5	58±10	59±9	60±8	0.0001
% EF	62±9	41±16	41±19	60±14	0.0001
LAVI, ml	29±11	46±18	48±15	63±19	0.0001
E wave vel., cm/s	74±22	91±25	100±23	157±30	0.0001
LVOT VTI, cm	18±4	15±6	20±19	16±4	0.077
Mitral VTI cm	20±5	21±7	35±45	36±14	0.0001
EVTI	4±1.6	6.8±3	6.5±2.6	9±2.4	0.0001
MOTVTI	1±0.29	1.5±0.39	1.6±0.37	2.2±0.99	0.0001
EROA, cm ²	.	0.1±0.04	0.3±0.1	0.7±0.3	0.0001
RV, ml	.	15±7	44±23	98±42	0.0001
VC, mm	.	3.3±1	4.9±1.8	8.3±2.2	0.0001

FC: Functional class. LVDD: Left ventricular diastolic diameter. EF: Ejection fraction. LAVI: Left atrial volume index. E wave vel.: Mitral flowgram E wave velocity. LVOT: Left ventricular outflow tract. VTI: Velocity time integral. EVTI: E wave/ left ventricular outflow tract velocity time integral. MOTVTI: mitral/left ventricular outflow tract velocity time integral. EROA: Effective regurgitant orifice area. RV: Regurgitant volume. VC: vena contracta. Values are expressed as mean±standard deviation.

Moreover, eccentric jets impacting on the left atrial wall seem significantly smaller than central jets of equal hemodynamic severity (due to jet flattening against the atrial wall). (12) Also, in the case of vena contracta, it is not always possible to obtain an adequate image of the narrowest jet zone and it can also change its value in irregular or multiple regurgitant orifices. (13)

When PISA parameters are measured, low hemisphere values (generally <1 cm) turn small measurement errors into large errors in the percent severity of MR (since any measurement error is raised to the power of 2). In addition, the measurement is not precise when the regurgitant orifice is not circular or there are eccentric jets. (14, 15)

Regarding pulsed Doppler, volumetric parameters have been studied and validated based on flow through the regurgitant mitral valve compared with flow through the LVOT. (8, 16) However, it also presents limitations, as its irregular shape makes it difficult to estimate the mitral orifice area with a simple linear measurement, and in addition, the tracing of both VTIs implies more time for the operator.

Conversely, the evaluation of MR has been described using the mitral flowgram E wave peak velocity, (17) yielding a sensitivity of 85% and specificity of 86%, but with a positive predictive value of 75%, which rules out its use as unique assessment method.

For these reasons, Lee et al. (6) developed a reliable and simple new alternative to the volumetric parameter to evaluate the severity of MR. This method is based in the ratio between the E wave velocity measured in the mitral flowgram (classically increased in these patients and an estimator of stroke volume (VTI from LVOT).

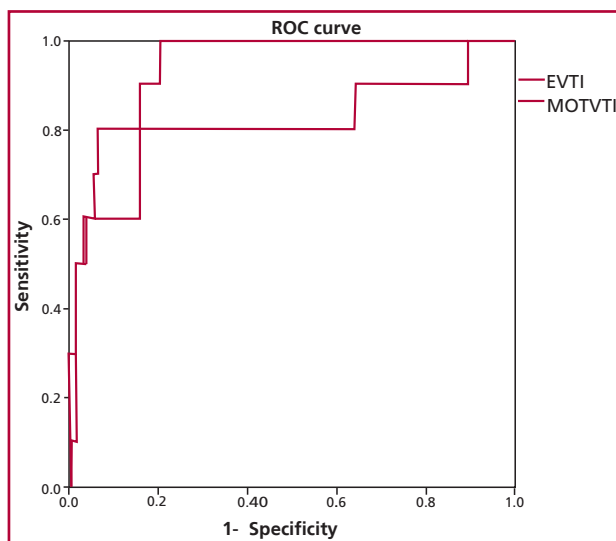


Fig. 3. Area under the ROC curve for both methods of severe regurgitation diagnosis. EVTI: E wave/left ventricular outflow tract velocity time integral. MOTVTI: mitral /left ventricular outflow tract velocity time integral.

Many studies have assessed classical parameters of MR evaluation, but the diagnostic ability of this new method has not been evaluated. In addition, its specificity and sensitivity has not been described prospectively.

In our work, this method was compared with the non-geometric method comparing the diastolic volume passing through the mitral valve with the left ventricular stroke volume (estimated by their corresponding VTIs).

We found that both methods are reliable parameters with sensitivity and specificity for the diagnosis of MR severity, and thus consider that they should be incorporated to the diagnostic algorithm of MR.

As both MOTVTI and EVTI indices increase, there is evidence of increasing severity of the echocardiographic parameters of MR (increased ventricular dimension, left atrial volume index, EROA, RV and VC), indicating a good correlation of the method with classical parameters.

Furthermore, this method is essentially useful in situations in which other methods fail, as with multiple regurgitant jets, irregular regurgitant orifices or in the presence of eccentric jets.

Its greater simplicity and shorter time involved in its acquisition is an additional attraction of VTI.

Cutoff points of the new index

The cutoff points for the diagnosis of severe MR in our study differ from those previously published.

In their original study, Tribouilloy et al (5) established the importance of MOTVTI for the echocardiographic diagnosis of MR. However, several aspects must be considered. A cutoff point ≥ 1.3 [or ≥ 1.4 as established in the European Association of Cardiovascular Imaging recommendations (2)] to identify patients with severe MR was derived from data where invasive angiography was the gold standard. Our study was strictly based on current recommendations for the echocardiographic diagnosis. The discordance of regurgitation severity may partially explain the difference between cutoff points.

Moreover, controls (without MR) in the Tribouilloy study had a mean MOTVTI ratio of 0.79 and in our study this was close to 1. In healthy persons, the normal mitral valve area is greater than the aortic valve area, so a lower mitral VTI compared with that of the LVOT is expected. However, most of our control patients had evidence of ventricular remodeling (especially due to hypertensive heart disease) with an average relative wall thickness of 0.46. Therefore, potential geometric abnormalities in the mitral annulus, the increased importance of atrial contraction and the increase in atrial volume may be some of the factors that explain this difference. Nonetheless, the higher MOTVTI value in our control patients is in agreement with an equally higher cutoff point for severe MR.

The study design of Lee et al. (6) is similar to the

one of the present study, although their study was retrospective, involving for reanalysis only cases classified as moderate or severe MR. In addition, patients without MR and those with mild MR were grouped together for the analysis. Similarly, there was a category of patients with moderate to severe MR. Conversely, our design was prospective and specifically directed to evaluate the different echocardiographic indicators of MR measured. These factors may explain the small differences in the area under the ROC curve and the cutoff point.

Limitations

The number of patients with severe MR was relatively small, so the different etiologies may not be sufficiently represented.

A comparison with other imaging methods, as magnetic resonance imaging, which could have better classified MR, was not performed.

The conclusions of the study can only be applied to patients with similar characteristics to those included in our investigation.

CONCLUSIONS

Both methods are useful for the diagnosis of severe MR and have similar diagnostic capacity. EVTI should be included with traditionally used methods of MR reclassification. The best cutoff points differ from originally published ones.

Conflicts of interests

None declared.

(See authors' conflicts of interest forms on the web/Supplementary material).

REFERENCES

- Vahanian A, Baumgartner H, Bax J, Butchart E, Dion R, Filippatos G et al. Guidelines on the management of valvular heart disease: the task force on the management of valvular heart disease of the European Society of Cardiology. *Eur Heart J* 2007;28:230-68. <http://doi.org/bk28>
- Lancellotti P, Tribouilloy C, Hagendorff A, Popescu BA, Edvardsson T, Pierard LA et al. Recommendations for the echocardiographic assessment of native valvular regurgitation: an executive summary from the European Association of Cardiovascular Imaging. *Eur Heart J Cardiovasc Imaging* 2013;14:611-44. <http://doi.org/bvj6vj>
- Zoghbi WA, Enriquez-Sarano M, Foster E, Grayburn PA, Kraft CD, Levine RA, et al. Recommendations for Evaluation of the Severity of Native Valvular Regurgitation with two-dimensional and Doppler Echocardiography. *J Am Soc Echocardiogr* 2013;16:777-802. <http://doi.org/bvj6vj>
- Lancellotti P, Moura L, Pierard LA, Agricola E, Popescu BA, Tribouilloy C et al. European Association of Echocardiography recommendation for the assessment of valvular regurgitation. Part 2: mitral and tricuspid regurgitation (native valve disease). *Eur J Echocardiogr* 2010;11:307-32. <http://doi.org/cfcq23>
- Tribouilloy C, Shen WF, Rey JL, Adam MC, Lesbre JP. Mitral to aortic velocity-time integral ratio. A non-geometric pulsed-Doppler regurgitant index in isolated pure mitral regurgitation. *Eur Heart J* 1994;15:1335-9. <http://doi.org/cfcq23>
- Lee MM, Salahuddin A, Garcia MJ, Spevack DM. Left Ventricular Early Inflow-Outflow Index: A Novel Echocardiographic Indicator of Mitral Regurgitation Severity. *J Am Heart Assoc* 2015; 4(6):e000781. <http://doi.org/cmcp>
- Enriquez-Sarano M, Bailey K, Seward J, Tajik A, Krohn M, Mays J. Quantitative Doppler assessment of valvular regurgitation. *Circulation* 1993;87:841-8. <http://doi.org/q3w>
- Rokey R, Sterling L, Zoghbi W, Sartori M, Limacher M, Kuo L, et al. Determination of regurgitant fraction in isolated mitral or aortic regurgitation by pulsed Doppler two-dimensional echocardiography. *J Am Coll Cardiol* 1986;7: 1273-8. <http://doi.org/fvjknw>
- Enriquez-Sarano M, Tajik A, Bailey K, Seward J. Color flow imaging compared with quantitative Doppler assessment of severity of mitral regurgitation: influence of eccentricity of jet and mechanism of regurgitation. *J Am Coll Cardiol* 1993;21: 1211-9. <http://doi.org/cvpj4f>
- Grayburn P, Bhella P. Grading severity of mitral regurgitation by echocardiography: science of art? *JACC Cardiovasc Imaging* 2010;3 244-6. <http://doi.org/dx3rsg>
- Sahn DJ. Instrumentation and physical factors related to visualization of stenotic and regurgitant jets by Doppler color flow mapping. *J Am Coll Cardiol*. 1988;12:1354-65. <http://doi.org/c654sr>
- Chen C, Thomas JD, Anconina J, Harrigan P, Mueller L, Picard MH, Levine RA, Weyman A. Impact of impinging wall jet on color Doppler quantification of mitral regurgitation. *Circulation* 1991;84:712-20. <http://doi.org/cmcp>
- Hall S, Brickner M, Willett D, Irani W, Afridi I, Grayburn P. Assessment of mitral regurgitant severity by Doppler color flow mapping of the vena contracta. *Circulation* 1997;95:636-42. <http://doi.org/cmcr>
- Rodriguez L, Anconina J, Flachskampf F, Weyman A, Levine R, Thomas J. Impact of finite orifice on proximal flow convergence: implications for Doppler quantification of valvular regurgitation. *Circ Res* 1992;70:923-30. <http://doi.org/cmcs>
- Pu M, Vandervoort P, Griffin B, Leung D, Stewart W, Cosgrove D, Thomas J. Quantification of mitral regurgitation by the proximal convergence method using transesophageal echocardiography: clinical validation of a geometric correction for proximal flow constraint. *Circulation* 1995;92:2169-77. <http://doi.org/cmct>
- Asch K, Stewart W, Jiang L, Guerrero J, Newell J, Gillam L, Weyman A. A Doppler two dimensional echocardiographic method for quantitation of mitral regurgitation. *Circulation* 1985;72:377-83. <http://doi.org/b3vvpq>
- Thomas L, Foster E, Schiller N. Peak Mitral Inflow Velocity Predicts Mitral Regurgitation Severity. *J Am Coll Cardiol* 1998; 31:174-9. <http://doi.org/fnh2n4>