

## Caso clínico

# Aesthetic rehabilitation with strip crowns in Pediatric Dentistry: a case report

## *Reabilitação estética com coroas de acetato em Odontopediatria: relato de caso*

Mónica Irma Aparecida Valdeci de Souza<sup>1</sup>✉, Jéssica Patrícia Cavalheiro<sup>1</sup>✉, Diego Giroto Bussaneli<sup>2</sup>✉ CvLAC, Fabiano Jeremias<sup>3</sup>✉, Ângela Cristina Cilense Zuanon<sup>3</sup>✉

1. PhD student. Department of Orthodontics and Pediatric Dentistry, Araraquara Dental School, Univ Estadual Paulista-UNESP, Araraquara/SP, Brazil.

2. Postdoctoral scholar Department of Morphology, Araraquara Dental School, Univ Estadual Paulista-UNESP, Araraquara/SP, Brazil.

3. Professor. Department of Orthodontics and Pediatric Dentistry, Araraquara Dental School, Univ Estadual Paulista-UNESP, Araraquara/SP, Brazil.

### Fecha correspondencia:

Recibido: octubre de 2017.

Aceptado: diciembre de 2018.

### Forma de citar:

Souza MIAV, Cavalheiro JP, Bussaneli DG, Jeremias F, Zuanon ACC. Aesthetic rehabilitation with strip crowns in Pediatric Dentistry: a case report Rev. CES Odont 2018; 31(2): 66-75.

### Open access

© Derecho de autor

Licencia creative commons

Ética de publicaciones

Revisión por pares

Gestión por Open Journal System

DOI: <http://dx.doi.org/10.21615/cesodon.31.2.7>

ISSN 0120-971X

e-ISSN 2215-9185

### Abstract

Even with all the preventive measures used in pediatric dentistry, early childhood caries is a problem faced daily in pediatric dentistry, and mainly affects the vestibular surface of the anterior teeth in children younger than 71 months.

The present study reports a case of aesthetic-functional rehabilitation performed with the help of laboratory-made strip crowns and composite in a 5-year-old patient affected by multiple lesions of early childhood caries. Composite resin restorations were performed on all upper anterior teeth to restore aesthetics and function, offering a better quality of life for the child and her family. The preparation of composite resin crowns with the help of strip crowns resulted in a shorter clinical time, a better aesthetic result and the restoration of the patient's smile and self-esteem.

**Keywords:** Mouth rehabilitation; Pediatric dentistry; Dental caries.

### Resumen

A pesar de todas las medidas preventivas utilizadas en odontología pediátrica, caries de la primera infancia es un problema que enfrentan todos los días en la odontología pediátrica, y sobre todo afecta a la cara vestibular de los dientes anteriores en niños menores de 71 meses. El presente estudio reporta un caso de rehabilitación estético-funcional realizado con la ayuda de coronas de acetato hechas en laboratorio y resina compuesta en un paciente de 5 años de edad afectado por múltiples lesiones de caries en la primera infancia. Se realizaron restauraciones de resina compuesta en todos los dientes anteriores superiores para restaurar la estética y la función, ofreciendo una mejor calidad de vida para el niño y su familia. La preparación de coronas de resina compuesta con la ayuda de coronas de tiras dio como resultado un tiempo clínico más corto, un mejor resultado estético y la restauración de la sonrisa y la autoestima del paciente.

**Palabras clave:** Rehabilitación bucal; Odontología; Caries dental.

## Resumo

Mesmo com todas as medidas preventivas utilizadas em odontopediatria, a cárie precoce da infância, consiste um problema enfrentado diariamente pelo Odontopediatra, e acomete principalmente a superfície vestibular de dentes anteriores em crianças menores de 71 meses. Este estudo relata um caso de reabilitação estética-funcional em uma paciente de 5 anos de idade. Foram realizadas restaurações de resina composta em todos os dentes superiores anteriores para restabelecimento da estética e função, oferecendo melhor qualidade de vida a criança e seu núcleo familiar. Com a confecção de coroas de resina composta conseguiu-se menor tempo clínico, bom resultado estético e o restabelecimento do sorriso e auto-estima da paciente.

**Palavras chave:** Reabilitação bucal; Odontopediatria; Cárie dentária

## Introduction

Early childhood caries is defined as the presence of caries lesion in one or more teeth in children less than 71 months of age (1), and the vestibular surface of the upper anterior teeth is one of the most commonly affected (2). As a consequence, pain, aesthetic problems, phonation, swallowing and even loss of anterior space can be found (1). Even with the numerous achievements for oral health promotion, caries disease is still considered a public health problem (3).

When the upper anterior deciduous teeth are affected by carious lesions, different treatment options can be used such as faceted steel crowns, polycarbonate crowns, composite resin (4-6), among others. Grosso et al., 1987 (7) described the strip crown technique for the preparation of composite resin cores, which is fast-performing and provides satisfactory aesthetic results.

The color, shape and texture of the teeth surface are essential for a beautiful smile (8) since children also have aesthetic perception of their teeth (9,10). In addition, there are the functional implications that decayed or absent teeth bring to the child, such as pain, difficulty speaking and swallowing (11).

The reduction of clinical time in pediatric dentistry is important, especially in more complex situations, which require longer working time and minimal patient collaboration. Thus, in cases of aesthetic reconstructions for restoration of highly destroyed dental crowns, the use of the strip crowns is an interesting alternative because it allows coverage of most of the remaining structure prepared, promotes a satisfactory aesthetic result, requires little operative time, is easy to execute and low cost.

## Objective

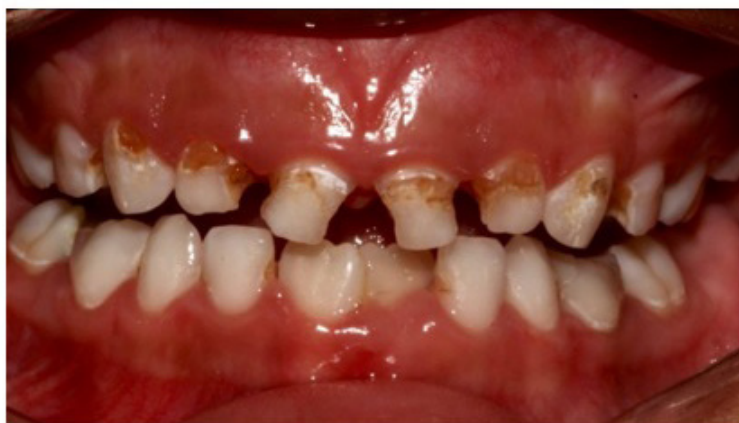The present report aims to present a clinical case of anterior aesthetic rehabilitation of deciduous teeth using composite resin using a strip crown made from the waxing of the plaster model.

## Clinical Considerations

A 5-year-old female patient, Y.A.G., attended the Pediatric Dentistry Clinic of the Araraquara Dental School-UNESP, accompanied by her mother who signed a Free and Informed Consent term prior to the clinical examination. The main complaint was related to the presence of dental caries in the upper anterior teeth, which were a cause for *bullying* in school.

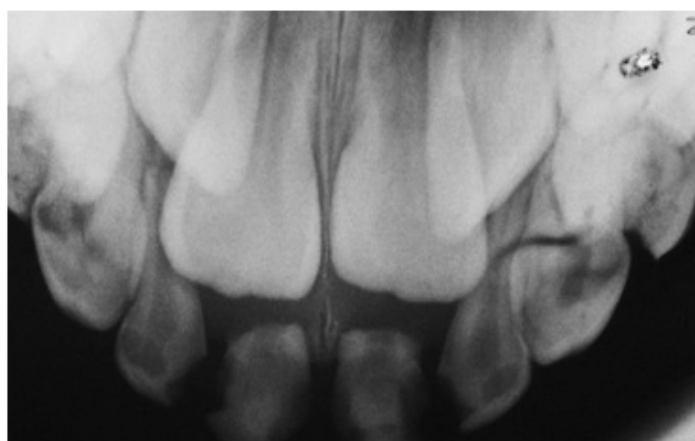
During the anamnesis, the frequent ingestion of sugary foods by the child and the hygiene of the teeth performed twice daily by the mother were reported. The patient's systemic health can be observed within the normal range.

Clinical examination revealed the presence of carious lesions on the teeth 51,52,53,61,62 and 63, besides those present on the posterior teeth (Figure 1a).



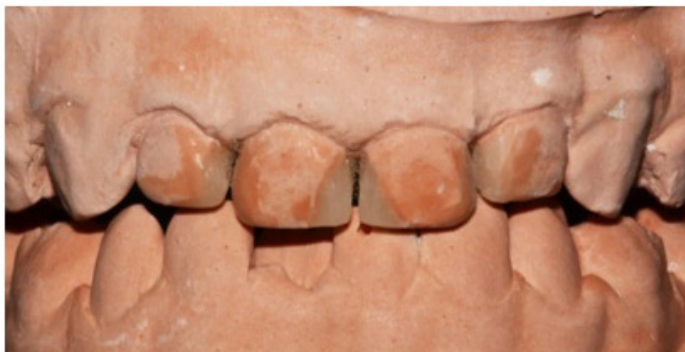**Figure 1a.** Initial clinical examination: diagnosis of caries lesions the anterior and posterior teeth in the upper and lower arches.

Radiographic examination of anterior teeth showed that caries lesions were located in the middle third of the dentin (Figure 1b). Thus, the use of strip crowns and direct restoration with composite resin was chosen, since, after removal of the carious tissue, the dental remnant was sufficient to perform this technique.



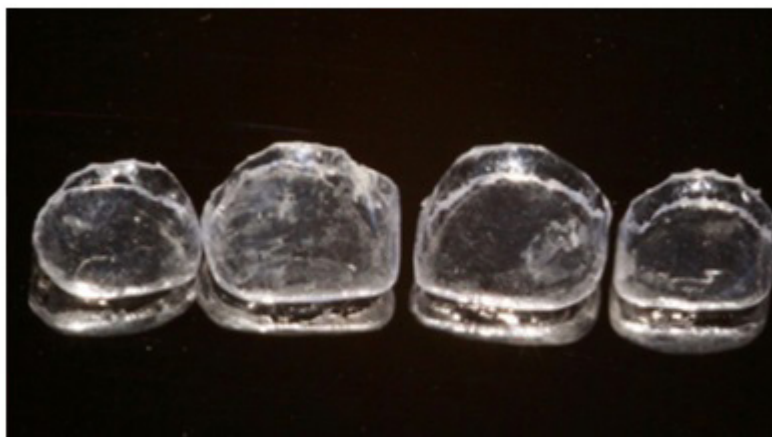
**Figure 1b.** Initial radiography: diagnosis of caries lesions in the anterior and posterior teeth in the upper and lower arches. Advanced degree of rhizolysis of teeth 51 and 61.

Initially, the upper and lower arches were molded with alginate (Avagel-Dentsply) to prepare a working model, where the teeth 51, 52, 61 and 62 were waxed (Figure 1 c) and soon after, molding with silicone condensation (Zetaplus, Zhermack).

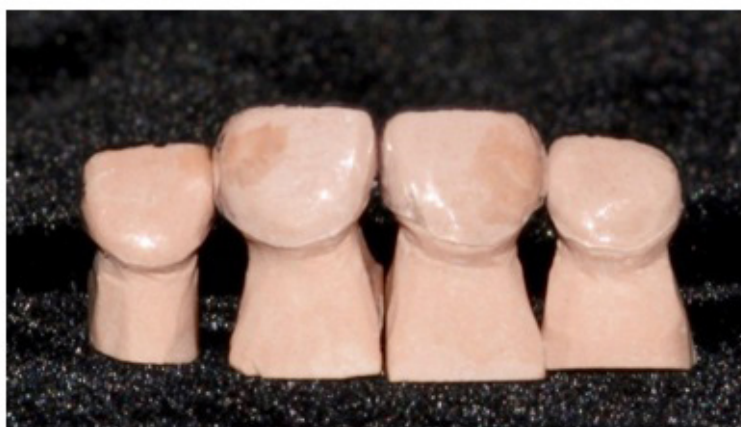

**Figure 1c:** Top and bottom models with tooth waxing of teeth 51, 52, 61 and 62.

The mold was cast with type IV gypsum plaster and in the respective model, the matrices were made (figure 1d), which were taken to a vacuum plasticizer (Protéctni) with an acetate plate attached to it to make the respective crowns (Figure 2a).

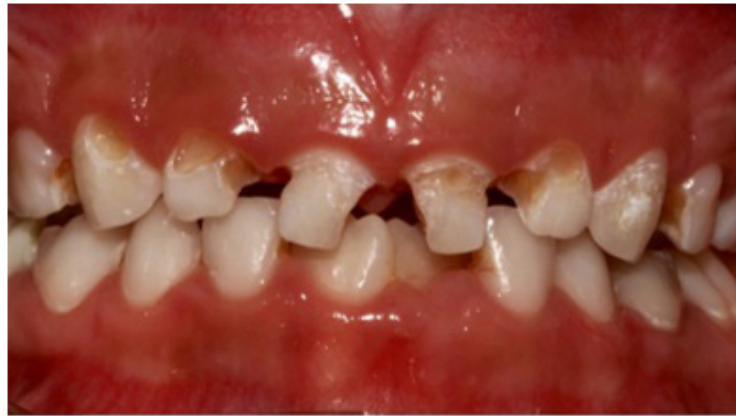

**Figure 1d:** Tooth acetate matrices of teeth 51, 52, 61 and 62



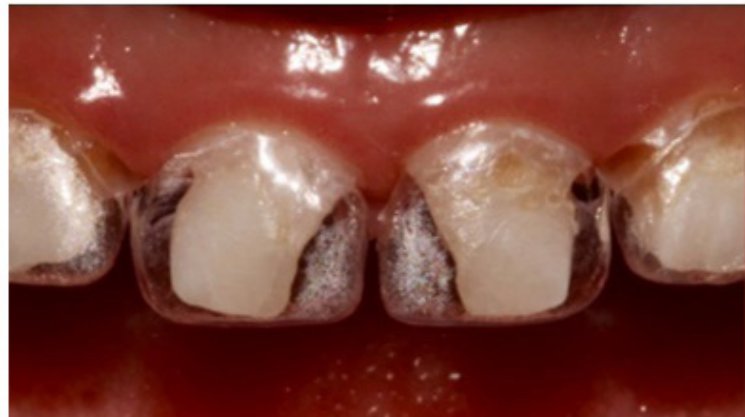**Figure 2a:** Troches to make the acetate matrices of teeth 51, 52, 61 and 62

Removal of the carious tissue was performed with spherical cutters numbers 4 and 6 (KG Sorensen) at low rotation under relative isolation of the operative field (Figure 2b).



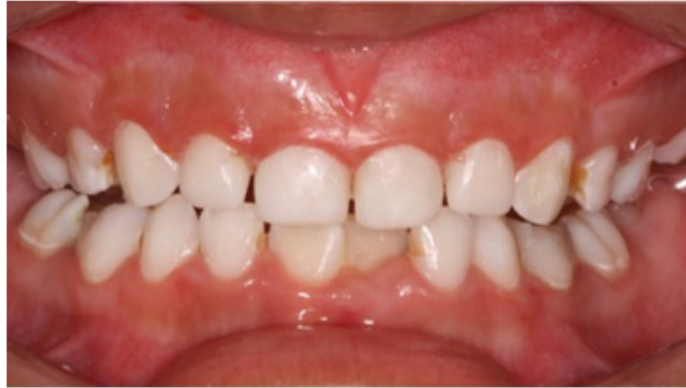**Figure 2b:** Clinical appearance of teeth 51, 52, 61 and 63 after removal of carious tissue

The strip crowns were placed on the dental remnants in order to verify their correct adaptation (Figure 2c). Subsequently, conditioning was performed with 35% phosphoric acid (Ultra Etch-Utradent) for 15 seconds in the dentin and 30 seconds in the enamel and delicate drying with the aid of absorbent paper. The adhesive system used was the Adper Scotchbond (3M ESPE) applied according to the manufacturer's recommendations.



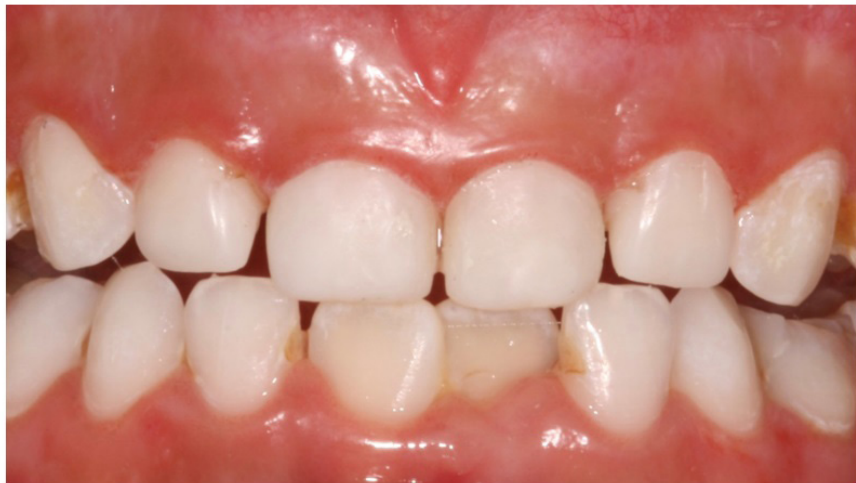**Figure 2c:** Adaptation of acetate crowns

Soon after, the strip crowns were filled with Filtek Z350 XT WD composite resin (3M ESPE) in color A1 and taken into position. After extravasation of the surplus material, the excesses of the cervical region were removed with an exploratory probe, followed by photoactivation for 40 seconds. Occlusal adjustment, finishing with a FG1190 FF miller (KG Sorensen) and polishing of the restorations with Shofu Super Snap discs (3M ESPE) were performed, respecting the sequence from highest to lowest granulation. The final clinical aspect, soon after the completion of the restorations can be visualized in Figure 2 d, and the patient's six-month follow-up in Figure 3.



**Figure 2d:** Clinical appearance immediately after restorations

The posterior teeth also received the necessary and adequate treatment before the patient was discharged.



**Figure 3.** Follow up 6 months after the restorations

## Discussion

Deciduous teeth play a key role in phonetics, eating, aesthetics and maintaining space for permanent teeth (12). Thus, pediatric dentistry should invest efforts to keep these dental elements healthy until the time of their rhizolysis and exfoliation. When caries lesion is installed, problems such as pain, edema, irritation, poor nutrition, among others, can cause anguish and discomfort in the child, affecting their behavior, appearance, chewing capacity and phonation (12, 13) among others. Even with all the oral health prevention policies, caries disease remains prevalent in the preschool population (14), especially in children from low-income families (15), resulting in the need for intervention by the dentist and public health policies.

For correct planning and treatment, in addition to the social and economic aspects of the child and his / her family, one must also consider the aesthetic and functional aspects. There are several treatments and materials which aim to restore aesthetics and function, as well as to prevent the recurrence of caries lesion under restorations (6).

The presented clinical case dealt with upper anterior deciduous teeth with large tissue loss (Figure 1 a) and advanced degree of root resorption of teeth 51 and 61 (Figure 1 b). Thus, even in view of the short period of time for the exfoliation of these teeth, the elaboration of the treatment plan considered the patient's main complaint, which reported great inconvenience when she suffered *bullying* at school due to the severe aesthetic alteration of these teeth.

*Bullying*, according to Olweus et al., 2011 (16), is considered an anti-social phenomenon that violates the rights of another person caused by repeated negative actions. These can be classified as direct (hitting, kicking, threatening and insulting) or indirect (gossip, spread of rumors and exclusion) (17). The demand for aesthetic dental treatment by children and parents has been increasing due to *bullying* (18). According to Al-Bitar et al. (19) 2013, the three dentofacial characteristics most commonly cited by *bullying* are spacing between the teeth, missing teeth, shape and color of the upper anterior teeth. In the case of patient Y.A.G. it was decided to rehabilitate the anterior teeth, even with an advanced degree of root resorption of the teeth 51 and 61, due to the emotional damages that the child presented, such as retraction in speech, shame of smiling and resistance to go to school.

Thus, it was decided to use composite resin since it offers excellent aesthetic results and great adhesion by means of micromechanical bonding (20) and formation of resinous tags. To dentin tissue, adhesion occurs after partial removal of the smear layer, when a hybrid layer with favorable conditions for better adhesion is created (21). Currently, composite resin is the material most used in direct aesthetic restorations (21, 22) because it offers better aesthetic results, is highly adhesive and affordable. Another aesthetic rehabilitation option is the use of zirconia crowns, which are becoming increasingly common in pediatric patients. However, the case reported shows a certain degree of rhizolysis, and the use of this treatment is not convenient due to the costs involved. In addition, there is little scientific evidence regarding the use of zirconia crowns in deciduous incisors, and the only randomized clinical trial available (24) has a limited follow-up of 6 months (25).

It should be considered that the dental remnant after removing the infected carious tissue (Figure 2 b) was sufficient for the adaptation of the stripe crowns (Figure 2 c) and restoration with composite resin (Figure 2 d).

Although this technique requires a previous laboratory phase, it saves considerable clinical time, important in child care. The strip crowns are effective in restoring heavily damaged dental crowns, malformed teeth, hypoplasia and fractured teeth (26). The restorations offer strength, durability, good aesthetics, as well as greater coverage of the dental remnant and better marginal adaptation (26). In addition, the technique is fast, affordable, inexpensive, well supported by the child and effective in offering the aesthetics and function of the dental elements. The choice of color is also very important, as it favors aesthetics making the tooth / restoration interface imperceptible, (8) providing good aesthetic results (Figure 3).

In the present clinical case, although the child was only 5 years old, there was cooperation, collaboration and participation since there was understanding of the necessity of the treatment in function of the emotional effects caused by the impairment of the teeth.

It is known that the quality of life of the child is related to his/her oral health, since dental disorders can cause disorders in his/her functional and physical performance (27). In addition, it can result in difficulties with eating and talking, isolation and shame in showing the teeth, sadness to avoid smiling and the prejudice on the part of other children (28, 29), as reported by the patient's mother in the case described. For this patient, the treatment of choice was the preparation of composite resin crowns with the aid of strip crowns, restoring the function and mainly the aesthetics, which resulted in the satisfaction of the child and the relatives.

## Conclusion

Composite restoration made with the aid of strip crowns provides a shorter clinical time, aesthetic result, re-establishment of the patient's smile and self-esteem were achieved.

## Disclosure Statement

The authors do not have any financial interest in the companies whose materials are included in this article.

## References

1. Vadiakas G. Case definition, aetiology and risk assessment of early childhood caries (ECC): a revisited review. *Eur Arch Paediatr Dent* 2008; 9: 114-125.
2. Holan G, Rahme MA, Ram D. Parents' attitude toward their children's appearance in the case of esthetic defects of the anterior primary teeth. *J Clin Pediatr Dent* 2009; 34: 141-145.
3. Marcenes W, Kassebaum NJ, Bernabe E, et al. Global burden of oral conditions in 1990-2010: a systematic analysis. *J Dent Res* 2013; 92: 592-597.
4. Wiedenfeld KR, Draughn RA, Welford JB. An esthetic technique for veneering anterior stainless steel crowns with composite resin. *ASDC J Dent Child* 1994; 61: 321-326.
5. Waggoner WF. Restoring primary anterior teeth: updated for 2014. *Pediatr Dent* 2015; 37: 163-170.
6. Halawany HS, Salama F, Jacob V, et al. A survey of pediatric dentists' caries-related treatment decisions and restorative modalities - A web-based survey. *Saudi Dent J* 2017; 29: 66-73.
7. Grosso FC. Primary anterior strip crowns: a new technique for severely decayed anterior primary teeth. *J Pedod* 1987; 11: 375-384.
8. Cotrim ER, Vasconcelos Junior AV, Haddad AC, Reis SA. Perception of adults' smile esthetics among orthodontists, clinicians and laypeople. *Dental Press J Orthod* 2015; 20: 40-44.
9. Di Blasio A, Mandelli G, Generali I, Gandolfini M. Facial aesthetics and childhood. *Eur J Paediatr Dent* 2009; 10: 131-134.



10. Tremblay L, Lovsin T, Zecevic C, Lariviere M. Perceptions of self in 3-5-year-old children: a preliminary investigation into the early emergence of body dissatisfaction. *Body Image* 2011; 8: 287-292.
11. Adewumi AO, Horton C, Guelmann M, et al. Parental perception vs. professional assessment of speech changes following premature loss of maxillary primary incisors. *Pediatr Dent* 2012; 34: 295-299.
12. Vittoba Setty J, Srinivasan I. Knowledge and Awareness of Primary Teeth and Their Importance among Parents in Bengaluru City, India. *Int J Clin Pediatr Dent* 2016; 9: 56-61.
13. Gilchrist F, Marshman Z, Deery C, Rodd HD. The impact of dental caries on children and young people: what they have to say? *Int J Paediatr Dent* 2015; 25: 327-338.
14. Tinanoff N, Reisine S. Update on early childhood caries since the Surgeon General's Report. *Acad Pediatr* 2009; 9: 396-403.
15. Sohn W, Taichman LS, Ismail AI, Reisine S. Caregiver's perception of child's oral health status among low-income African Americans. *Pediatr Dent* 2008; 30: 480-487.
16. Olweus D. Bullying at school and later criminality: findings from three Swedish community samples of males. *Crim Behav Ment Health* 2011; 21: 151-156.
17. Nansel TR, Craig W, Overpeck MD, et al. Health Behaviour in School-aged Children Bullying Analyses Working G. Cross-national consistency in the relationship between bullying behaviors and psychosocial adjustment. *Arch Pediatr Adolesc Med* 2004; 158: 730-736.
18. Al-Omari IK, Al-Bitar ZB, Sonbol HN, et al. Impact of bullying due to dentofacial features on oral health-related quality of life. *Am J Orthod Dentofacial Orthop* 2014; 146: 734-739.
19. Al-Bitar ZB, Al-Omari IK, Sonbol HN, et al. Bullying among Jordanian schoolchildren, its effects on school performance, and the contribution of general physical and dentofacial features. *Am J Orthod Dentofacial Orthop* 2013; 144: 872-878.
20. Watanabe T, Tsubota K, Takamizawa T, et al. Effect of prior acid etching on bonding durability of single-step adhesives. *Oper Dent* 2008; 33: 426-433.
21. Niu Y, Ma X, Fan M, Zhu S. Effects of layering techniques on the micro-tensile bond strength to dentin in resin composite restorations. *Dent Mater* 2009; 25: 129-134.
22. Kramer N, Reinelt C, Frankenberger R. Ten-year Clinical Performance of Posterior Resin Composite Restorations. *J Adhes Dent* 2015; 17: 433-441.
23. Lu H, Roeder LB, Lei L, Powers JM. Effect of surface roughness on stain resistance of dental resin composites. *J Esthet Restor Dent* 2005; 17: 102-108; discussion 109.

24. Walia T, Salami AA, Bashiri R, et al. A randomised controlled trial of three aesthetic full-coronal restorations in primary maxillary teeth. *Eur J Paediatr Dent* 2014; 15: 113-118.
25. Aiem E, Smail-Faugeron V, Muller-Bolla M. Aesthetic preformed paediatric crowns: systematic review. *Int J Paediatr Dent* 2017; 27: 273-282.
26. Drummond BK. Restoration of primary anterior teeth with composite crowns. *N Z Dent J* 1993; 89: 92-95.
27. Vollu AL, da Costa M, Maia LC, Fonseca-Goncalves A. Evaluation of Oral Health-Related Quality of Life to Assess Dental Treatment in Preschool Children with Early Childhood Caries: A Preliminary Study. *J Clin Pediatr Dent* 2018; 42: 37-44.
28. Bendo CB, Paiva SM, Torres CS, et al. Association between treated/untreated traumatic dental injuries and impact on quality of life of Brazilian schoolchildren. *Health Qual Life Outcomes* 2010; 8: 114.
29. Aldrigui JM, Abanto J, Carvalho TS, et al. Impact of traumatic dental injuries and malocclusions on quality of life of young children. *Health Qual Life Outcomes* 2011; 9: 78.