

Características radiográficas en la cicatrización periapical postratamiento endodóntico en pacientes de la Facultad de Odontología de la Universidad Autónoma de Yucatán

Radiographic characteristics in the periapical healing post endodontic treatment in patients of the Autonomous University of Yucatan, School of Dentistry

Oscar David Jurado Patrón¹

Andrés Vargas López¹

Elma María Vega Lizama²

Gabriel Alvarado Cárdenas²

María Eugenia López Villanueva²

Marco Ramírez Salomón²

¹ Universidad Autónoma de Yucatán. Estudiante, Facultad de Odontología

² Universidad Autónoma de Yucatán. Profesor, Facultad de Odontología

Autor para correspondencia: Elma María Vega Lizama E-mail: elma.vega@correo.uady.mx

Resumen

Introducción: El control radiográfico postratamiento endodóntico puede evaluar la cicatrización de las lesiones periapicales. El objetivo de este estudio fue determinar las características de la cicatrización radiográfica a un año después de realizado el tratamiento endodóntico; la cicatrización de las lesiones según la patología periapical al iniciar el tratamiento y documentar las causas de fracaso de los tratamientos endodónticos.

Método: Estudio prospectivo, observacional, descriptivo y longitudinal realizado en pacientes que acudieron a control de un año posterior al tratamiento endodóntico a través del Índice Periapical (PAI).

Resultados: De 395 órganos dentarios de pacientes a los que se les realizó tratamiento endodóntico un año previo a la recolección de los datos, 87 presentaron lesiones periapicales radiográficamente observables; de éstos, 40 (45.97%) acudieron al control a un año. La frecuencia de casos en los que se observó algún grado de cicatrización radiográfica un año después de realizado el tratamiento fue del 97.46%. La patología con más casos de cicatrización completa fue la periodontitis apical con tracto sinuoso. En general, el 84.61% de los casos disminuyeron 2 niveles en su PAI luego de un año. El 100% de los casos de fracaso presentaron fracturas verticales radiculares.

Conclusión: La frecuencia cicatrización periapical del tratamiento endodóntico es alta. La principal causa para el fracaso de los tratamientos documentada en este estudio fue la falta de restauración coronal que ocasionó fracturas verticales.

Palabras clave: cicatrización periapical; tratamiento endodóntico; patología periapical; cicatrización radiográfica

Abstract

Introduction: The radiographic control of the root canal treatment can evaluate the healing of the periapical lesions. The objective of this study was to determinate the characteristics of the radiographic healing that was observed after one year, during follow-up sessions; so, the healing of the lesions according to the periapical pathology at the beginning of the treatment and the causes of failure of the endodontic treatments were recorded.

Method: This is a prospective, observational, descriptive and longitudinal study, carried out in patients who attended control one year after endodontic treatment through the Periapical Index (PAI).

Results: A total of 395 teeth of patients who underwent endodontic treatment one year prior to data collection, 87 presented radiographically observable periapical lesions; of these, 40 (45.97%) attended the control at one year. The frequency of cases in which some degree of radiographic healing was observed one year after treatment was 97.46%. The pathology with more cases of complete healing was periodontitis with sinus tract. In general, 84.61% of the cases decreased

two levels in their PAI after one year. The 100% of the cases of failure presented vertical root fractures.

Conclusion: The frequency of periapical healing after endodontic treatment is high. The main cause for the failure of the treatments documented in this study was the lack of coronal restoration that caused vertical fractures.

Keywords: periapical healing; root canal treatment; periapical pathology; radiographic healing

Recibido en 23/07/2018

Aceptado en 18/09/2018

Introduction

The radiographic control of the endodontic post-treatment is used to observe the healing of the periapical injuries. When the treatment fails, the tooth continues showing radiographic signs and in some cases the complications can produce pain (Hargreaves & Berman, 2016).

The periapical disease is an acute or chronic inflammation of the periapical tissue, it is produced in 90% of the cases as a result of dental cavities but also as a result of dental procedures, impacts or injuries, teeth grinding and abrasion (Saatchi, 2007; Segura-Egea, *et al.*, 2015).

Chronic apical periodontitis is a consequence of the pulp necrosis where the inflammation hurts and causes pain to percussion, and in some cases reveal radiographic changes. Chronic apical periodontitis is asymptomatic and radiographically reveals a periradicular radiolucency (Hargreaves & Berman, 2016; Sigurdsson, 2003).

The radiographically observable periapical or periradicular osteolytic injuries are a consequence of the osseous destruction carried by the periapical and periradicular inflammation process (Ridao-Sacie *et al.*, 2007; Saatchi, 2007). On its unbalanced stage, it is possible to disperse the infection and inflammation to closer tissues and this can be considered as a severe inflammation but fortunately, this is a rare condition (Hargreaves & Berman, 2016). The

principal way to heal injuries is by reparation of tissues. Repairing is a biological process where the continuity of the tissue is established by the formation of a new tissue but it does not restore the anatomy and original function (Altare, 2010).

The main objective of the endodontic treatment is to set the conditions for the repair of the damaged periapical tissues, once the causes of the aggression are eliminated, the reaction evolves the repair process where the proliferation and differentiation of specific cells work in the reposition of destroyed tissues (Soares & Goldberg, 2012; Hargreaves & Berman, 2016).

The success of the endodontic treatment can be affected by four factors in a positive or negative way: 1) the presence or absence of apical periodontitis, 2) the apical density, 3) apical extension of the radicular obturation, and 4) the quality of the final restoration. It has been observed that teeth with previous endodontic treatment without a final restoration or with poorly adjusted treatment shows the worst periapical healing (Haapasalo *et al.*, 2011; Liang *et al.*, 2011; Kirkevang *et al.*, 2014).

The healing process takes between six months and several years (approximately 4 years). In some cases, the size of periapical lesions can persist, can reduce, can increase or show no changes (Haapasalo *et al.*, 2011; Peters & Peters, 2013).

Endodontic literature proposes to evaluate the success of a treatment by means of clinical and radiographical criteria. The clinical success is when the patient does not experiment pain in the dental piece treated by the dentist; nevertheless, this can be misleading because a chronic periapical asymptomatic injury might occur. Radiographic success is characterized by the disappearance of the radiographic sign of periapical lesion after the root canal treatment (Hilú & Balandrano-Pinal, 2009). The European Society of Endodontics recommends a follow-up visit for four years (Lynch & Burke, 2006).

A 63% of cases of teeth with periapical lesions show a considerable reduction after the second year after the endodontic treatment, therefore, a retreatment is not considered. It is important to consider following the changes of the radiolucency in the teeth with periapical lesions after two years or more of being treated (Zhang *et al.*, 2015).

Due to the periapical healing can be radiographically observable one year after endodontic treatment, the main objective of this study is to determine the characteristics in radiographic healing after one year of the treatment. The study was performed on patients who attended the

follow-up sessions after one year of treatment through the Periapical Index (PAI) (Orstavik *et al.*, 1986).

Method

This study was performed on patients in the Postgraduate Endodontics Area, School of Dentistry at the Autonomous University of Yucatan that showed radiography observable periradicular injuries at the beginning of the treatment, maintained a schedule of follow-up sessions after one year of the treatment and accepted to participate in the study as indicated in the "World Medical Association Declaration of Helsinki" (Hurts, 2014); all the patients agreed to participate in the study verbally and then, they sign a letter of informed consent. The inclusion criteria were to have a radiographically observable endodontic pathology and to accept to continue one year follow-up. The exclusion criteria were health systematic compromise presence. The elimination criteria were applied when the patients do not return to the follow-up session. During the first visit at the clinic, an endodontic diagnostic test was performed by a postgraduate student through clinical and radiographic assessment to establish the treatment plan for each case according to the postgraduate of endodontic protocol. The clinical test was based on the observation of periodontal tissues, percussion, palpation, mobility and periodontal probing. An XCP was used in all the follow-up sessions to take digital periapical X-Rays, using periapical long cone paralleling technique to estandarize the radiographic images. We also conducted anamnesis to obtain epidemiological data and evaluate the presence of other systemic and local factors. All patients were appointed 3, 6 and 9 months to determine the presence of any symptomatology and the restauration quality. And a one year follow-up session was performed in order to finish their clinical and radiographical control according to the postgraduate of endodontic protocol to discharge the patient. In the final follow-up session (one year), the teeth were clinically and radiographically analyzed to confirm systemic diseases, quality of treatment and the presence or absence of definitive restoration.

Digital periapical radiographies were recorded and analyzed using PAI (Orstavik *et al.*, 1986) and the classification of the endodontic pathologies used, was the one described by Sigurdsson (Sigurdsson, 2003). Periapical Index (PAI) is a measurement system which is modified and applied to comparative epidemiological and clinical studies. This system provides with an ordinary scale of five punctuations that go from "Normal Periapical Structure" to "Severe Periodontitis with exacerbating features" and is based on a study of histological and radiographical correlation of Brynolf. It was described for the first time by Orstavik in 1986 (Orstavik *et al.*, 1986).

The scales of PAI are as follow: 1. Normal periapical structure, 2. Small changes in bone structures, 3. Changes in bone structure with mineral loss 4. Periodontitis with well-defined radiolucent area, and 5. Severe periodontitis with exacerbating features (Orstavik *et al.*, 1986) see Figure 1.

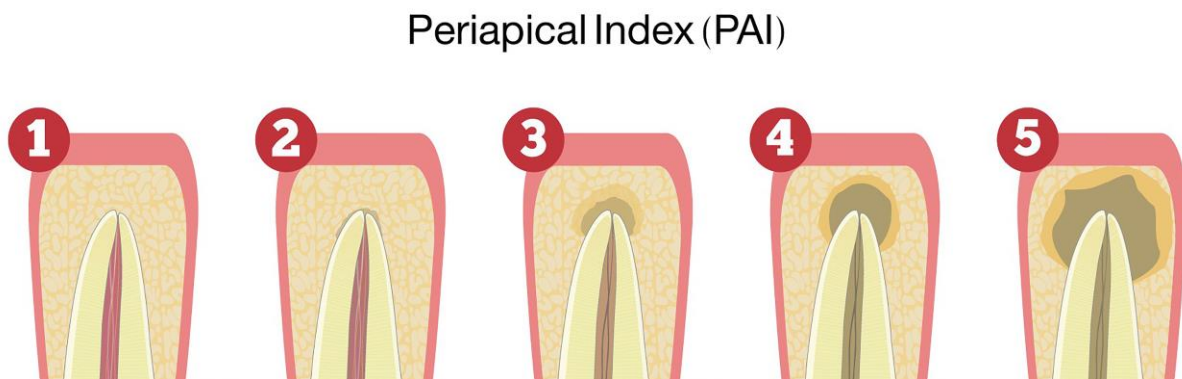


Figure 1. Representation of the periapical index.

The evaluation was made independently by two endodontic experts that were previously calibrated. The agreement between the observers was 89.74%. The four cases with disagreement were analyzed by a third endodontic expert independently. The final score for that four cases was recorded according to the agreement between the third observer and one of the original observers. Data collected was organized in an Excel® data base and percentages and graphics were calculated afterwards, the T Student test for paired data was used to observe differences between the initial and final scores. The distribution of the sample was normal.

Results

Endodontic diagnosis were performed to a total of 395 teeth, and its endodontic treatment during the study period and we could find that 87 (22.02%) presented radiographically visible periapical lesions at the sixth month follow-up session and 40 (45.97%) of those 87 patients came back to the one year follow-up sessions.

Distribution of periapical pathologies is as follows: 2 (5%) showed apical periodontitis with abscess, 6 (15%) showed apical periodontitis with sinuous tract, 10 (25%) showed acute apical periodontitis and 22 (55%) showed chronic apical periodontitis.

One tooth showed a vertical fracture in the sixth month follow-up session due to the absence of definitive restoration and it was eliminated of the research; 38 of the 39 patients (97.43%) showed evident radiographic healing; one (2.56%) remained with no radiographic change, however asymptomatic, for that reason, the frequency of observable radiographic healing after one year was 97.43%, see Figure 2.

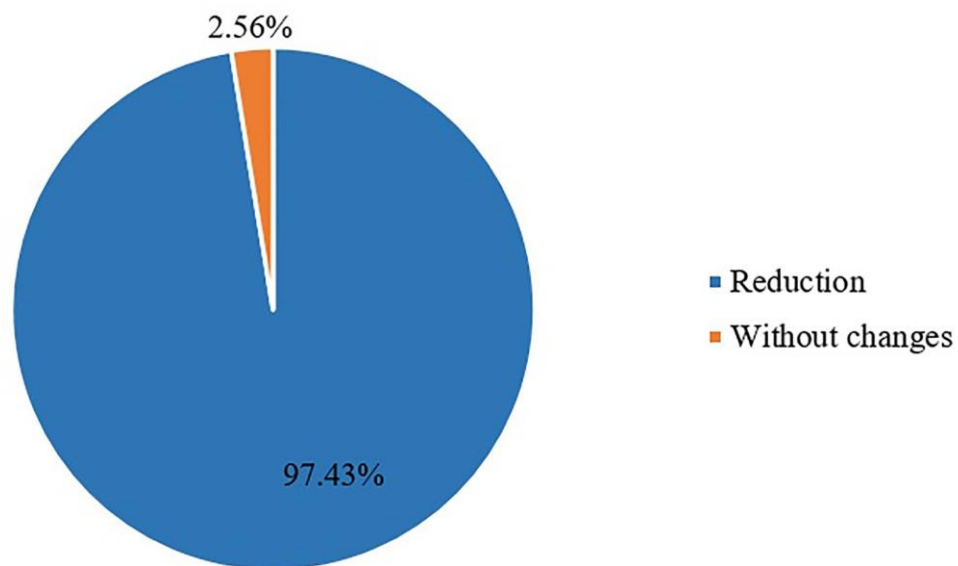


Figure 2. Frequency of radiographic healing 1 year after the treatment (38 patients).

After one year of the endodontic treatment, we observed a decrease of the two cases with apical periodontitis with abscess. One lesion healed completely from PAI 3 to 1 and the other from PAI 4 to 2. In the six cases of periapical periodontitis with sinuous tract, we observed a healing of 100% of the cases passing from PAI 3 to 1. In ten cases with severe apical periodontitis we obtained an initial PAI 3 in six cases and a PAI 5 in 4 cases; after one year those that started in PAI 3, four healed to PAI 1 and two to PAI 2; and the cases of PAI 5, three healed to a PAI 2 and one healed to a PAI 3.

In the twenty one cases with chronic apical periodontitis, eleven cases showed a PAI 3 and nine cases showed a PAI 4, after a year of treatment the cases that started in PAI 3 changed to PAI 1 and one case showed no changes; the nine cases with PAI 4 changed to PAI 2.

After one year, the healing index of all radiographic observable lesions was 97.43% where 53.84% was a complete healing and 43.58% was partial healing. Thirty three of the cases (84.61% lowered two levels in the PAI index scale, 3 (7.69%) three levels, 2 (5.12%) one level and 1 (2.56%) showed no changes. The distribution of the sample was normal, so we used the T Student test for the paired data. The score threw a statistics difference between the initial and final score $t=25.372$ with 38 d.f., $p=0.000$. The mean of PAI at the endodontic treatment was 3.74 with a s.d. of 0.97. The mean after one year finished the treatment was 1.77 with a s.d. of 0.90. The difference between the mean in the initial and final evaluations was 1.97 with a s.d. of 0.49; thus, after a year we could observe a reduction of two levels.

It was also found that three patients showed vertical root fractures before the six months treatments because of the lack of rehabilitation and just one patient go to the six month control visit but the patient was eliminated from the study because of the absence of coronal sealing and vertical root fracture.

Discussion

In endodontics, it is important to have follow-up sessions, but in the first months after treatment, it is difficult to observe evidence of periapical lesions healing. In this study, the frequency of observable radiographic healing after one year was 97.43%.

According to the PAI, the results of the present study showed 43.58% partial healing and 53.84% complete healing. There are many studies with different follow-up sessions protocol to evaluate the success of the endodontic treatment using periods of time between six months and several years (Haapasalo *et al.*, 2011; Peters & Peters, 2013; Zhang *et al.*, 2015). It is remarkable that of the entire sample, 84.61% showed a two-level decrease from their initial PAI index stage. So, we found in this study, that one year was enough to see significative radiographical changes in the healing of chronical pathologies.

Although many studies refer to the need for long-term follow-up in cases of periapical lesions, the results of the present study (two stages of improvement of the PAI), they can be applied in clinical practice as indicators of a healing process in progress.

In the present study, 22.02% of the endodontic patients had visible periapical lesion as expected, since most studies report similar data. In a research performed by Beconsall-Ryan *et al.* 2010, it presented that 29.2% of the total population showed radiographically observable periapical lesions, and Davies *et al.* 2016 presented that 55 patients (20%) out of 273 showed periapical lesions. (Timmerman *et al.*, 2017) also described that 179 (25.8%) out of 695 patients who were treated with panoramic radiographs showed periapical lesions which is comparable with this study since the total is of the patients with periapical lesions is 22.02%.

Peters *et al.* (2011) obtained, of a total of 178 patients tested with panoramic radiographs that 93 (52.24%) cases showed periapical lesions which differs from the previous studies and ours because it is based in the methodology of Cleen *et al.* (1993) that considers a periapical lesion to any widening of the periodontal ligament that doubles the size of it, but this kind of lesion can be considered in the PAI 2 which is not a periapical lesion. Also, the panoramic radiograph does not show an accuracy comparable to a periapical radiograph.

Timmerman *et al.* (2017) described that 11 (45.88%) out of 24 cases had a PAI 3, 9 (37.5%) showed a PAI 4, and 4 cases (16.66%) showed a PAI 5; Tsesis *et al.* found that in a research of 200 teeth with periapical injuries, 88 (44%) showed a PAI 3, 22 (11%) a PAI 2, and 2 cases (1%) a PAI 5. These distributions of the frequency of PAI index are comparable to this

research because of a total of 39 cases, during the radiographic initial evaluation, it was found that 24 (61.5%) showed a PAI 3, 11 (28.2%) a PAI 4 and 4 cases (10.25%) a PAI 5.

Huumonen & Ørstavik (2013) obtained in their study that the teeth with an initial PAI from 3 to 5 showed a meaningful improvement in the first 3 months, 27% were considered healthy reaching a PAI 1 or 2; healing during the first year of groups with PAI 4 and 5 were slower than the patients with a PAI 3. Monardes *et al.* (2016) obtained from a total of 227 cases, that 213 (93.8%) reached a clinic and radiographic success and 14 (6.2%) failed, these results are similar to the results of our research since we also obtained a decrease in the lesions of two levels in the PAI after one year of control.

In the present study, 38 (97.43%) of the cases with an initial visible periapical lesion showed a periapical healing observed radiographically after one year of treatment this may be due to the standardization level in the treatments performed by the students in the Postgraduate Endodontic Area at the Autonomous University of Yucatan. Timmerman *et al.* (2017) performed an endodontic treatment in 54 patients and found that six (11.1%) cases did not show periapical lesions in their subsequent visits and 25 (46%) remained with no changes which differ from this research because from a total of 39 cases it was found that 21 cases (53.48%) did not show periapical lesions in their subsequent visit; however, 17 (43.58%) showed a reduction in their injuries and just 1 case (2.56%) showed no changes; the difference in this studies might be because Timmerman *et al.* (2017) used panoramic radiographs in his research and this could reduce the clarity of the images which can lead to having a poor observation of the radiographic changes.

In the research of Peralta-Lazo *et al.* (2017) found an endodontic success rate of 98% in 52 teeth after the six-month visit and the remaining 2% was a questionable case (showed no change but was asymptomatic) and one failure caused by a fracture because of the lack of rehabilitation. This research also showed similar numbers since we obtained that six patients (15%) had no restoration after six months of the treatment and one case was considered as a failure because showed a vertical root fracture, however, we obtained a high percentage of radiographic success. The occurrence of root fracture is quite similar to the 5% recently reported by Pirani *et al.* (2018).

Timmerman *et al.* (2017) described that from 54 endodontic treatment cases that showed periapical lesions in their first control visit with panoramic radiographs, twenty one (38.9%) did

not show coronal restoration in subsequent evaluations, of which, just one case (4.8%) did not show a subsequent periapical lesion, which is important to emphasize because we also found in this research that from 395 endodontic cases, 107 (27.08%) did not show coronal restoration (3 showed vertical root fractures at 6 months before the initial treatment) added to 154 (39.98%) patients who did not show to their control visit that lead us to the idea that we have to emphasize more with patients to rehabilitate their teeth to have a better success rate in their treatment. It is really difficult to achieve patients again for the follow-up sessions. Despite all efforts to explain the importance, we could not do it for a large sample size.

The particular case that showed no radiographic change was a healthy patient whose endodontic treatment presented an endodontic overextension. Pirani *et al.* 2018 have reported the healing outcome was not impacted by the extrusion of the root filling, whereas Ng *et al.* 2011 have reported an adverse impact. So, the impact of root filling extrusion on the prognosis of apical periodontitis has not yet been definitively clarified (Hargreaves & Berman 2016). The case that was eliminated corresponded to a diabetic patient with no rehabilitation, however, the failure was because of the lack of rehabilitation which leads to a vertical root fracture.

Conclusion

The cases in which a periapical healing was observed radiographically after one year of treatment was 97.43%.

The index of periapical healing of the lesions, after one year exhibited that 43.58% of the cases showed partial healing and a 53.84% showed complete healing.

Of all cases, 84.61% showed a two-level decrease from their initial PAI index stage.

Acknowledgements

We are grateful to Fernando Aguilar Ayala, Ruben Herrera Atoche and Mauricio Escoffié Ramírez, current Dean and authorities of the School of Dentistry (UADY) for facilitating the investigation. This research was financed by the School of Dentistry (UADY) SISTPROY

Project 2017-0002. The authors report no fees or financial arrangements paid to consultants or other investigations and have nothing to disclose. The authors deny any conflicts of interest related to this study.

References

- Herica A, Rivas J, Geraldés F, Mauricio G. (2007). Evaluación del éxito clínico y radiográfico post-tratamiento de dientes con necrosis pulpar y lesión periapical visible radiográficamente. *Acta Odontológica Venezolana* 45: 1–6.
- Altare, L. (2010). Reparación apical y periapical post-tratamiento endodóntico. *Journal of Endodontics Rosario* 2: 433–61.
- Beconsall-Ryan K, Tong D, Love R.M. (2010). Radiolucent Inflammatory Jaw Lesions: A Twenty- Year Analysis. *International Endodontic Journal* 43: 859–65.
- Cleen MJ, Schuurs AH, Wesselink PR, Wu MK. (1993). Periapical status and prevalence of endodontic treatment in an adult dutch population. *International Endodontic Journal* 26: 112–19.
- Davies A, Patel S, Foschi F, Andiappan M, Mitchell PJ, Mannocci F. (2016). The detection of periapical pathoses using digital periapical radiography and cone beam computed tomography in endodontically retreated teeth - Part 2: A 1 year post-treatment follow-up. *International Endodontic Journal* 49: 623–35.
- Haapasalo M, Shen Y, & Ricucci D. (2011). Reasons for Persistent and Emerging Post-Treatment Endodontic Disease. *Endodontic Topics* 18: 31–50.
- Hargreaves KM & Berman LH. (2016). *Cohen's Pathways of the Pulp* 11th ed. St. Louis, Elsevier.
- Hilú R, Balandrano-Pinal F. (2009). El éxito en endodoncia. *Endodoncia* 27: 131–38.
- Huomonen S, Ørstavik D. (2013). Radiographic follow-up of periapical status after endodontic treatment of teeth with and without apical periodontitis. *Clinical Oral Investigations* 17: 2099–2104.
- Hurst S (2014). Declaration of Helsinki and protection for vulnerable research participants. *J Am Med Assoc* 12: 1252-72.
- Kirkevang LL, Ørstavik D, Wenzel A, Vaeth M. (2014). Prognostic value of the full-scale periapical index. *International Endodontic Journal* 48: 1051–8.

- Liang YH, Li G, Wesselink PR, Wu MK. (2011). Endodontic outcome predictors identified with periapical radiographs and cone-beam computed tomography scans. *Journal of Endodontics* 37: 326–31.
- Lynch CD, Burke FM. (2006). Quality of root canal fillings performed by undergraduate dental students on single-rooted teeth. *European Journal of Dental Education* 10: 67–72.
- Monardes H, Lolas C, Aravena J, Gonzáles H, Abarca J. (2016). Evaluación del tratamiento endodóntico y su relación con el tipo y la calidad de la restauración definitiva. *Revista Clínica de Periodoncia, Implantología y Rehabilitación Oral*. 9: 108-13.
- Ng YL, Mann V, Gulabivala K (2011). A prospective study of the factors affecting outcomes of nonsurgical root canal treatment: part 1: periapical health. *International Endodontic Journal*. 44:583-609.
- Orstavik D, Kerekes K, Eriksen HM. (1986). The periapical index a scoring system for radiographic assessment of apical periodontitis. *Dental Traumatology* 2: 20–34.
- Peralta-Lazo EC, Ramirez-Salomón M, Alvarado-Cádenas G, López-Villanueva MA, Ayala-Ham A, Vega-Lizama EM. (2017). Frecuencia del éxito del tratamiento endodóntico en la Facultad de Odontología de la UADY. *Revista Odontológica Latinoamericana*. 9: 57-62.
- Peters CI, Peters O. (2013). Cone beam computed tomography and other imaging techniques in the determination of periapical healing. *Endodontic Topics* 26: 57–75.
- Peters LB, Lindeboom JA, Elst ME. (2011). Prevalence of apical periodontitis relative to endodontic treatment in an adult dutch population: a repeated cross-sectional study. *Oral Surg Oral Med Oral Pathol Oral Radiol Endod*. 111: 523–28.
- Pirani C, Friedman S, Gatto MR, Iacono F, Tinarelli V, Gandolfi MG, Prati C. (2018). Survival and periapical health after root canal treatment with carrier-based root fillings: five-year retrospective assessment. *International Endodontic Journal*. 51: 178–88.
- Ridao-Sacie C, Segura-Egea JJ, Fernández-Palacín A, Bullón-Fernández P, Ríos Santos JV. (2007). Radiological assessment of periapical status using the periapical index: comparison of periapical radiography and digital panoramic radiography. *International Endodontic Journal* 40: 433–40.
- Saatchi M. (2007). Healing of large periapical lesion: a non-surgical endodontic. *Australian Endodontic Journal* 33: 136–40.
- Segura-Egea JJ, Martin-Gonzalez J, Castellanos-Cosano L. (2015). Endodontic medicine:

connections between apical periodontitis and systemic diseases. *International Endodontic Journal* 48: 933–51.

Sigurdsson A. (2003). Pulpal Diagnosis. *Endodontic Topics* 5: 12–25.

Soares I, Goldberg F. (2012). Endodoncia, técnica y fundamentos. *Panamericana*, 272–93.

Timmerman A, Calache H, Parashos P, Timmerman AN. (2017). A cross sectional and longitudinal study of endodontic and periapical status in an australian population. *Australian Dental Journal* 62: 345–54.

Zhang MM, Liang YH, Gao XJ, Jiang L, Van-Der-Sluis L, Wu MK. (2015). Management of apical periodontitis: healing of post-treatment periapical lesions present 1 year after endodontic treatment. *Journal of Endodontics* 41: 1020–25.