

Received:  
11-XII-2019

Dental Findings in Kabuki Syndrome:  
A Systematic Review for Dentistry

Accepted:  
21-I-2020

Published Online:  
21-II-2020

Hallazgos dentales en el síndrome de Kabuki:  
Una revisión sistemática para la odontología

Ricardo Barbosa-Lima DDS<sup>1</sup>; Amanda Lopes DDS<sup>1</sup>; Juliely N. F. de Moura DDS<sup>1</sup>;  
Sabrina N. Ribeiro DDS<sup>1</sup>; Matheus S. N. T. Cardoso MD<sup>2</sup>

1. Dentistry student, Department of Dentistry of Lagarto, Federal University of Sergipe, Lagarto, Sergipe, Brazil.
2. Medical student, Department of Medicine of Lagarto, Federal University of Sergipe, Lagarto, Sergipe, Brazil.

Correspondence to: Mr. Ricardo Barbosa-Lima - [ricardoblina@academico.ufs.br](mailto:ricardoblina@academico.ufs.br)

**ABSTRACT:** Kabuki syndrome consists in a series of congenital anomalies involving intellectual disability, hypotonia, and facial and body dysmorphism. In addition to these cardinal signs, craniofacial and dental changes are frequently observed, although they are not fully understood. Thus, the aim of this article is to present the dental findings in patients with Kabuki syndrome. This is a systematic review developed according to the PRISMA protocol. A search strategy with descriptors ("kabuki syndrome" AND "dentistry") was applied to six databases. As inclusion criteria, we selected clinical case reports that addressed dental findings in one or more patients with Kabuki syndrome between 1999 and 2019, without restrictions regarding gender, age or language. Data collection in all databases was performed by a calibrated evaluator and titles, abstracts and full-text studies were systematically analyzed. Eleven case reports that fit the proposed inclusion criteria were found. After the qualitative synthesis, teeth absence or agenesis were the most reported findings, being observed by nine authors. Less frequent dental findings in patients with this syndrome are taurodontism, microdontia, fusion, gemination and conical or screwdriver-shaped teeth. In fact, when any syndrome or genetic condition is related to manifestations of dental interest, the dental surgeon should be able to investigate them, especially teeth agenesis or absence. For this reason, the dentist should be aware of the manifestations of Kabuki syndrome, contributing to patients' understanding and management.

**KEYWORDS:** Kabuki syndrome; Genetics; Oral manifestations; Tooth abnormalities; Case reports; Systematic review.

**RESUMEN:** El síndrome de Kabuki consiste en una serie de anomalías congénitas que involucran discapacidad intelectual, hipotonía y dismorfismo facial y corporal. Además de estos signos cardinales, con frecuencia se observan cambios craneofaciales y dentales, aunque no se entienden completamente. Por lo tanto, el objetivo de este artículo es presentar los hallazgos dentales en pacientes con síndrome de Kabuki. Esta es una revisión sistemática desarrollada de acuerdo con el protocolo PRISMA. Se aplicó una estrategia de búsqueda con descriptores ("síndrome de kabuki" AND "odontología") a seis bases de datos. Como criterios de inclusión, seleccionamos informes de casos clínicos que abordaban los hallazgos dentales en uno o más pacientes con síndrome de Kabuki entre 1999 y 2019, sin restricciones de género, edad o idioma. La recolección de datos en todas las bases de datos fue realizada por un evaluador calibrado y los títulos, resúmenes y estudios de texto completo fueron analizados sistemáticamente. Se encontraron once informes de casos que se ajustan a los criterios de inclusión propuestos. Después de la síntesis cualitativa, la ausencia de dientes o la agenesia fueron los hallazgos más reportados, siendo observados por nueve autores. Los hallazgos dentales menos frecuentes en pacientes con este síndrome son taurodoncia, microdoncia, fusión, geminación y dientes cónicos o con forma de destornillador. De hecho, cuando cualquier síndrome o condición genética se relaciona con manifestaciones de interés dental, el cirujano dental debe poder investigarlas, especialmente la agenesia o ausencia de los dientes. Por esta razón, el dentista debe ser consciente de las manifestaciones del síndrome de Kabuki, lo que contribuye a la comprensión y el manejo de los pacientes.

**PALABRAS CLAVES:** Síndrome de Kabuki; Genética; Manifestaciones orales; Anormalidades de los dientes; Reportes del caso; Revisión sistemática.

## INTRODUCTION

First described in 1981 by two Japanese scientists, Kabuki syndrome (KS) consists in a set of congenital anomalies and affects one in every 32.000 or 35.000 newborns in Japan. This name was given by two Japanese researchers, Kuroki and Niikawa, that considered the characteristic facial dysmorphism of the affected individuals similar to the face painting used by Kabuki actors, a traditional theater in their country. These are long palpebral fissures with lateral third eversion associated with the depressed nose tip and prominent ears (1-2).

In addition to this facial dysmorphism described, it is possible to observe arched eyebrows, short

stature for age, reduced intellectual abilities, cardiac anomalies, skeletal anomalies (in fingers, spine and hip), ureteral malformation and dermatoglyphic abnormalities in fingerprints. Additionally to the name Kabuki syndrome, the most popular term, this set of congenital anomalies can also be identified as Kabuki makeup syndrome or Niikawa-Kuroki syndrome (OMIM # 147920) (1-2).

The etiology of KS, a rare syndrome, is not yet fully understood by science. Currently, it is considered that two genes are described as causing KS in the individuals evaluated: KMT2D and KDM6. For the first gene, the mutation can be found on chromosome 12q13, while for the second gene, the mutation can be found on chromosome Xp11.23. Considering the many

possible deleterious variations, patients often present different phenotypic spectra and severity of congenital anomalies (2-3).

Although there are no consolidated diagnostic criteria for KS, there is consensus on the clinical observation of five cardinal signs: characteristic facial dysmorphism, skeletal abnormalities, unusual dermatoglyphic patterns, mild or moderate intellectual impairment and growth deficiency. However, it is necessary to consider that isolated case reports of KS present other less frequent signs and symptoms, including craniofacial and dental variations. Detection and analysis of mutations in the KMT2D and KDM6 genes may be a way of confirming the clinical diagnosis of KS (1,3).

Along with the five cardinal signs, other changes seen less frequently in patients with KS help in the differential diagnosis between KS and other syndromes associated with congenital anomalies. In this context, alterations of the craniofacial complex, such as arched palate and cleft palate can be observed in up to 72% and 35%, respectively, of patients with KS. This frequency refers to a set of 350 cases reported in the scientific literature. Additionally, bimaxillary protrusion, lip hypotonia, malocclusions and tongue muscle alterations can be found in case reports (4-6).

Significantly and nonspecifically, dental anomalies can be observed in up to 68% of patients with KS. Although the abnormal dental characteristics observed are not detailed, it is a significant portion that demands more appropriate investigations (4-6). Thus, the aim of this article is to present the dental findings in patients with Kabuki syndrome.

## METHODS

This is a systematic review of the scientific literature. To develop it, the recommendations of the PRISMA (Reporting Items for Systematic Reviews and Meta-Analyses) protocol in the Brazilian version

were adopted as the methodological framework (7). The question that guided the development of this bibliographic research was: what are the dental findings observed in patients with Kabuki syndrome?

As inclusion criteria, we selected clinical case reports that addressed dental findings in one or more patients with Kabuki syndrome between 1999 and 2019, without restrictions regarding gender, age or language. Other studies and case reports that did not report dental findings were excluded, as well as studies that could not be fully accessed and studies published outside the delimited timeline.

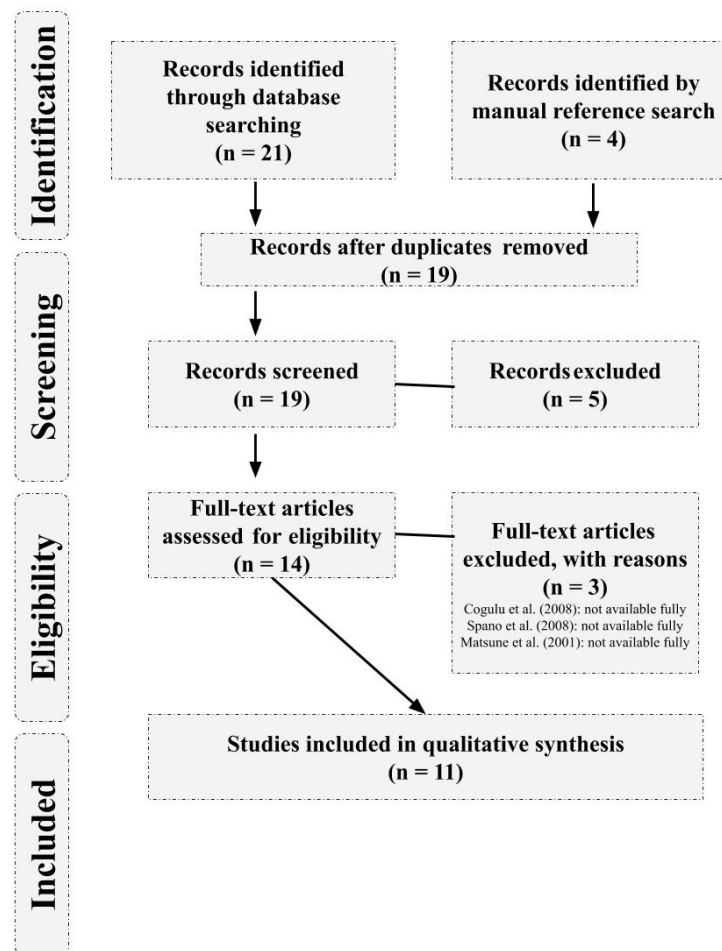
The databases accessed were Medical Literature Analysis and Retrieval System Online (MEDLINE/PubMed), Web of Science, Scopus, Scientific Electronic Library Online (SciELO), Latin American and Caribbean Health Sciences Literature (LILACS) and Virtual Health Library - Brazil (VHL). The search strategy consisted in a combination of two descriptors extracted from Medical Subject Headings (MeSH), namely: "kabuki syndrome" AND "dentistry". No additional commands were used to filter the database searches and the last consultation was held on 05 January 2020.

Data collection in all databases was performed by a calibrated evaluator. In the first round, the author evaluated all the titles, abstracts and complete studies of the screened articles, deciding to include or exclude each one. In the second round, after seven days, the author reevaluated the same articles under the same criteria, attributing the inclusion or exclusion by title, abstract or complete study again. The observed gross agreement level was 90.5% and the intra-examiner Cohen's Kappa coefficient was 0.83 agreement for study selection. Data were extracted independently by the same calibrated evaluator and the other authors were available to check the extracted data.

After the initial scope of articles was defined, their references were manually consulted for other case reports that fit our inclusion criteria and were not reached by the search strategy. The variables of interest were the individual characteristics of patients with Kabuki syndrome, such as age, gender and dental findings observed by the authors. The

risk of bias in case reports was measured by The Joanna Briggs (JBI) appraisal tool for case reports (8). The PRISMA flow diagram for study screening is available in figure 1, the synthesis of data extracted from the included articles is available in table 1 and the risk of bias of case reports is available in table 2.

## RESULTS



**Figure 1.** PRISMA flow diagram for study screening.

**Table 1.** Synthesis of dental findings in patients with Kabuki syndrome.

<b>Authorship &amp; Year</b>	<b>Sample</b>	<b>Age</b>	<b>Sex</b>	<b>Dental findings</b>
Santos et al. (9) (2019)	1 patient	2 years old	Male	Talon cusp (primary upper central incisor); Upper and lower canines with coniform anatomy; Upper and lower canines in infraocclusion; Absence of second upper and lower molars
Silva-Andrade et al. (10) (2019)	8 patients	between 3 and 16 years old	3 females and 5 males	Enamel hypoplasia; Delayed tooth eruption; Tooth agenesis; Microdontia; Fusion
Tuna et al. (11) (2012)	1 patient	5 years old	Male	Severe tooth agenesis/absence
Teixeira et al. (12) (2009)	9 patients	between 6 and 18 years old	6 females and 3 males	Tooth agenesis/absence
Rocha et al. (13) (2008)	1 patient	9 years old	Male	Supranumerary teeth; Taurodontism (molar)
dos Santos et al. (14) (2006)	1 patient	3 years old	Male	Tooth agenesis/absence; Fusion; Gemination
Atar et al. (15) (2006)	1 patient	2 years old	Male	Screwdriver shaped teeth (primary upper central incisors)
Schrander-Stumpel et al. (16) (2005)	20 patients	between 1 and 34 years old	13 females and 7 males	Tooth agenesis/absence
Shalev et al. (17) (2004)	3 patients	Undetermined	3 males	Tooth absence; Conical shaped teeth (incisors)
Petzold et al. (18) (2003)	4 patients	between 13 and 18 years old (unclear)	2 females and 2 males	Teeth crown size alterations; Flattened teeth crowns; Taurodontism (molar); Teeth root development alterations; Conical shaped teeth (upper incisors) Tooth agenesis;
Mhanni et al. (19) (1999)	8 patients	Between 2 and 11 years ago	6 females and 2 males	Tooth agenesis/absence; Screwdriver shaped teeth (incisors)

**Table 2.** Risk of bias suggested by JBI appraisal tool for case reports.

Criteria questions	Santos et al. (9)	Silva-Andrade et al. (10)	Tuna et al. (11)	Teixeira et al. (12)	Rocha et al. (13)	dos Santos et al. (14)	Atar et al. (15)	Schrande-Stumpel et al. (16)	Shalev et al. (17)	Petzold et al. (18)	Mhanni et al. (19)
1. Were patient's demographic characteristics clearly described?	Yes	Yes	Unclear	Yes	No	Yes	Yes	No	Yes	Yes	Yes
2. Was the patient's history clearly described and presented as a timeline?	Yes	Yes	Yes	Yes	Yes	No	Yes	Yes	No	Yes	No
3. Was the current clinical condition of the patient on presentation clearly described?	Yes	Yes	Yes	Yes	Yes	Yes	Yes	Yes	Yes	Yes	Yes
4. Were diagnostic tests or assessment methods and the results clearly described?	Yes	Yes	Yes	Yes	Yes	Unclear	Unclear	Yes	Yes	Yes	Unclear
5. Was the intervention(s) or treatment procedure(s) clearly described?	N/A	N/A	N/A	N/A	N/A	N/A	N/A	N/A	N/A	N/A	N/A
6. Was the post-intervention clinical condition clearly described?	N/A	N/A	N/A	N/A	N/A	N/A	N/A	N/A	N/A	N/A	N/A
7. Were adverse events or unanticipated events identified and described?	N/A	N/A	N/A	N/A	N/A	N/A	N/A	N/A	N/A	N/A	N/A
8. Does the case report provide takeaway lessons?	Yes	Yes	Yes	Yes	Yes	Yes	Yes	Yes	Yes	Yes	Yes
Risk of bias suggested	Very low	Very low	Low	Very low	Low	Medium	Low	Low	Very low	Very low	Medium

N/A: not applicable.

## DISCUSSION

After a systematic search in the literature, 11 case reports that fit the proposed inclusion criteria were found (9-19). In all, 57 patients were evaluated, 30 women and 27 men. Among the 11 studies included in the qualitative synthesis, teeth absence or agenesis were the most reported findings, being observed by nine authors (9-12,14,16-19). The risk of bias suggested by The Joanna Briggs (JBI) appraisal tool for case reports was low or very low for most studies.

In fact, the absence of teeth is strongly associated with KS. In patients with this syndrome, such changes may be observed in primary and permanent teeth. Although few data are available, lateral incisor, canine and premolar may be absent more frequently (10-11). Interestingly, Rocha *et al.* (13) reported the presence of supernumerary teeth in a nine-year-old boy with no reported absent teeth. Thus, although the teeth absence or agenesis is frequently found in patients with KS, it cannot be understood as a cardinal sign (9).

In addition, Santos *et al.* (9) were pioneers in observing a talon cusp in a patient with KS, an experience never described before. As the authors emphasize, it is an uncommon finding for KS, with a low prevalence in healthy individuals, although other genetic syndromes are associated with its incidence, such as Rubinstein-Taybi syndrome, suggesting that the etiology of this variation may have a determining genetic component (9,20).

It is not uncommon to observe reports of KS patients with conical (9,17-18) or screwdriver-shaped teeth, especially the upper incisors (15,19). Despite fewer incidents, these changes cause immediate aesthetic impact and may lead caregivers to seek dental care for investigations and treatments, providing an opportunity to investigate other dental findings and diagnostic cardinal signs for KS. In addition, the dental

surgeon should pay attention to the diagnosis of other conditions with similar clinical presentations, for example, children with congenital syphilis who developed Hutchinson incisors (15-19,21).

Less frequent complications such as fusion, gemination and taurodontism, may be observed by radiographic examinations of patients with KS. It is important to recognize that among them, taurodontism is mostly relevant because it is found in a number of other syndromes, such as tricho-dento-osseous and Klinefelter syndrome. Although there is no consensus among authors, some studies indicate that the prevalence of taurodontism in some healthy populations may be moderate or high. In addition, endodontic management requires special attention from dental surgeons (10,13,14,18,22,23).

In fact, when any syndrome or genetic condition is related to manifestations of dental interest, the dental surgeon should be able to investigate them, especially teeth agenesis or absence. Some scientific evidence generally supports that the absence of dental germs is the manifestation most associated with genetic syndromes and may be associated with other characteristics, such as teeth in infraocclusion and microdontia of lateral incisor, both reported in patients with KS (9,10). From this perspective, panoramic radiographs can be a useful diagnostic tool for dental anomalies (24-26).

Recently, in 2019, an international expert group drafted a proposal for new diagnostic criteria for KS, with the participation of Norio Niikawa. After systematically reviewing 70 scientific publications involving patients diagnosed molecularly with KS, the group suggests that the diagnosis should take into account intellectual impairment and hypotonia associated with facial and body dysmorphism in various phenotypic presentations, which have been increasingly investigated in diverse carrier populations of the syndrome. However, in this



proposal, dental findings were only commented and are not part of the diagnostic criteria (27-28).

Currently, it is understood that KS has a genetic heterogeneity and a wide phenotypic variation. In addition, cardinal signs have been increasingly explored for new genetic correlations and forms of treatment. Craniofacial and dental manifestations, however, remain poorly understood in KS and new studies with more significant samples may help in understanding these findings (11-12,29-30).

## CONCLUSION

We can conclude that the main dental findings of Kabuki syndrome are teeth absences and agenesis. However, changes in tooth shape are also frequently reported in case reports and may, together with other signs, aid in the diagnosis of this syndrome. For this reason, the dentist should be aware of the manifestations of Kabuki syndrome, contributing to patients' understanding and management.

## REFERENCES

- Cheon C. K., Ko J. M. Kabuki syndrome: clinical and molecular characteristics. *Korean J Pediatr*. 2015 Sep; 58 (9): 317-324.
- Shangguan H., Su C., Ouyang Q., Cao B., Wang J., Gong C., et al. Kabuki syndrome: novel pathogenic variants, new phenotypes and review of literature. *Orphanet J Rare Dis*. 2019; 14: 255.
- Geneviève D., Amiel J., Viot G., Le Merrer M., Sanlaville D., Urtizberea A., et al. Atypical findings in Kabuki syndrome: report of 8 patients in a series of 20 and review of the literature. *Am J Med Genet A*. 2004 Aug 15; 129A (1): 64-8.
- Sattur A., Deshmukh P. K., Abraham L., Naikmasur V. G. Kabuki Make-up Syndrome – A Case Report with Electromyographic study. *J Clin Diagn Res*. 2014 Nov; 8 (11): ZD03-ZD06.
- Matsumoto N., Niikawa N. Kabuki make-up syndrome: a review. *Am J Med Genet C Semin Med Genet*. 2003 Feb 15; 117 C (1): 57-65.
- Adam M. P., Hudgins L. Kabuki syndrome: a review. *Clin Genet*. 2005 Mar; 67 (3): 209-19.
- Galvão T. F., Pansani T. S. A., Harrad, D. Principais itens para relatar Revisões sistemáticas e Meta-análises: A recomendação PRISMA. *Epidemiol. Serv. Saúde*. 2015 Jun; 24 (2): 335-342.
- The Joanna Briggs Institute (JBI). *Critical Appraisal Checklist for Case Reports*. 2017.
- Santos C. N., Cardoso M. C. A. C., Turrioni A. P., Santo A. S. M., Paranhos L. R. Talon cusp in the temporary dentition of a patient with Kabuki syndrome: Case report with a two-year follow-up. *Spec Care Dentist*. 2019 Nov; 39 (6): 624-630.
- Silva-Andrade N., López-Ortega K., Gallottini M. Orofacial features and medical profile of eight individuals with Kabuki syndrome. *Med Oral Patol Oral Cir Bucal*. 2019 Sep; 24 (5): e630-e635.
- Tuna E. B., Marşan G., Gençay K., Seymen F. Craniofacial and dental characteristics of Kabuki syndrome: nine years cephalometric follow-up. *J Clin Pediatr Dent*. 2012 Summer; 36 (4): 393-400.
- Teixeira C. S., Silva C. R., Honjo R. S., Bertola D. R., Albano L. M., Kim C. A. Dental evaluation of Kabuki syndrome patients. *Cleft Palate Craniofac J*. 2009 Nov; 46 (6): 668-73.
- Rocha C. T., Peixoto I. T., Fernandes P. M., Torres C. P., de Queiroz A. M. Dental findings in Kabuki make-up syndrome: a case report. *Spec Care Dentist*. 2008 Mar-Apr; 28 (2): 53-7.
- dos Santos B. M., Ribeiro R. R., Stuaní A. S., de Paula e Silva F. W., de Queiroz A. M. Kabuki make-up (Niikawa-Kuroki) syndrome: dental and craniofacial findings in



- a Brazilian child. *Braz Dent J.* 2006;17 (3): 249-54.
15. Atar M., Lee W., O'Donnell D. Kabuki syndrome: oral and general features seen in a 2-year-old Chinese boy. *Int J Paediatr Dent.* 2006 May; 16 (3): 222-6.
  16. Schrandt-Stumpel C. T., Spruyt L., Curfs L. M., Defloor T., Schrandt J. J. Kabuki syndrome: Clinical data in 20 patients, literature review, and further guidelines for preventive management. *Am J Med Genet A.* 2005 Jan 30; 132A (3): 234-43.
  17. Shalev S. A.1, Clarke L. A., Koehn D., Langlois S., Zackai E. H., Hall J. G., et al. Long-term follow-up of three individuals with Kabuki syndrome. *Am J Med Genet A.* 2004 Mar 1; 125A (2): 191-200.
  18. Petzold D., Kratzsch E., Opitz Ch., Tinschert S. The Kabuki syndrome: four patients with oral abnormalities. *Eur J Orthod.* 2003 Feb; 25 (1): 13-9.
  19. Mhanni A. A., Cross H. G., Chudley A. E. Kabuki syndrome: description of dental findings in 8 patients. *Clin Genet.* 1999 Aug; 56 (2): 154-7.
  20. Elmubarak N. A. Genetic Risk of Talon Cusp: Talon Cusp in Five Siblings. *Case Rep Dent.* 2019 Aug 27; 2019: 3080769.
  21. Chotta N. A., Mgongo M., Msuya S. E., Nyombi B. M., Uriyo J. G., Stray-Pedersen B., et al. Prevalence and factors associated with HIV and syphilis infection among children aged 0-36 months in Kilimanjaro, Tanzania: a community-based cross-sectional study. *Trop Med Health.* 2019 Nov 21; 47: 53.
  22. MacDonald D. Taurodontism. *Oral Radiol.* 2019 Apr 12.
  23. Giambersio E., Barile V., Giambersio A. M. Klinefelter's syndrome and taurodontism. *Arch Ital Urol Androl.* 2019 Jul 2; 91 (2).
  24. Haghanifar S., Moudi E., Abesi F., Kheirkhah F., Arbabzadegan N., Bijani A. Radiographic Evaluation of Dental Anomaly Prevalence in a Selected Iranian Population. *J Dent (Shiraz).* 2019 Jun; 20 (2): 90-94.
  25. Choi S. J., Lee J. W., Song J. H. Dental anomaly patterns associated with tooth agenesis. *Acta Odontol Scand.* 2017 Apr; 75 (3): 161-165.
  26. Al-Abdallah M., AlHadidi A., Hammad M., Al-Ahmad H., Saleh R. Prevalence and distribution of dental anomalies: a comparison between maxillary and mandibular tooth agenesis. *Am J Orthod Dentofacial Orthop.* 2015 Nov; 148 (5): 793-8.
  27. Adam M. P., Banka S., Bjornsson H. T., Bodamer O., Chudley A. E., Harris J., et al. Kabuki syndrome: international consensus diagnostic criteria. *J Med Genet.* 2019 Feb; 56 (2): 89-95.
  28. Wang Y., Li N., Su Z., Xu Y., Liu S., Chen Y., et al. The phenotypic spectrum of Kabuki syndrome in patients of Chinese descent: A case series. *Am J Med Genet A.* 2019 Dec 28.
  29. Ruault V., Corsini C., Duflos C., Akouete S., Georgescu V., Abaji M., et al. Growth charts in Kabuki syndrome 1. *Am J Med Genet A.* 2019 Dec 26.
  30. Wang Y. R., Xu N. X., Wang J., Wang X. M. Kabuki syndrome: review of the clinical features, diagnosis and epigenetic mechanisms. *World J Pediatr.* 2019 Dec; 15 (6): 528-535.



Attribution (BY-NC) - (BY) You must give appropriate credit, provide a link to the license, and indicate if changes were made. You may do so in any reasonable manner, but not in any way that suggest the licensor endorses you or your use. (NC) You may not use the material for commercial purposes.