

Endovascular Repair of Aortic Recoarctation and Thoracic Aortic Pseudoaneurysm

Aortic coarctation is a congenital defect characterized by stenosis of the aortic lumen typically located at the region of the ligamentum arteriosum. This narrowing is usually localized, but may involve other segments of the aorta such as the aortic arch and –less common– the abdominal aorta. Usually, there is significant variation in the degree of stenosis, extent of the disease and clinical manifestations, associated with extensive collateral circulation.

It accounts for 5–7% of all congenital heart defects, with an incidence of 3 per 100,000 live births. (1) Open surgery continues to be the gold standard of treatment due to lower risk of reintervention. (2)

The endovascular approach has emerged as a feasible and less invasive option in selected cases. Major surgical and endovascular advances have impacted positively on survival rate. (3) Today, given the expected longevity of this population, long term complications have been increasing. The most critical ones are aortic recoarctation and aortic aneurysm/pseudoaneurysm.

In the case of late complications, open surgery or endovascular repair are under discussion. Each approach has associated benefits and drawbacks, and should be evaluated individually when deciding on the optimal treatment plan for each patient.

This is the case of a 78-year-old man with a history of hypertension –difficult to manage with five drugs–, dyslipidemia, ex-smoker, hypothyroidism, and surgery for aortic coarctation when he was 17 years old.

At the age of 65 years, the patient progressed to severe bicuspid aortic stenosis, associated with ascending aorta dilation and severe coronary artery disease, so a mini-root surgery with stentless Toronto valve (biological valve) combined with myocardial revascularization (vein bypasses to descending anterior and diagonal coronary arteries) was carried out.

No arterial bypasses were performed due to disease in both internal mammary arteries secondary to evident longstanding recoarctation. On admission, the patient was anticoagulated with rivaroxaban due to chronic atrial fibrillation.

The reason for his hospitalization was an intermittent claudication in the last months, progressing to pain after walking a few meters. Lab tests confirmed severe anemia associated with kidney failure. The patient reported having had an accident a few months before, with significant blood loss due to epistaxis. After optimizing the lab panel with hydration and transfusions, a CT angiography of the chest, abdomen, and pelvis was performed (Figure 1). The study revealed the ascending aortic replacement with the valved conduit and aortic recoarctation of 22 mm length and 6 mm diameter in the proximal third of the descending aorta, immediately posterior to the origin of the left subclavian artery, associated with anastomotic pseudoaneurysm.

The maximum diameter of the ascending aorta was 34 mm, and the supra-aortic vessels were normal, ectatic and patent. The maximum diameter of the descending aorta was 25 mm. The echocardiography confirmed preserved diameters and biventricular function, concentric left ventricular hypertrophy, left atrial enlargement, mitral regurgitation, and bioprosthesis in aortic position with normal function.

Endovascular repair of recoarctation was indicated. For strategy optimization, a reconstruction and 3D printing model of the pathological aorta was performed (Figure 1).

The procedure was carried out under neuroleptanalgesia, with continuous central monitoring of differential pressure and a rapid pacemaker during stent placement. An AltoSa-XL-Gemini Balloon Catheter of 18 mm diameter and 50 length (AndraTec GmbH, Koblenz, Germany) was used over which a self-expandable covered Andrastent 48XL stent (PTFE-tube covered cobalt-chromium stent with semi-open cell design, AndraMed GmbH, Reutlingen, Germany) was mounted. Once deployed, a control angiography was performed and differential arterial pressures were recorded in pull back. The covered stent was placed in the correct position, and the previous gradient of 60 mmHg was reduced to 15 mmHg (Figure 2).

The patient was discharged three days after surgery with no antihypertensive drugs and with normal kidney function. At present, he walks three kilometers a day without claudication.

Indications for surgery on a patient with recoarctation are the same as those for the native disease. Those indications include a transcoarctation pressure gradient >20 mmHg, persistent hypertension not attributable to other causes, radiological evidence of clinically significant collateral flow, heart failure associated with coarctation, or disabling intermittent claudication. (2) Although severe anemia may have been the precipitating factor of this patient's symptoms of claudication, management of blood pressure was difficult, as he was taking five antihypertensive drugs.

Aneurysm or pseudoaneurysm is usually found distal

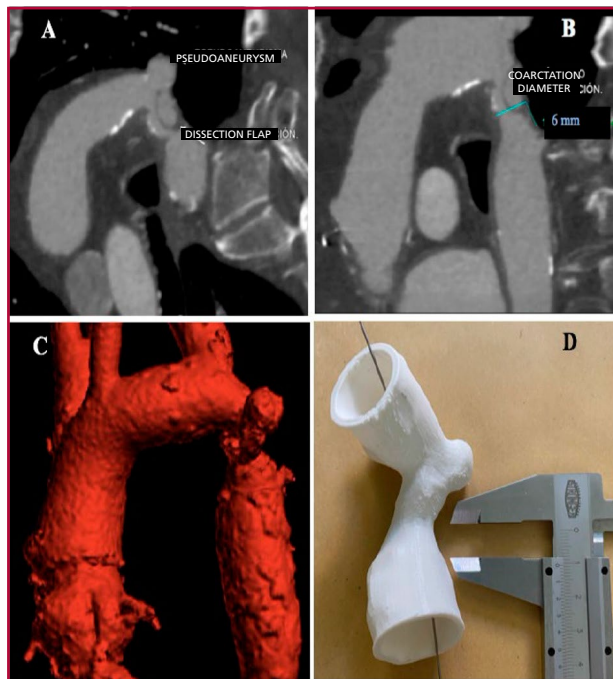


Fig. 1. A-B: Sagittal section of CT angiography showing pseudoaneurysm, dissection flap and diameter of aortic coarctation. C-D: 3D reconstruction of aortic coarctation associated with pseudoaneurysm.

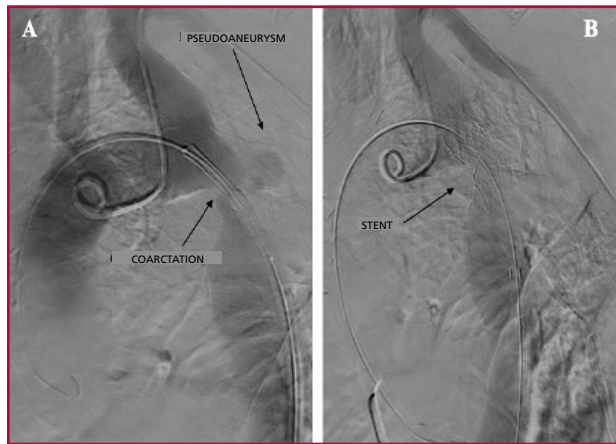

Fig. 2. Digital angiography - Sagittal incidence A: Before stent deployment. B: After stent deployment.

to or at the site of primary repair, and can develop with or without concomitant recoarctation. In our patient, a small pseudoaneurysm was observed at the recoarctation site.

Endovascular repair is the treatment of choice for recoarctation, regardless of patient age. (4) This recommendation is based on data showing a significant increase in mortality from reintervention rather than from native repair, 3% versus < 1%, respectively. (5)

Angioplasty with stent is the most common procedure. However, stent placement in adolescents and children would not be standard for recoarctation due to risk of mismatch secondary to growth. (4) Technical success of stenting in recoarctation is usually close to 99%. (6)

Even though it is a safe procedure, associated complications are similar to any stenting procedure (dissection or rupture, endoleak, arterial thromboembolism, stent migration, graft infection, paraplegia secondary to spinal cord ischemia, and acute coronary syndrome). (5) In our patient, after a successful angioplasty, the neck of the pseudoaneurysm was covered with a single stent, normalizing blood pressure and kidney function, and allowing the patient to walk again without pain.

While there is no current evidence to account for the preferential use of covered, straight or conical stents, they should be readily available to treat possible aortic rupture immediately. In patients with symptomatic recoarctation and adequate anatomy, a first endovascular approach seems to be the most beneficial.

Conflicts of interest

None declared.

(See authors' conflicts of interest forms on the website/ Supplementary material).

Ethical considerations

Not applicable.

José M. Álvarez Gallesio¹, Mariano Ferreira¹,
Patricio Giménez Ruiz¹, Michel David¹,
Guillermo Migliaro², José A. Álvarez²

¹ Department of Cardiac Surgery.

² Interventional Cardiology.

Herzzentrum, Hospital Alemán, Buenos Aires

e-mail: jalvarezgallesio@gmail.com

REFERENCES

- Riambau V, Böckler D, Brunkwall J, Cao P, Chiesa R, Coppi G, et al. Editor's Choice-Management of Descending Thoracic Aorta Diseases: Clinical Practice Guidelines of the European Society for Vascular Surgery (ESVS). *Eur J Vasc Endovasc Surg* 2017;53:4-52. <https://doi.org/10.1016/j.ejvs.2016.06.005>
- Brown ML, Burkhart HM, Connolly HM, Dearani JA, Cetta F, Li Z, et al. Coarctation of the aorta: lifelong surveillance is mandatory following surgical repair. *J Am Coll Cardiol* 2013;62:1020-5. <https://doi.org/10.1016/j.jacc.2013.06.016>
- Babu-Narayan SV, Mohiaddin RH, Cannell TM, Muhll IV, Dimopoulos K, Mullen M, et al. Cardiovascular changes after transcatheter endovascular stenting of adult aortic coarctation. *Int J Cardiol* 2011;149:157-163 <https://doi.org/10.1016/j.ijcard.2009.12.025>
- Stout KK, Daniels C, Aboulhosn JA, Bozkurt B, Broberg CS, Coleman JM, et al. 2018 AHA/ACC guideline for the management of adults with congenital heart disease: executive summary: a report of the American College of Cardiology/American Heart Association Task Force on clinical practice guidelines. *J Am Coll Cardiol*. 2019;73:1494-563 <https://doi.org/10.1161/CIR.0000000000000602>
- Kron IL, Flanagan TL, Rheuban KS, Carpenter MA, Gutgesell HP Jr, Blackburne LH, et al. Incidence and risk of reintervention after coarctation repair. *Ann Thorac Surg*. 1990;49:920-5 discussion 925-6. [https://doi.org/10.1016/0003-4975\(90\)90867-6](https://doi.org/10.1016/0003-4975(90)90867-6)
- Feltes TF, Bacha E, Beekman RH 3rd, Cheatham JP, Feinstein JA, Gomes AS, et al. Indications for cardiac catheterization and intervention in pediatric cardiac disease: a scientific statement from the American Heart Association. *Circulation*. 2011;123:2607-52. <https://doi.org/10.1161/CIR.0b013e31821b1f10>

Rev Argent Cardiol 2019;87:455-456.

<http://dx.doi.org/10.7775/rac.v88.i5.18792>

Aortic Recoarctation Associated with Type-B Aortic Dissection. Impossibility of Endovascular Treatment

The rate of aortic recoarctation in patients operated in childhood ranges from 3.1% to 15%. (1) Some studies suggest that it is due to residual coarctation, resulting in a proximal blood pressure difference >20 mm Hg. This causes recurrent systemic hypertension, which together with bicuspid aortic valve disease, significantly increases preoperative morbidity and mortality. (2)

Endovascular repair is the first-line therapeutic option in some centers, either alone or combined with traditional surgical treatment. (3) However, in some cases the endovascular approach is not feasible, and a full surgical strategy and approach are required. We describe a case of aortic recoarctation associated with Stanford Type-B acute aortic dissection.

Stage 1

In June 2011, a 50-year-old female patient with a history of aortic coarctation repair in childhood and no history of coronary artery disease, consulted for piercing chest pain. The electrocardiogram (ECG) was normal and the transthoracic echocardiography (TTE) showed preserved left ventricular function, bicuspid aortic valve and moderate aortic regurgitation.

A computed tomography angiography (angio-CT) revealed aortic recoarctation distal to the left subcla-

vian artery, associated with a descending dissecting aortic aneurysm (52 mm) reaching the flap up to both iliac arteries, with preserved visceral flows (Figure 1A).

The endovascular option was ruled out due to aortic angulation of 90° in the distal aortic arch and to post-coarctation hypoplasia (Figure 1B).

The emergency surgery consisted of a posterolateral thoracotomy through the fifth intercostal space, extending to the abdomen. Once the skin incision was made, a double entrance to the thorax was used at the level of the sixth and the fourth intercostal spaces. Cannulation for cardiopulmonary bypass (CPB) was through the femoral artery, and the venous entry with a long 25 French Medtronic® cannula. The aortic arch and descending aortic aneurysm were dissected. Proximal clamping of the aortic arch was performed between the left carotid artery and the left subclavian artery, which was separately occluded with a balloon.

The aorta was distally clamped at the level of the diaphragm. The proximal end-to-end anastomosis was made with a #24 Dacron graft, in oblique position, at the same level of the left subclavian artery. Once the anastomosis was completed, the clamp was distally transferred to the distal graft to allow flow in the vertebral artery and improve spinal circulation. At a temperature of 32 °C, CPB was briefly stopped, the lower clamp was removed, and a Foley catheter was inserted into the abdominal aorta (Figure 2A); then, CPB was restarted, and open distal end-to-end anastomosis was performed, applying the distal flap (Figure 2B).

The postoperative course in the Cardiac Intensive Care Unit (CICU) was uneventful; the patient was extubated 48 hours later, and was discharged after 10 days. Angio-CT scan at 30 days confirmed persistent distal dissection flap with no visceral involvement, and a 43-mm abdominal aortic aneurysm.

Stage 2

Progression of the abdominal aortic aneurysm to 54 mm diameter was confirmed in May 2013. (Figure 3A). Given the configuration of the dissection flap and the involvement of both visceral vessel lumens, endovascular repair was not possible. Preservation of the intermediate aortic segment between the celiac trunk and both renal arteries (39 mm diameter) was decided. The approach was a xiphopubic laparotomy, with clamping in the intermediate infrarenal segment, and the infrarenal aorto-bi-iliac replacement was performed with an 18 x 9 mm Dacron graft. The postoperative course was uneventful and the patient was discharged 6 days after surgery. A year later, the patient was asymptomatic; angio-CT scan detected patent supra-aortic visceral vessels and aorto-bi-iliac bypass, in addition to non-dilated residual descending aorta and dissection flap with no visceral involvement (Figure 3B).

Aortic dissection in the context of aortic recoarctation is a rare entity. Very few reports document the

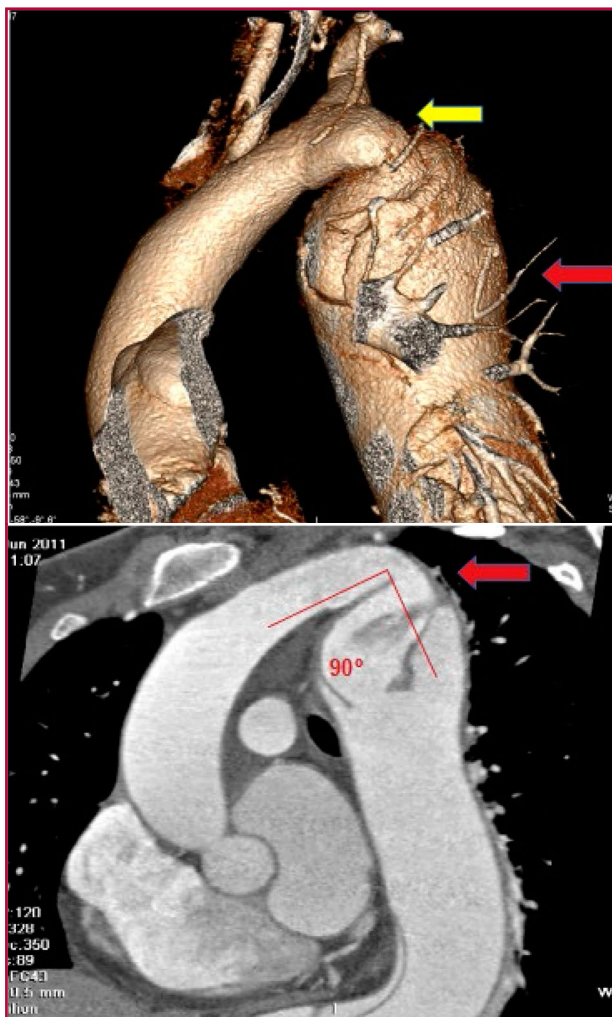


Fig. 1. A. Preoperative 3D angio-CT reconstruction (Stage 1) depicting aortic recoarctation (yellow arrow) and descending dissecting aortic aneurysm (52 mm) (red arrow). B. Preoperative angio-CT scan (Stage 1) showing aortic recoarctation with 90° angulation in the distal aortic arch and post-coarctation hypoplasia (red arrow).

combination with a Type-B dissection. (4) It probably occurs due to high pressure proximal to the coarctation, or often after an angioplasty attempt. (5)

In this case, the patient had a bicuspid aortic valve and degenerative pathological findings in the aortic wall that, in combination with post-stenosis dilation of the descending aorta, was a predisposing factor for Type-B dissection. (6)

At present, there is no consensus on the joint treatment of the two entities. Although endovascular repair has taken center-stage in recent years, (7) this approach is not possible for a subgroup of patients who must be surgically treated, with risk of complications such as spinal or mesenteric ischemia, stroke, and acute renal failure. (8)

In the resolution of this case, the following strategies stand out in the first stage: a) the choice of the approach through the same incision and the opening

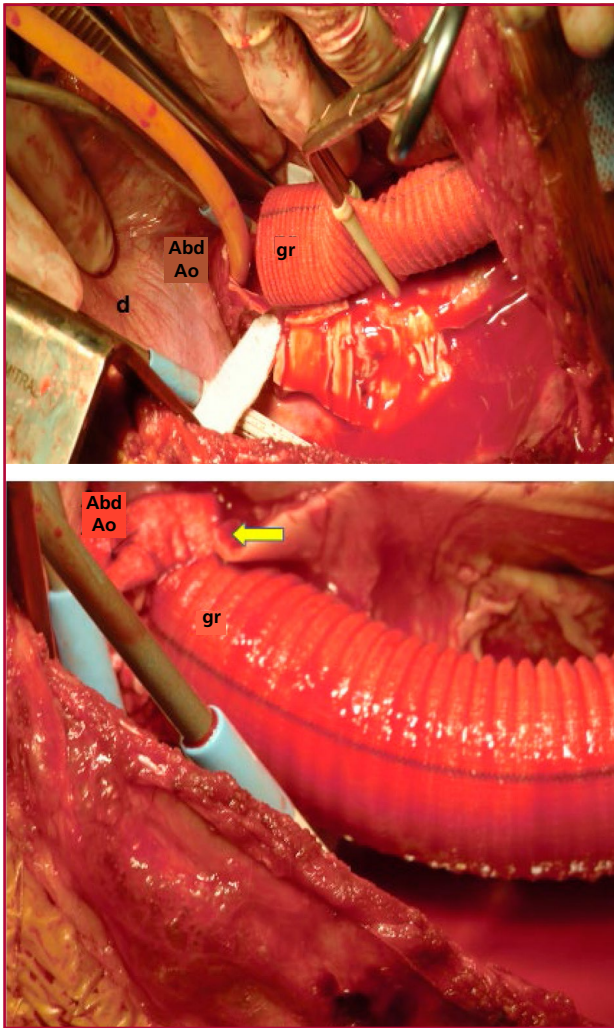


Fig. 2. A. Surgical image (Stage 1) showing distal aortic anastomosis graft (gr) at the level of the diaphragm (d) and distally transferred clamping and Foley catheter placement into the abdominal aorta (Abd Ao) for distal anastomosis. **B.** Surgical image (Stage 1): Completed open distal anastomosis between the Dacron graft and the abdominal aorta (yellow arrow).

of two different intercostal spaces, providing good exposure of the aortic arch and the descending aortic aneurysm at the level of the diaphragm, admitting supraceliac aortic cross-clamping; b) peripheral cannulation that allowed unloading the heart at 32 °C maintaining cerebral perfusion, and peripheral perfusion through CPB; c) the decision to perform open distal anastomosis due to fragile distal segment, by placing a Foley catheter that allowed maintaining visceral and spinal cord perfusion at the infradiaphragmatic level, with the resulting benefit in the postoperative period.

In the second stage, it is worth mentioning the decision to preserve the intermediate aortic segment –surrounded by the celiac trunk, the superior mesenteric artery and both renal arteries–. As it had uninvolved vascular flow, it was possible to perform

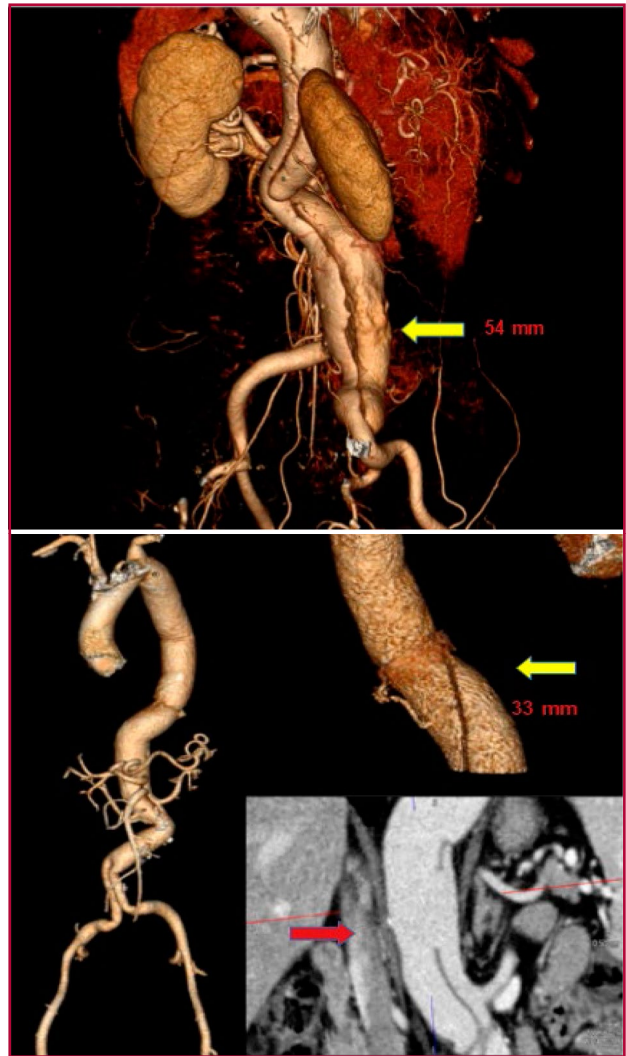


Fig. 3. A. Preoperative 3D angio-CT reconstruction (Stage 2) showing the dissection flap and the infrarenal abdominal aortic (54 mm) and right iliac aneurysm (yellow arrow) **B.** Postoperative 3D angio-CT reconstruction (Stage 2) illustrating the final result, with descending aorta (33 mm) (yellow arrow) and residual dissection flap of the abdominal aortic segment, with preserved patency of the visceral arteries (red arrow).

abdominal aortic replacement up to both iliac arteries. It simplified the surgical strategy and operative time, and reduced morbidity and mortality rates. We reported the surgical repair of a complex case of aortic recoarctation in combination with Type-B dissection.

The surgical treatment was possible due to an adequate two-stage strategy that provided an angiographic solution in the acute stage, and avoided the risks of spinal and visceral ischemia, and stroke, resulting in a practical solution for the subsequent chronic stage.

Conflicts of interest

None declared.

(See authors’ conflicts of interest forms on the website/ Supplementary material).

Ethical considerations

Not applicable

**Ronald M. Estrada¹, Roberto Battellini¹,
Ricardo Marenchino¹, Martin Rabellino²,
Vadim Kotowicz¹**

¹ Department of Cardiac Surgery

² Imaging Division,

Hospital Italiano de Buenos Aires

E-mail: ronaldm.estrada@hospitalitaliano.org.ar

REFERENCES

1. Presbitero P, Demarie D, Villani M, Actis Perinetto E, Riva G, Orzan F, et al. Long term results (15 to 30 years) of surgical repair of aortic coarctation. *Br Heart J* 1987;57:462–7. <https://doi.org/10.1136/hrt.57.5.462>
2. Jenkins NP, Ward C. Coarctation of the aorta: natural history and outcome after surgical treatment. *Ann Int J Med* 1999;92:365–71. <https://doi.org/10.1093/qjmed/92.7.365>
3. Rothman A. Interventional therapy for coarctation of the aorta. *Curr Opin Cardiol* 1998;13:66–72. <https://doi.org/10.1097/00001573-199801000-00011>
4. Yamaguchi A, Adachi H, Kamio H, Murata S, Okada M, Adachi K, et al. A combination of preductal aortic coarctation and type B dissection: report of a case. *Surg Today* 1998;28:435–7. <https://doi.org/10.1007/s005950050159>
5. Beitzke A, Stein JI, Gamillscheg A, Rigler b Dissection of the descending aorta after balloon angioplasty of native coarctation. *Ped Cardiol* 1997;18:222–5. <https://doi.org/10.1007/s002469900156>
6. Edwards WD, Leaf DS, Edwards JE. Dissecting aortic aneurysm associated with congenital bicuspid aortic valve. *Circulation* 1978;57:1022–52. <https://doi.org/10.1161/01.CIR.57.5.1022>
7. Yetman AT, Nykanen D, McCrindle BW, Sunnegardh J, Adatia I, Freedom RM, et al. Balloon angioplasty of recurrent coarctation: a 12 year review. *J Am Coll Cardiol* 1997;30:811–6. [https://doi.org/10.1016/S0735-1097\(97\)00228-3](https://doi.org/10.1016/S0735-1097(97)00228-3)
8. Shin JS, Sun K, Shim WJ, Kim KT, Kim HM. Acute descending aortic dissection associated with coarctation in adult. *Asian Cardiovasc Thorac Ann* 2002;10:354–5. <https://doi.org/10.1177/02184923021000420>

Rev Argent Cardiol 2020;88:456-459.
<http://dx.doi.org/10.7775/rac.v88.i5.18794>

Postcardiac Injury Syndrome Secondary to Thoracic Trauma

Traumatic chest wall injuries proximal to the heart can be fatal, and identifying cardiac involvement is critical for the management of affected patients. Pericarditis secondary to pericardial injury constitutes the postcardiac injury syndrome, which includes post-infarction pericarditis or Dressler syndrome, post-pericardiotomy syndrome and post-traumatic pericarditis due to either iatrogenic or accidental injury, resulting in pericardial effusion. It was decided to call this presentation “postcardiac injury syndrome”, as it is more inclusive, since the initial injury may occur both in the myocardium as in the pericardium. (1)

We report the case of a 44-year-old male athlete, with a history of closed left lateral thoracic trauma and rib fracture while playing soccer 45 days before consultation. The patient presented with continuous abdominal pain radiating to the chest, a 4-day history of progressive dyspnea, 39 °C fever, and without bac-

teremia in the previous 24 hours.

The physical examination was within normal limits; the patient was lucid, with BP: 100/70 mmHg, HR: 90 bpm, RR: 18 per minute, T° 36°C and 2/3 jugular venous distention without inspiratory collapse. Pulsus paradoxus was not detected. Muffled S1 and S2, pericardial friction rub. Soft tender abdomen.

Chest x-ray revealed 11 left rib fracture (Figure 1).

ECG: Sinus rhythm, 75 bpm; axis 100 degrees. CRBBB. Diffuse repolarization disorders in the anterior wall.

Lab tests: White blood cell count: 12000/mm³, Red blood cell count: 3600000/mm³, Hct: 36%, Platelets: 241000/mm³, Erythrocyte sedimentation rate: 96 mm/h, C-reactive protein: 26 mg/L, Glycemia: 116 mg/dl, Urea: 30 mg/dl, Creatinine: 0.85 mg/dl, LDH: 318 IU/L, Na: 135 mEq/L, K: 4 mEq/L, GOT: 36 U/L, GPT: 37 U/L, ALP: 334 U/L, Total bilirubin: 2.34 mg/dl, Direct bilirubin: 1.41mg/dl, Indirect bilirubin: 1.41 mg/dl, Troponin I: < 0.010 ng/ml, CPK: 68 U/L, CPK-MB: 2 ng/dl, Pro-BNP: 187 pg/ml, HIV: non-reactive

Due to severe pericardial effusion associated to the progression of symptoms, a pericardiocentesis was performed, reporting bloody red cloudy fluid, with abundant red blood cells, leukocytes 210 cells/mm³ (neutrophils 60%, lymphocytes 40%), PH: 7.5, proteins: 3.9 g, glucose: 1.33 g/l, uric acid: 2.8 mg/dl, and LDH: 1347 IU/L. Negative culture for common germs, BAAR and fungi. Negative autoimmune profile. The pathology report indicated no evidence of neoplastic cells.

It was interpreted as a late postcardiac injury syndrome after thoracic trauma, and colchicine 1 mg every 12 hours and aspirin 1 g/day administration was initiated.

The patient was discharged, and remained asymptomatic 30 days after treatment onset.

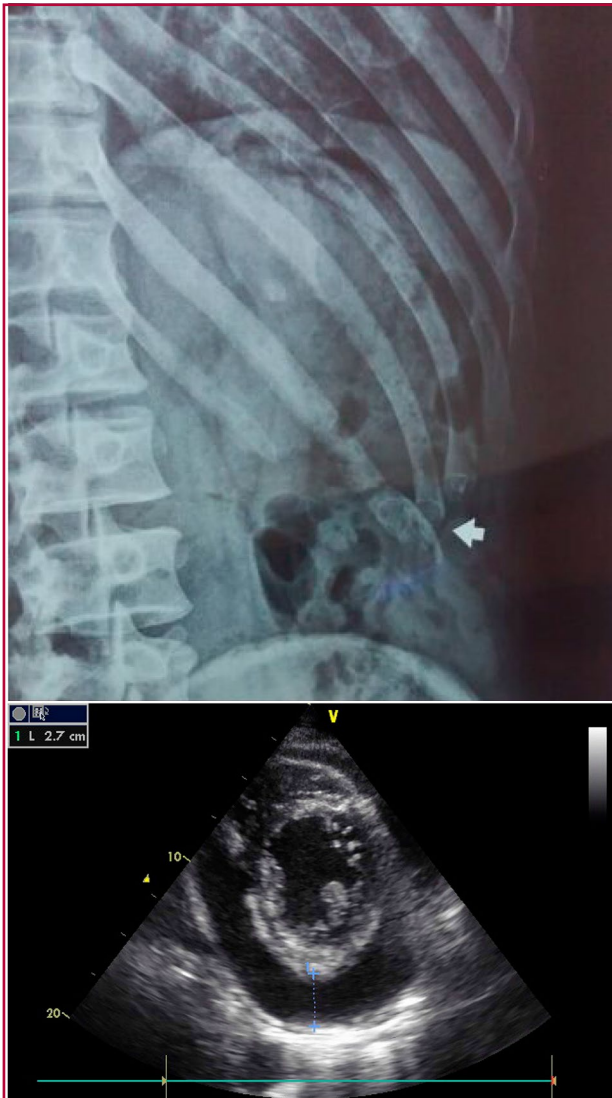Follow-up echocardiography showed minimal fluid in the pericardium and absence of inspiration/expiration variations in the transmitral flow.

The exact incidence of postcardiac injury syndrome is unknown, probably due to its heterogeneous spectrum. When grouped with other causes of pericarditis with similar pathophysiology, it may account for up to 10% of pericarditis cases that progress to pericardial effusion. (2)

It is believed that damage to pericardial or pleural mesothelial cells in combination with blood entering the pericardial space represents the initial trigger of postcardiac injury syndrome. (3)

There is evidence for a correlation between elevated antimyocardial antibody titers and the incidence of post cardiac surgery syndrome.

Based on these observations and insights from pathophysiological animal models, we therefore hypothesize that release of cardiac antigens, together with non-specific activation of the innate immune system, initiates a T-cell response and recruitment of in-



Doppler echocardiography: Severe pericardial effusion and transmitral flow variation >30% in inspiration and expiration.

Fig. 1. ECG: Sinus rhythm, 75 bpm; axis 100 degrees. CRBBB. Diffuse repolarization disorders in the anterior wall.

inflammatory cells.

The latency period between cardiac injury and post-cardiac injury syndrome, as well as the generally favorable response to anti-inflammatory drugs, strongly support the hypothesis of an autoimmune-mediated pathogenesis. (4)

Most patients with postcardiac injury syndrome present with chest pain, fever, and dyspnea.

Lab tests show elevated inflammation markers and leukocytosis. (5)

In the initial evaluation of these patients, echocardiography is crucial and should be performed early.

The diagnosis should be suspected when findings are detected after a period of latency following a cardiac trauma.

Therapeutic decisions should be made carefully, given the possible side effects and risks associated with

non-steroidal anti-inflammatory drugs and colchicine in cardiac patients which may be cursing a recent invasive procedure. Simple postoperative pericardial effusions with no evidence of systemic inflammation do not justify treatment.

Aspirin is the first option, with doses varying between 750 and 1000 mg every 6 or 8 hours. A treatment period of 1 or 2 weeks before a gradual decrease is usually enough. A retrospective study showed that colchicine along with non-steroidal anti-inflammatory drugs was more effective than anti-inflammatory agents (OR 0.43- 0.95-0.99). (6)

A minority of patients with contraindications for non-steroidal anti-inflammatory drugs or colchicine, or with refractory symptoms, may receive prednisolone 0.25 to 0.5 mg/kg/day.

We reported the case of a healthy patient who developed severe pericardial effusion 45 days after a rib fracture, which was confirmed by puncture of a bloody exudate, after ruling out secondary causes. An anti-inflammatory treatment was started with positive outcome.

Conflicts of interest

None declared.

(See authors' conflicts of interest forms on the website/ Supplementary material).

Ethical considerations

Not applicable

Pablo Courtade Iriarte,
Claudio Efraín López, Nicomedes Carranza,
Pablo Etchevery, Mariana Lucía Arguello

Centro de Medicina Integral del Comahue.
School of Medicine, Universidad Nacional del Comahue
e-mail: pcourtadeiriarte@gmail.com

REFERENCES

- Soto M, Romero N, Wills B, Pinzón B, Jiménez JC. Pericarditis post traumática como manifestación del síndrome de lesión post cardíaca. *Rev Colomb Cardiol* 2016;23:229. <http://dx.doi.org/10.1016/j.rcar.2015.02.009>
- Imazio M, Spodick DH, Brucato A, Trincherio R, Adler Y. Controversial issues in the management of pericardial disease. *Circulation* 2010;121:916-28. <http://dx.doi.org/10.1161/CIRCULATIONAHA.108.844753>
- Tabatznik B, Isaacs JP. Postpericardiectomy syndrome Following minimally invasive coronary artery By Pass. *J Emerg Med* 1998;16:737-9.
- Eriksson U, Sasse T. Post-cardiac injury syndrome: aetiology, diagnosis, and treatment. *E-Journal of Cardiology Practice* 2017;15(21)31 Oct 2017
- Imazio M, Hoit BD. Post cardiac injury syndrome. An emerging cause of pericardial diseases. *Int J Cardiol* 2013;168:648-52. <http://dx.doi.org/10.1016/j.ijcard.2012.09.052>
- Alraies MC, Jaroudi W Al, Shabrang C, Yarmohammadi H, Klein AL, Tamarappoo BK. Clinical features associated with adverse events in patients with post-pericardiotomy syndrome following cardiac surgery. *Am J Cardiol* 2014;114:1426-30. <http://dx.doi.org/10.1016/j.amjcard.2014.07.078>

Abdominal Aortic Aneurysm in Marfan Syndrome

Marfan syndrome is a connective tissue disorder that usually affects the skeletal, ocular, and cardiovascular systems. (1) Most cardiovascular manifestations emerge in the thoracic aorta, mainly in the aortic root, as an aneurysm or dissection, and are the main cause of morbidity and mortality for this systemic disease.

Abdominal aortic aneurysm is a rare location of initial presentation or during progression of patients with Marfan syndrome, with isolated reports or series of few cases in the literature. (2-5)

We report the case of a 38-year-old woman, smoker, with a diagnosis of Marfan syndrome, retrognathia, dolichocephaly, arachnodactyly, wrist sign on physical examination, arthrodesis due to scoliosis, and a family history of sudden death of her father at the age of 40 years.

She was medicated with atenolol, topiramate, and amitriptyline for migraine. During a checkup with her cardiologist, a pulsatile tumor was detected in the left abdominal region corresponding to an abdominal aortic aneurysm of 75 mm diameter. A CT angiography of the thoracic, abdominal and iliac aorta showed a 47-mm aortic root enlargement in its sinus portion with no signs of dissection and preserved size of the aortic arch and the descending aorta.

The CT scan in Figure 1 shows the fusiform aneurysm of the infrarenal abdominal aorta with a maximum diameter of 77 mm, uncomplicated and with no mural thrombus. The echocardiogram revealed a left ventricle (LV) with 44-mm left ventricular diastolic dysfunction (LVDD), 8-mm interventricular septal (IVS) thickness and 65% ejection fraction. The aortic valve was tricuspid, with normal function, and the aortic root diameters were: ring 27 mm, sinus 43.5 mm (Z-score 4.95), and tubular 34 mm.

Considering the patient's age, low surgical risk, vascular anatomy and pathophysiology of the aneurysm, conventional surgery was the treatment of choice; and an infrarenal aorto-aortic replacement was performed with a Dacron tube graft. After an uneventful course, the patient was discharged 6 days after surgery. The histopathological study of the abdominal aortic wall showed rupture and loss of elastic fibers, with reduction of the muscle wall replaced by a basophilic myxoid matrix, evidencing vascular changes consistent with Marfan syndrome.

Three weeks after surgery, the patient consulted for functional class-III dyspnea, systodiastolic murmur at the aortic focus (de novo) and signs of heart pump failure. The patient was hospitalized and an echocardiography showed preserved LV diameters and acute dissection flap with flow inside in the ascending aorta and aortic arch associated with severe aortic regurgitation with eccentric jet to the mitral valve and mild pericardial effusion.

CT angiography confirmed Stanford type-A dissection with a 49 × 56 mm aneurysmatic sac at the

level of the ascending aorta, and moderate right pleural effusion. Emergency surgery was performed with ascending aorta replacement with a Dacron graft and aortic valve repair. Postoperative echocardiography showed adequate aortic valve function with mild central aortic regurgitation and mild anterior mitral leaflet prolapse. The patient made good progress and was discharged on the 7th day.

Marfan syndrome is a genetic disorder of the connective tissue, inherited in an autosomal dominant pattern. (1) The disease is characterized by a heterogeneous clinical presentation mainly in the skeletal, ocular and cardiovascular systems, requiring a multidisciplinary approach to confirm the diagnosis and treatment. Cardiovascular complications are the most critical because of their potentially fatal consequences, and are responsible for the poor life expectancy of patients with Marfan syndrome. (2, 3, 6)

In this disease, the congenital fragility of the aortic wall shows decreased elastin content and fragmentation of elastic fibers, leading to cystic necrosis of the aortic media, with dissection and aneurysmal lesions.

In most patients with Marfan syndrome the thoracic aorta is the most affected segment, mainly in the aortic root; sometimes, it is associated with aortic and mitral valve disease, while aneurysms and dissections in other locations are rare. Abdominal aortic aneurysm is rare in patients with Marfan syndrome. (2-5) Takayama et al. (2) were able to recruit 6 patients with Marfan syndrome and abdominal aortic aneurysm as initial presentation over a period of 32 years, and Hagerly et al. (3) reviewed 12 cases from the same health center in a 20-year period. In 2020, in an analysis of 301 cases with Marfan syndrome, Aranson et al. (6) describe only 6 patients (1.9%) with abdominal aortic aneurysm requiring surgical treatment, but all of them had a history of some kind of surgery on the thoracic aorta. The 2010 revised Ghent nosology, (1) currently applicable, which describes uniform diagnostic criteria, does not even include lesions in the abdominal aorta and focuses only on the aortic root size in Marfan syndrome diagnosis, as opposed to the 1988 Berlin nosology and the 1996 Ghent nosology, where the abdominal aortic aneurysm was considered a minor diagnostic criterion in patients with suspected Marfan syndrome.

Risk factors for abdominal aortic aneurysm in Marfan syndrome are poorly understood, but Hagerly et al. (3) described in their series that more than 90% of patients had undergone previous aortic root replacement, 75% were smokers (a known risk factor for aneurysms), and more than 50% had aneurysms in other arterial branches.

Abdominal aortic aneurysms occur in young patients with Marfan syndrome at an average age of 44 years, as opposed to atherosclerotic abdominal aortic aneurysms in the non-Marfan general population that are typical in patients over 65 years. (2, 3) Another feature in patients with Marfan syndrome and abdom-

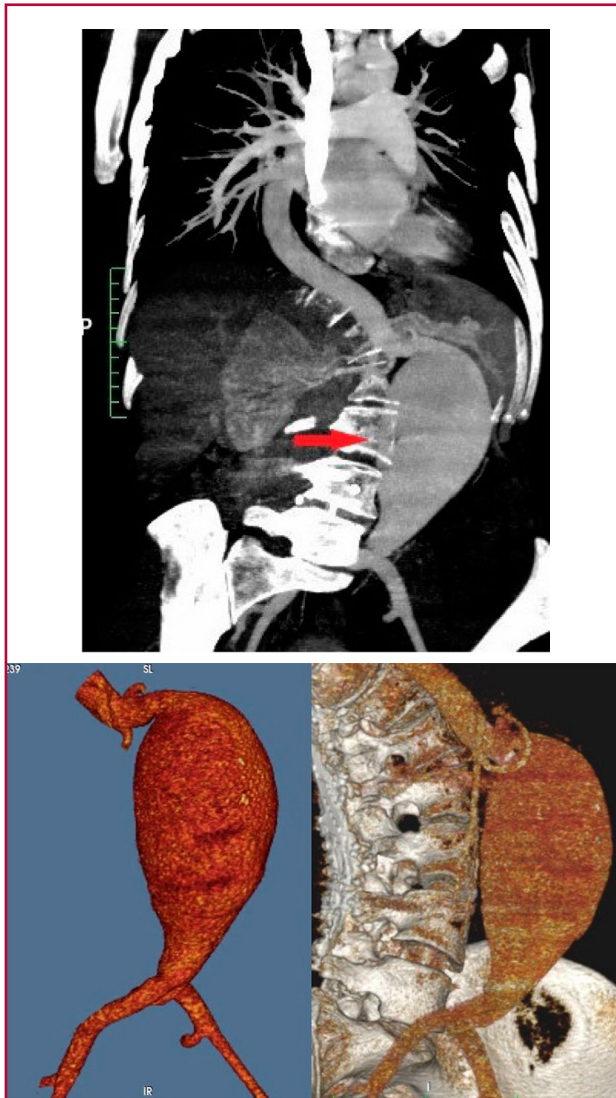


Fig. 1. A & B. CT angiography showing infrarenal abdominal aortic aneurysm of 77 mm with no mural thrombus and normal iliac arteries

inal aortic aneurysm is that they rarely show mural thrombus or intimal calcification in the aortic wall. (2)

The need for emergency surgery in abdominal aortic aneurysms in patients with Marfan syndrome is 33-50% (2, 6), partly because aneurysms develop rapidly without being detected, and are usually diagnosed when they are large, with an average diameter of 50 or 76 mm depending on the series. (2, 3) In addition, abdominal aortic aneurysms in Marfan syndrome tend to rupture, even if small, with rupture reports at only 30 mm diameter. (2)

Aranson et al. (6) studied 174 patients with Marfan syndrome and cardiovascular surgery, and concluded that patients undergoing multiple interventions had significant survival disadvantage at one and 10 years.

In conclusion, abdominal aortic aneurysm is rare in Marfan syndrome, but routine imaging of abdomi-

nal aortic size should be performed mainly in patients with a history of aortic root surgery or arterial branch aneurysms, and in smokers.

Conflicts of interest

None declared.

(See authors' conflicts of interest forms on the website/ Supplementary material).

Ethical considerations

Not applicable

**Mariano Norese¹, Hernán Chen¹,
Sergio Ferreyra Fernández¹, Augusto Meretta²
Adrián Alberto Charask², Carlos Barrero²**

¹ Department of Cardiovascular Surgery.

² Department of Cardiology.

Clínica Bazterrica, Juncal 3002 (1425),

Ciudad Autónoma de Buenos Aires

E-mail: marianonorese@hotmail.com

REFERENCES

1. Loeys BL, Dietz HC, Braverman AC, et al. The revised Ghent nomenclature for the Marfan syndrome. *Journal of Medical Genetics* 2010; 47:476-485. <http://dx.doi.org/10.1136/jmg.2009.072785>
2. Takayama T, Miyata T, Nagawa H. True abdominal aortic aneurysm in Marfan syndrome. *J Vasc Surg* 2009;49(5):1162-1165. <http://dx.doi.org/10.1016/j.jvs.2008.12.007>
3. Hagerty T, Geraghty P, Braverman AC. Abdominal Aortic Aneurysm in Marfan Syndrome. *Ann Vasc Surg* 2017; 40:294. e1-294.e6. <http://dx.doi.org/10.1016/j.avsg.2016.07.067>
4. Pedersen MW, Huynh KD, Baandrup UT, Nielsen DG, Andersen NH. Rupture of an Abdominal Aortic Aneurysm in a Young Man with Marfan Syndrome. *Ann Vasc Surg* 2018; 48:252. e5-252.e8. <http://dx.doi.org/10.1016/j.avsg.2017.10.024>
5. Mutavdzic P, Dragas M, Kukic B, Stevanovic K, Končar I, Ilić N, Tomic I, et al. An Isolated Aneurysm of the Abdominal Aorta in a Patient with Marfan Syndrome A Case Report. *Ann Vasc Surg* 2020; 63:454. e1-454.e4. <http://dx.doi.org/10.1016/j.avsg.2018.11.019>
6. Aranson NJ, Patel PB, Mohebbi J, Lancaster RT, Ergul EA, Clouse WD, et al. Presentation, surgical intervention, and long-term survival in patients with Marfan syndrome. *J Vasc Surg* 2020; S0741-5214(19)32552-2. <http://dx.doi.org/10.1016/j.jvs.2019.10.060>

Rev Argent Cardiol 2020;88:461-462.

<http://dx.doi.org/10.7775/rac.v88.i5.18500>

Myocardial Infarction, Pulmonary Thromboembolism and Impending Paradoxical Embolism

The combination of acute myocardial infarction, pulmonary embolism and a thrombus straddling a patent foramen ovale with risk of impending pulmonary or systemic embolism (paradoxical embolism) is extremely rare and presents high morbidity and mortality rates. Therefore, deciding on a treatment turns into a clinical challenge.

We report the case of a 57-year-old man with hypertension, obesity, and dyslipidemia, who was admitted to our health center for anterior wall acute coronary syndrome, presenting ventricular fibrillation (VF) in the emergency room, which required defibrillation, cardiopulmonary resuscitation and mechanical ventila-

tion. A drug-eluting stent angioplasty was performed on the anterior descending artery, and the patient was extubated within 24 hours.

Doppler echocardiography showed preserved left ventricular (LV) diameter, LV hypertrophy, interventricular septum (IVS) thickness of 11 mm, anterior septal hypokinesis with 40% left ventricular ejection fraction, preserved right ventricle (RV) and normal atrial size.

The patient evolved without complications during the first 72 hours. On the 4th day after the Valsalva maneuver, he had recurrence and cardiopulmonary arrest with electromechanical dissociation. Response to CPR was successful, and orotracheal intubation and mechanical ventilation were performed. The patient was not in shock. Emergency echocardiography revealed a mobile, thrombotic-like image, straddling between both atria through a patent foramen ovale, in contact with both the RV and LV inflow tracts.

Treatment with unfractionated heparin was initiated. Pulmonary CT angiography reported bilateral segmental and subsegmental pulmonary thromboembolism (PTE), and venous Doppler echocardiography of both lower limbs was negative for deep vein thrombosis.

During the first 24 hours, the patient was hemodynamically stable, regained lucidity without neurological sequelae, and was extubated. Only 3 liters/minute supplemental oxygen given via cannula was required. Given the high risk of right and left embolization, a consultation with the Department of Cardiovascular Surgery was requested and surgical resection of the thrombus and mechanical thrombectomy of the pulmonary artery were performed.

The patient had good postoperative course and was discharged five days later, continuing with the prescribed medical treatment, regular check-ups and cardiac rehabilitation sessions.

Prophylaxis with low-molecular-weight heparin has significantly lowered the incidence of PTE in myocardial infarction, and is currently a very rare complication (< 2%). (1) Once pulmonary embolism occurs, it is also rare to find a thrombus in transit through the right chambers (<4%) in the Doppler echocardiography, (2) and even rarer and more serious is to find a thrombus straddling a patent foramen ovale (PFO), as was the case with our patient. (3, 4)

Therapeutic options in those cases include anticoagulation, thrombolytics, and surgery (embolectomy and PFO closure). As these are very rare cases, the literature is limited to case reports or case series, and of course there is no randomized study or guideline from scientific societies regarding the approach to be followed.

The latest systematic review published in 2017 (5) (with 194 cases of thrombi entrapped in a PFO from 1995 to 2015) reported that most patients (57.7%) were treated with surgery, 14.4% with thrombolytics, and 27.8% with anticoagulation alone. The incidence of

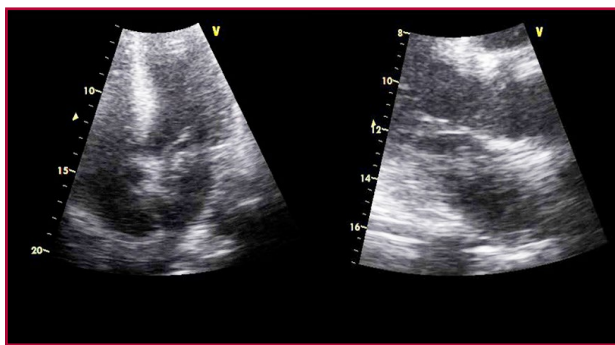


Fig. 1. Doppler echocardiography image consistent with thrombus in transit

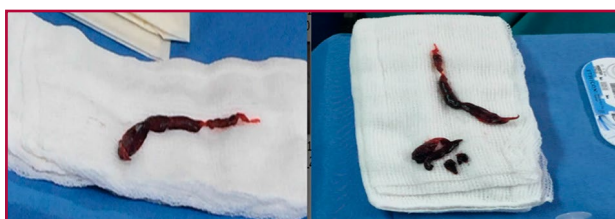

Fig. 2. A. Image of thrombus in transit (left) and pulmonary thrombectomy (right).

post-treatment embolism was 8.3% (stroke 5.7%), and overall mortality rate was 13.9%, mostly due to cardiogenic shock, followed by stroke and treatment complications.

Only three patients in this series were associated with myocardial infarction, and in these cases, it was the result of a complication of the paradoxical embolism in the coronary arteries, and not 4 days later as was the case with our patient. Mortality at 60 days was lower in patients undergoing surgery (6.3%) compared with those treated with thrombolytics (35.7%) or anticoagulation alone (18.5%). The incidence of embolisms in operated patients (4.5%) was also significantly lower compared with those receiving thrombolytics (14.3%) and anticoagulation (13%). While numbers favor surgical treatment, it should be pointed out that these are only case reports and patients with hemodynamic instability may not make it to surgery.

Our patient underwent surgical embolectomy, PFO closure and pulmonary artery thrombectomy, since he also had a straddling thrombus in it. The postoperative course was uneventful, even though he had undergone drug-eluting stent angioplasty and was receiving dual antiplatelet therapy with aspirin and clopidogrel due to his acute coronary syndrome.

Conflicts of interest

None declared.

(See authors' conflicts of interest forms on the website/ Supplementary material).

Ethical considerations

Not applicable

**Nicolás Aquino, Yanina Castillo Costa ,
Víctor Mauro, Martín Vernaba,
Miguel Rubio, Carlos Barrero**

Clínica Bazterrica.
Juncal 3002 (1425), Ciudad Autónoma de Buenos Aires.
E-mail: nico.aquino@gmail.com

REFERENCES

1. Collins R, MacMahon S, Flater M, Baigent C, Remving L, Mortensen TK, et al. Clinical effects of anticoagulant therapy in suspected acute myocardial infarction: systematic overview of randomised trials. *BMJ* 1996;313:652. <https://doi.org/10.1136/bmj.313.7058.652>
2. Hidalgo-Torrico I, Fletcher-Sanfelix D, Enríquez F, Padro D, Tarrío-Fernández R, Sáez de Ibarra JI. Embolia paradójica inminente tras tromboembolismo pulmonar masivo. *Cirugía Cardiovascular* 2019;26: 175-8
3. Aboyans V, Lacroix P, Ostyn E, Cornu E, Laskar M. Diagnosis and management of entrapped embolus through a patent foramen ovale. *Eur J CardioThorac Surg* 1998; 14: 624-8
4. Eva Otoupalova, Bhavinkumar Dalal y Brian Renard. Right heart thrombus in transit: a series of two cases. *Crit Ultrasound J* (2017) 9:14
5. Won-Woo S, Systematic review of treatment for trapped thrombus in patent foramen ovale. *Korean Circ J* 2017;47:776. <http://dx.doi.org/10.4070/kcj.2016.0295>

Rev Argent Cardiol 2020;88:462-464.
<http://dx.doi.org/10.7775/rac.v88.i5.17512>

Attendees to the Argentine Society of Cardiology Webinars. Analysis of Variables Associated with Audience and Trend

Since its inception, medical education (ME) has been based on an instructor imparting knowledge to one or more students or trainees. While this model has been standardized and regulated over the past 100 years, the modality remains the same as in the time of Hippocrates. (1)

Over the past decades, ME has added contents to digital platforms where students can interact and access educational material synchronically or asynchronously. (2) Webinars are multi-platform educational seminars broadcast over the Internet. Their low cost of production and easy access turn them into an ideal tool for breaking down barriers to access medical education. (3)

While the literature suggests that online ME is at least as effective as traditional education, (4) this paradigmatic shift has encountered detractors and multiple barriers, such as absence of institutional strategies and support, poor technical skills, inadequate infrastructure, negative attitudes (from both teachers and students), and generational differences in perceiving its usefulness. (2)

Coronavirus disease (COVID-19) pandemic has had a dramatic impact on the world. Government au-

thorities in Argentina have decreed social and mandatory lockdown and the cessation of crowded activities, such as educational activities. Medical education is no exception, and its graduate and postgraduate programs have adapted to this new reality.

Those responsible for the training area of the Argentine Society of Cardiology (SAC) have managed to offer ongoing postgraduate educational programs through webinars. The aim of this study was to assess the results of this educational proposition in terms of audience and to characterize the variables that marked its behavior.

This was a descriptive, retrospective study. A website created in the form of agenda was used to organize, in one place, a large number of webinars classified by specialties (www.medbinars.com). Webinars hosted by the SAC between May and June 2020 were localized by their streaming day and time, the presence of international guests, industry sponsorship, whether references to COVID-19 were made, and whether the title included a clear and accurate description of a clinical cardiology topic to be addressed. For instance: "Management of Acute Coronary Syndromes during the COVID-19 Pandemic" meets the criterion of clear and accurate description of a clinical cardiology topic. On the contrary: "From Bill Gates to the Pandemic in New York: The Country Asks" does not meet this criterion.

Information about the number of webinar attendees was requested to the SAC by letter. The rest of the data was obtained from the website.

Quantitative variables were assessed using Student's t or Mann-Whitney U tests, depending on their distribution. Categorical variables were analyzed with the chi-square test or Fisher's exact test, as appropriate. The trend of attendees over time was analyzed with the Kruskal-Wallis test.

A total of 31 webinars were hosted by the SAC and its associated entities in the period studied, and audience data was collected from 18 of those webinars (Table 1). Median number of attendees was 409.5 (IQR 25-75 273-574.5). Among the total number of webinars, 9 (50%) were broadcast on Wednesdays and 16 (72.2%) at 7 pm.

COVID-19 or pandemic were mentioned in the titles of 16 webinars (72.2%), and 7 (31.8%) reported that the webinar would deal with a specific topic of general cardiology. There were foreign guests in six webinars (27%).

A difference was observed in the median number of attendees based on a specific title: 714 (IQR 415-892) vs. 326 (IQR 193-465) $p = 0.003$. There was an inverse association between international guests and attendees: median 491 (IQR 401-687) vs 281 (IQR 156-477) $p = 0.039$ (Figure 1). Except for one webinar with 714 attendees, those with international guests referred to situations outside Argentina or on generic topics in their titles.

When the number of attendees was divided into

quartiles, none of the webinars about generic topics reached the 4th quartile ($p = 0.011$).

Trend analysis showed no decrease in the audience over time when webinars were grouped on a biweekly basis.

To date, this is the first study that assesses the audience and its determinants in postgraduate education of an Argentine scientific society during the pandemic. We observed that the SAC hosted 31 webinars in 2 months (average of 3.8/week). The average attendance was good; it seems that the audience is more interested in specific topics of cardiology than in events with international guests. Therefore, it can be inferred that content had more pulling power than speakers. Audience levels were maintained, showing that attendees accepted the methodology and were

not saturated.

Our study demonstrates the feasibility and acceptance of webinar-based educational methods for postgraduate training in cardiology. Our findings are consistent with the survey conducted by Sun, L. et al. on 854 university students in Southeast China, which revealed that 50% of them were satisfied with this modality. From this study, it also emerged the need to transform students from passive recipients into active builders of knowledge. (5)

The persistence of audience levels over time reflects the interest raised by online education due to its multiple attractive features: asynchronicity, low cost, time optimization, diverse offerings, positive environment, and practicality of the topics to be discussed. These last two features were highlighted in a study conducted on primary care physicians. (6) In that study, webinars triggered learning opportunities by creating a comfortable atmosphere, and by predisposing students' active participation when dealing with practical and relevant topics for the daily work of attendees.

"Data Science" applied to "Learning Analytics" education is a discipline that attempts to measure, collect, analyze and report data related to education and its contexts in order to understand and optimize the learning process. This discipline can improve ME processes, as well as encourage institutional growth by creating models that optimize productivity and identification of access barriers to content.

The present study shows practical results of the application of this discipline. By analyzing audience trends, it will be possible to optimize the titles of future webinars in order to improve SAC competitiveness, as well as to implement pre-scheduled streaming agendas or generate contents to encourage participation through internal chat.

Postgraduate education in cardiology provided through webinars is feasible, and had good acceptance and adherence in learners, who maintained audience levels over time and preferred webinars that addressed specific topics related to daily practice. The development of "Learning Analytics" by the SAC will allow to understand users' dynamics and hence, optimize its content.

Conflicts of interest

None declared.

(See authors' conflicts of interest forms on the website/ Supplementary material).

Ethical considerations

Not applicable

Table 1. Webinar features

Webinar features	n=18
Median number of attendees (IQR 25-75)	409,5 (273-574,5)
Streaming on Wednesday	9 (50%)
Streaming on Thursday	4 (18%)
Webinar starting time: 7 pm	16 (72,2%)
Reference to pandemic/COVID-19 in the title	16 (72,2%)
International guest	6 (27%)
Explicit title of a specific topic on general cardiology	7 (31,8%)

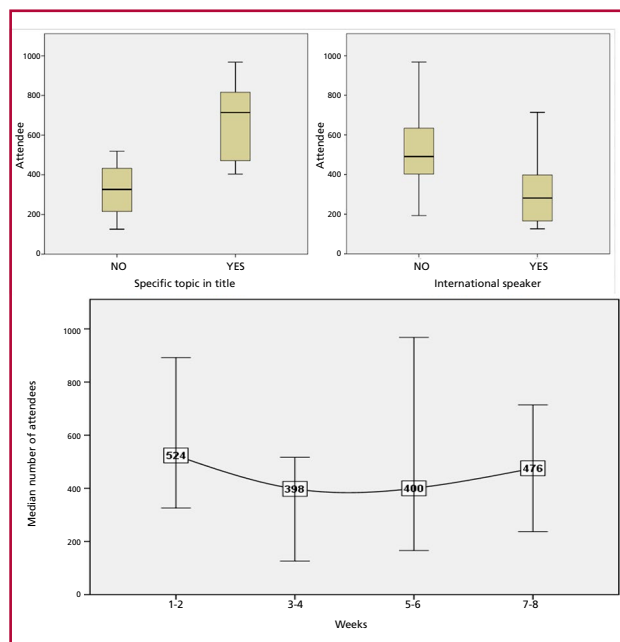


Fig. 2. A. Angiographic control through the guidewire showing patent MUG graft and false lumen (FL). B. Balloon angioplasty for in situ fenestration. C. Angiographic control showing blood flow through the true lumen with complete sealing of the FL

Luciano Battioni¹, Leandro Tomas, Carlos Asención, Fernando Priou, Aneley Porto

Medbinars

¹ Luciano Battioni - Calle 3 N3070 (6600)

Mercedes, Prov. de Buenos Aires

Phone: +54 9 11050506

E-mail: lucianobattioni@gmail.com

REFERENCES

1. Shachar M, Neumann Y. Differences Between Traditional and Distance Education Academic Performances: A Meta-Analytic Approach. *Int Rev Res Open Distrib Learn* 2003 ;4:100–4. <https://doi.org/10.19173/irrodl.v4i2.153>
2. O'Doherty D, Dromey M, Loughheed J, Hannigan A, Last J, McGrath D. Barriers and solutions to online learning in medical education – an integrative review. *BMC Med Educ* 2018 ;18:130. <https://doi.org/10.1186/s12909-018-1240-0>
3. Chiswell M, Smissen A, Ugalde A, Lawson D, Whiffen R, Brockington S, et al. Using Webinars for the Education of Health Professionals and People Affected by Cancer: Processes and Evaluation. *J Cancer Educ* 2018;33:583–91. <https://doi.org/10.1007/s13187-016-1138-7>
4. Goldberg HR, Haase E, Shoukas A, Schramm L. Redefining classroom instruction. *Adv Physiol Educ* 2006;30:124–7. <https://doi.org/10.1152/advan.00017.2006>
5. Sun L, Tang Y, Zuo W. Coronavirus pushes education online. *Nat Mater* 2020;19:687. <https://doi.org/10.1038/s41563-020-0678-8>
6. Kimura S, Onishi H, Kawamata M. Characteristics and perceptions of twice-weekly webinars for primary care physicians in Japan: a qualitative study. *Int J Med Educ* 2018;9:229–38. <https://doi.org/10.5116/ijme.5b6b.21e1>

Rev Argent Cardiol 2020;88:464-466.
<http://dx.doi.org/10.7775/rac.v88.i5.18616>
