

Pericardial effusion associated with DRESS syndrome. Case report

Derrame pericárdico asociado con síndrome de DRESS. Reporte de caso

Laura María Román-Chica¹  Ángela María Díaz-Duarte² 

¹ Clínica Central Del Quindío - Intensive Care Unit - Armenia, Quindío - Colombia.

² Clínica Central Del Quindío - Concurrent Audit Office - Armenia, Quindío - Colombia.

Corresponding author: Laura María Román-Chica. Unidad de Cuidado Intensivo, Clínica Central Del Quindío. Armenia, Quindío. Colombia.

Email: lalamaria4@hotmail.com.

Abstract

Introduction: The DRESS (drug reaction with eosinophilia and systemic symptoms) syndrome is a rare but serious and potentially lethal occurrence of a set of signs and symptoms associated with the use certain types of drugs. This syndrome is characterized by a heterogeneous clinical manifestation that, in many cases, results in multisystemic involvement.

Case presentation: A 24-year-old man from Calarcá, Colombia, visited the emergency department of the local hospital due to a three-day history of unquantified intermittent fever associated with asthenia, adynamia, anorexia, headache, myalgia, odynophagia, and upper abdominal pain. Due to his condition and based on laboratory findings, he was referred to the Clínica Central del Quindío. The patient, 20 days before the initial assessment, had been prescribed a pharmacological treatment with non-steroidal anti-inflammatory drugs and phenytoin due to a severe cranioencephalic trauma; he also presented with generalized skin rash, elevated transaminases, and moderate eosinophilia. Complementary studies reported mild pericardial effusion, so DRESS syndrome was suspected, and corticosteroid therapy was started, achieving the complete remission of the syndrome.

Conclusion: Although the DRESS syndrome has a low incidence, it should always be suspected, especially in patients with cardiac and pericardial involvement. In this case, pericardial involvement was evident, demonstrating that individuals with this syndrome may present with rare symptoms that have a serious impact on their health, as they may significantly increase adverse outcomes and mortality risk.

Keywords: Hypersensitivity; Pericardial Effusion; Exanthema; Eosinophilia; Phenytoin (MeSH).

Román-Chica LM, Díaz-Duarte AM. Pericardial effusion associated with DRESS syndrome. Case report. Rev. Fac. Med. 2021;69(4):e86390. English. doi: <https://doi.org/10.15446/revfacmed.v69n4.86390>.

Resumen

Introducción. El síndrome de DRESS (Drug Reaction with Eosinophilia and Systemic symptoms) consiste en la ocurrencia, si bien poco frecuente, pero grave y potencialmente mortal, de un conjunto de signos y síntomas asociados al consumo de cierto tipo de medicamentos. Este síndrome se caracteriza por tener una manifestación clínica heterogénea que, en muchos casos, causa compromiso multisistémico.

Presentación del caso. Hombre de 24 años de Calarcá, Colombia, que asistió al servicio de urgencias del hospital local por presentar fiebre intermitente no cuantificada durante 3 días, junto con astenia, adinamia, anorexia, cefalea, mialgias, odinofagia y dolor abdominal superior, y que, debido a su condición y resultados de laboratorio, fue remitido a la Clínica Central del Quindío. El paciente, 20 días antes de la valoración inicial, había recibido tratamiento farmacológico con antiinflamatorios no esteroides y fenitoína por traumatismo craneoencefálico severo; además presentó rash cutáneo generalizado, elevación de transaminasas y eosinofilia moderada. En los estudios complementarios se reportó derrame pericárdico leve, por lo que se sospechó síndrome de DRESS y se inició corticoterapia, lográndose así la remisión completa de la enfermedad.

Conclusión. Aunque el síndrome de DRESS tiene una baja incidencia, siempre debe sospecharse, en especial en pacientes que presentan compromiso cardíaco y pericárdico. En este caso se destaca la afectación pericárdica, demostrando que en este síndrome se pueden presentar manifestaciones poco frecuentes, pero con un gran impacto en su salud, ya que pueden aumentar considerablemente los desenlaces adversos y la mortalidad en estos pacientes.

Palabras clave: Hipersensibilidad; Derrame pericárdico; Eosinofilia; Exantema; Fenitoína (DeCS).

Román-Chica LM, Díaz-Duarte AM. [Derrame pericárdico asociado con síndrome de DRESS. Reporte de caso]. Rev. Fac. Med. 2021;69(4):e86390. English. doi: <https://doi.org/10.15446/revfacmed.v69n4.86390>.

Introduction

DRESS syndrome is a rare condition caused by a hyper-sensitive and disproportionate response of the immune system to exposure to various chemicals, mainly drugs. Its incidence is still unknown, but the risk of presentation in patients exposed to drugs is estimated to be between 1 in 1 000 and 1 in 10 000.¹ Due to the lack of clearly defined criteria, it is often considered as a clinical diagnosis of exclusion. According to Husain *et al.*,² this condition may cause high mortality rates (up to 10%) if not detected in a timely manner.

The term DRESS (drug rash with eosinophilia and systemic symptoms) was coined in 1996 by Bocquet *et al.*,³ but Chaiken *et al.*⁴ described a similar condition associated with the use of phenytoin as early as 1930. Over time, this syndrome was classified as a serious adverse drug reaction, along with other skin reactions such as Stevens-Johnson syndrome, acute generalized exanthematous pustulosis, and toxic epidermal necrolysis.⁵

The objective of this report is to expose an unusual presentation of DRESS syndrome in order to guide its timely diagnosis, thus avoiding complications arising from the late treatment of these patients.

Case presentation

A 24-year-old man from Calarcá (Quindío, Colombia) visited the emergency department of a secondary care hospital in the municipality where he lived due to a three-day history of unquantified intermittent fever, asthenia, adynamia, anorexia, moderate global headache, myalgia, odynophagia, and non-radiating colicky upper abdominal pain.

The patient had no significant medical, allergic, or family history; however, 20 days before the initial assessment, he was involved in a motorcycle accident and sustained severe cranioencephalic trauma, requiring surgical management with decompressive craniectomy. On that occasion, he had an adequate clinical course in the postoperative period and was discharged 4 days after the procedure with a prescription for non-steroidal anti-inflammatory drugs every 8 hours orally to treat pain and phenytoin oral capsules 100mg orally every 8 hours indefinitely until a new neurosurgery follow-up.

During the assessment made in the emergency department, the patient was febrile, tachycardic, dehydrated, and with evidence of generalized skin rash. Therefore, additional laboratory studies were requested, which revealed elevated transaminase levels and eosinophilia. Since no other alterations were reported, management at the highest level of care was considered necessary, and he was referred the next day to the Clínica Central Del Quindío in the city of Armenia (Colombia).

The patient was admitted to the clinic in acceptable general condition with the following vital signs: temperature of 38.8°C, heart rate of 118 bpm, respiratory rate of 25 breath/min, and blood pressure 112/66 mmHg. Physical examination revealed that he was dehydrated (grade II), with pain on deep palpation in the right hypochondrium, no signs of peritoneal irritation, and presence of plaque-like lesions and confluent erythematous urticaria-like papules distributed mainly in the lower limbs and trunk (Figure 1). During the initial approach, laboratory and imaging studies were requested, and the most relevant findings are presented in Table 1.

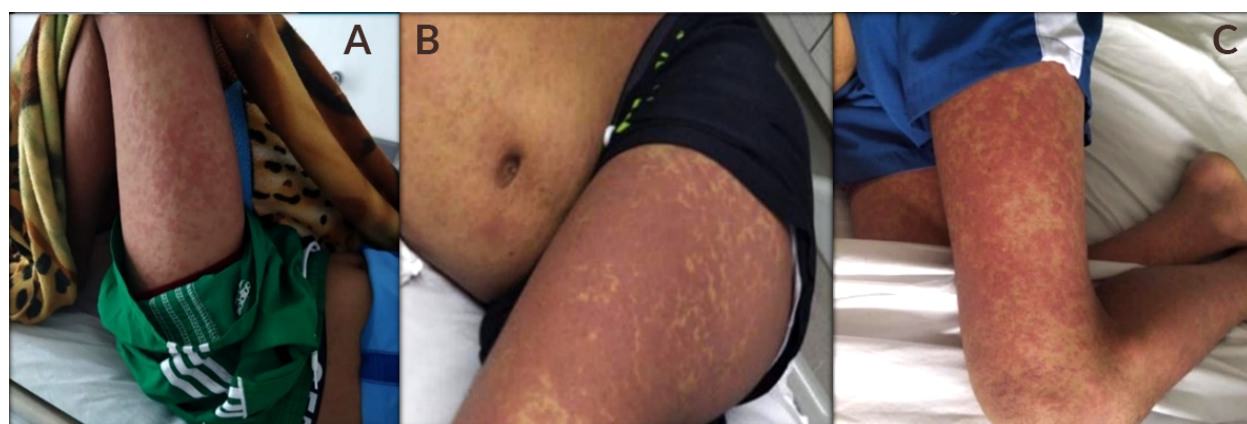


Figure 1. Plaque-like lesions and confluent erythematous urticaria-like papules. A) At the time of admission; B) and C) after a few days of hospital stay.

Source: Document obtained during the course of the study.

Table 1. Imaging and laboratory findings.

Test	Relevant findings
Blood count	Moderate eosinophilia (1000 cells/microliter)
Transaminase level	AST 916U/L - ALT 998U/L
Bilirubin	Total: 2.5 mg/dl. Direct: \geq 1.85mg/dl
Hepatobiliary ultrasound	Normal

Source: Own elaboration.

The treatment plan was to administer a single dose of corticoid (hydrocortisone 100mg IV) and analgesics and antipyretics (dipyron 1g IV), as well as intravenous hydration (1000mL bolus of 0.9% saline). It was also decided to admit the patient to the hospital so that the internal medicine service assessed him. The specialist requested a viral panel to detect hepatotropic viruses, HIV ELISA, serological test for syphilis (VDRL), blood cultures, and urine culture.

During the second day of hospitalization, and while awaiting the report of the studies, the patient continued with intermittent fever, so it was decided to start antibiotic management with ceftriaxone 1g IV every 12 hours for broad-spectrum coverage.

On the third day of hospital stay, HIV, VDRL, and culture test results were negative, and other causes of fever, including an autoimmune origin, were considered. Anti-nuclear antibodies, extractable antibodies, and anti-DNA antibodies, as well as an aprocalcitonin test, were requested as part of the care protocol in patients with fever of unknown origin. A possible endocardial infection focus was also considered, so a transthoracic echocardiogram was requested, the results of which were obtained the next day and revealed mild pericardial effusion located in the posterior wall of the right atrium, moderate pericardial effusion adjacent to left cavities (Figure 2), and no signs of tamponade, constriction, or hemodynamic effects.

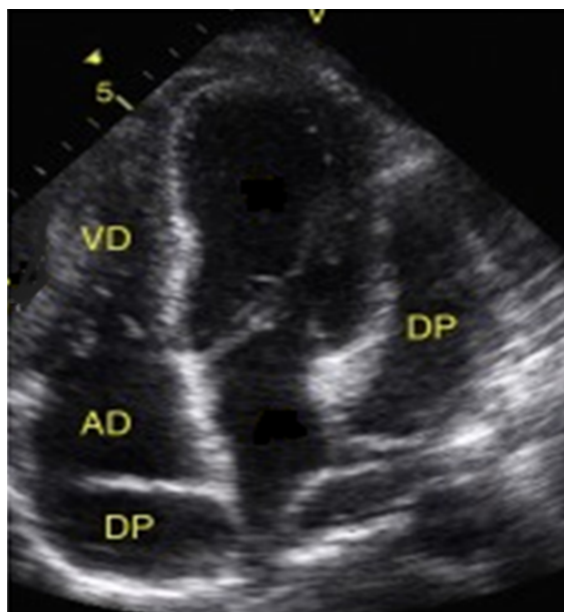


Figure 2. Transthoracic echocardiogram showing mild pericardial effusion in the posterior wall of the right atrium and moderate adjacent pericardial effusion adjacent to the left cavities. AD: right atrium; RV: right ventricle; PD: pericardial effusion. Source: Document obtained during the study.

In view of this relevant finding, on the fourth day of hospitalization and with all the laboratory results, a new evaluation of the case was carried out considering the possible differential diagnoses. After evaluating the patient's condition, it was decided to rule out both infectious and autoimmune etiologies due to negative laboratory

test reports, the absence of fever for more than 24 hours, and the negative polymerase chain reaction (PCR) test. Therefore, other drug-related causes were considered, including DRESS syndrome, which was proposed as a diagnostic option due to the fulfillment of the three main characteristics of the disease: skin lesions, presence of eosinophilia, and multisystem involvement presumably associated with the use of anticonvulsants (phenytoin), which were suspended to subsequently initiate therapy with glucocorticoid methylprednisolone (500mg IV every 24 hours for 3 days).

On the third day of treatment, skin lesions had almost completely disappeared, and liver function and eosinophilia had normalized; therefore, it was decided to discharge the patient with a prescription of prednisolone 1 mg/kg/day for 5 days and gradually taper off, to discontinue the anticonvulsant medication, and to schedule an outpatient visit 15 days later. During the follow-up consultation, it was found that the patient had progressed satisfactorily and had no subsequent complications.

Discussion

DRESS syndrome is a severe drug hypersensitivity syndrome that causes cutaneous and systemic manifestations. Its pathophysiology is not clearly understood, but it has been suggested that it may be related to drug metabolism enzyme deficiency, impaired drug detoxification, lymphocyte activation, herpes virus reactivation, genetic predisposition, among others.²

According to reports from the RegiSCAR study, conducted between February 2003 and May 2006, the genesis of this syndrome is related to approximately 316 therapeutic components, finding a stronger relationship with aromatic antiepileptic drugs (35%), followed by allopurinol (18%), and sulfamides (12%).⁶

In terms of clinical presentation, organ dysfunction is relatively rare in DRESS syndrome, but it primarily affects liver and kidney function and causes myocarditis, pneumonitis, and, less frequently, meningoencephalitis.⁷ Likewise, electrocardiographic findings such as T-wave alterations, sinus tachycardia, low ejection fraction, elevated troponin I, systolic dysfunction, biventricular heart failure and, in very rare cases, pericardial involvement have been described as unusual heart abnormalities.⁸

Due to the wide spectrum of symptoms generated by this syndrome, attempts have been made to establish criteria for its definition; however, currently only three key features have been proposed for its diagnosis: multisystem involvement, drug-related skin lesions, and eosinophilia or the presence of atypical lymphocytes. However, the time of onset of symptoms, their relationship to the start of drug administration, and the improvement after medication discontinuation have been considered as possible new criteria.⁹

Regarding differential diagnoses, it should be noted that the symptoms observed during the course of this condition are similar to those seen in other syndromes, such as those resulting from bacterial infections, viral infections by cytomegalovirus, HIV, Epstein-Barr virus,

viral hepatitis, connective tissue diseases, and febrile rash;¹⁰ thus, these diseases should be considered and ruled out using diagnostic and laboratory aids, as in the case presented here.

Regarding the treatment of DRESS syndrome, the first step is to discontinue the related drug, followed by the administration of corticosteroids at doses equivalent to 1–2 mg/kg per day of prednisone.¹¹ Other treatments, such as antiviral drugs, immunoglobulins, cyclosporine, cyclophosphamide, azathioprine and rituximab or the use of plasmapheresis, have not yet been approved due to their poor efficacy.^{12,13}

Finally, it should be kept in mind that prospective studies recommend long-term follow-up after treating the acute episode, since this syndrome has been associated with various autoimmune diseases, including Graves' disease, systemic lupus erythematosus, type 1 diabetes mellitus, and autoimmune hemolytic anemia, which may occur in 3–5% of patients.¹⁴

Conclusion

Although DRESS syndrome has a low incidence and poses a diagnostic challenge, mainly because of its heterogeneous clinical presentation, it should always be suspected, especially in patients with cardiac and pericardial involvement. This case, in particular, demonstrates that, while pericardial involvement is rare, it has a major impact on these patients because adverse outcomes and mortality may increase significantly. Therefore, timely diagnosis and appropriate treatment are critical, as in the present case, as they allowed avoiding adverse outcomes and long-term sequelae.

Informed consent

For this case report, informed consent was obtained from the patient and one of his relatives, according to the institution's procedures.

Conflicts of interest

None stated by the authors.

Funding

None stated by the authors.

Acknowledgments

To Dr. Camilo Ernesto Barros, internist of the Hospital Universitario de la Samaritana (Zipaquirá Functional Unit) for his support and guidance in the preparation of this case report.

References

1. Cho YT, Yang CW, Chu CY. Drug Reaction with Eosinophilia and Systemic Symptoms (DRESS): An Interplay among Drugs, Viruses, and Immune System. *Int J Mol Sci.* 2017;18(6):1243. <https://doi.org/gbmgf6>.
2. Husain Z, Reddy BY, Schwartz RA. DRESS syndrome: Part I. Clinical perspectives. *J Am Acad Dermatol.* 2013;68(5):693.e1–14. <https://doi.org/f2krck>.
3. Bocquet H, Bagot M, Roujeau JC. Drug-induced pseudolymphoma and drug hypersensitivity syndrome (Drug Rash with Eosinophilia and Systemic Symptoms: DRESS). *Semin Cutan Med Surg.* 1996;15(4):250–7. <https://doi.org/bmqtrf>.
4. Chaiken BH, Goldberg BI, Segal JP. Dilantin sensitivity; report of a case of hepatitis with jaundice, pyrexia and exfoliative dermatitis. *N Engl J Med.* 1950;242(23):897–8. <https://doi.org/cbpvg7>.
5. Behera SK, Das S, Xavier AS, Selvarajan S. DRESS syndrome: a detailed insight. *Hosp Pract (1995).* 2018;46(3):152–62. <https://doi.org/g622>.
6. Kardaun SH, Sekula P, Valeyrie-Allanore L, Liss Y, Chu CY, Creamer D, et al. Drug reaction with eosinophilia and systemic symptoms (DRESS): an original multisystem adverse drug reaction. Results from the prospective RegiSCAR study. *Br J Dermatol.* 2013;169(5):1071–80. <https://doi.org/f5v875>.
7. Oelze LL, Pillow MT. Phenytoin-induced drug reaction with eosinophilia and systemic symptoms (DRESS) syndrome: a case report from the emergency department. *J Emerg Med.* 2013;44(1):75–8. <https://doi.org/bs4kbf>.
8. Morikawa D, Hiraoka E, Obunai K, Norisue Y. Myocarditis Associated with Drug Reaction with Eosinophilia and Systemic Symptoms (DRESS) Syndrome: A Case Report and Review of the Literature. *Am J Case Rep.* 2018;19:978–84. <https://doi.org/gd37tk>.
9. Shiohara T, Iijima M, Ikezawa Z, Hashimoto K. The diagnosis of DRESS syndrome has been sufficiently established on the basis of typical clinical features and viral reactivations. *Br J Dermatol.* 2007;156(5):1083–4. <https://doi.org/frtkk4>.
10. Corneli HM. DRESS Syndrome: Drug Reaction With Eosinophilia and Systemic Symptoms. *Pediatr Emerg Care.* 2017;33(7):499–502. <https://doi.org/g624>.
11. Ocampo-Garza J, Ocampo-Garza SS, Martínez-Villarreal JD, Barbosa-Moreno LE, Guerrero-González GA, Ocampo-Candiani J. Reacción por drogas con eosinofilia y síntomas sistémicos (síndrome de DRESS). Estudio retrospectivo de nueve casos. *Rev Med Chile.* 2015;143(5):577–83. <https://doi.org/g8n3>.
12. Joly P, Janela B, Tetart F, Rogez S, Picard D, D'Incan M, et al. Poor benefit/risk balance of intravenous immunoglobulins in DRESS. *Arch Dermatol.* 2012;148(4):543–4. <https://doi.org/bxt2>.
13. Funck-Brentano E, Duong TA, Bouvresse S, Bagot M, Wolkenstein P, Roujeau JC, et al. Therapeutic management of DRESS: a retrospective study of 38 cases. *J Am Acad Dermatol.* 2015;72(2):246–52. <https://doi.org/f2x7fb>.
14. Isaacs M, Cardones AR, Rahnama-Moghadam S. DRESS syndrome: clinical myths and pearls. *Cutis.* 2018;102(5):322–6.