

A CONE-BEAM COMPUTED TOMOGRAPHY STUDY TO ASSESS ANTERIOR LOOP AND OTHER ANATOMIC VARIATIONS IN MENTAL FORAMEN AREA IN AN IRANIAN POPULATION.

Un estudio de tomografía computarizada de haz cónico para evaluar el asa anterior y otras variaciones anatómicas en el área del foramen mentoniano en una población iraní.

Leila Khojastepour.¹
Sahar Assar.²
Najmeh Movahhedian.¹
Mohammad Mahjoori-ghasrodashti.³
Farzaneh Ahrari.⁴

AFFILIATIONS:

¹Department of Oral and Maxillofacial Radiology, School of Dentistry, Shiraz University of Medical Sciences, Shiraz, Iran.

²Student Research Committee, School of Dentistry, Shiraz University of Medical Sciences, Shiraz, Iran.

³Eastman Institute for Oral Health, Rochester, United States.

⁴Dental Research Center, School of Dentistry, Mashhad University of Medical Sciences, Mashhad, Iran.

CORRESPONDING AUTHOR:

Farzaneh Ahrari. Dental Research Center, School of Dentistry, Mashhad University of Medical Sciences, Vakilabad Blvd, Mashhad, Iran. Phone: (0098-51) 38829504. E-mail: farzaneh.ahrari@gmail.com; Ahrarif@mums.ac.ir

CITE AS:

Khojastepour L, Assar S, Movahhedian N, Mahjoori-ghasrodashti M & Ahrari F. A cone-beam computed tomography study to assess anterior loop and other anatomic variations in mental foramen area in an Iranian population.

J Oral Res.2022;11(1):1-14.

doi:10.17126/joralres.2022.004

ABSTRACT:

Purpose: This study aimed to determine the prevalence and length of the anterior loop (AL) of the inferior alveolar nerve, and evaluate the emergence direction of the mental nerve and the location of mental foramen in a group of Iranian patients.

Material and Methods: This study was carried out on CBCT scans of 150 patients (57 males and 93 females; mean age 40.8 ±14.33 years). The presence and extent of the AL was determined in reconstructed images. The emergence path of the mental nerve was classified into three groups: anteriorly directed emergence, right-angled pattern of emergence, and posteriorly directed emergence. The location of mental foramen relative to adjacent premolars was determined.

Results: AL was identified in 14.7% of the cases with a mean length of 1.39±0.91 mm (range 0.25 to 3.50 mm). No significant differences were observed in the prevalence and extent of the AL between genders ($p>0.05$). The right-angled pattern of emergence was more dominant (43.7%). The most prevalent location of mental foramen was between the first and second premolars (68.3%). There was no significant association between the presence of AL with the path of emergence of the mental nerve ($p=0.627$) or the location of the mental foramen ($p=0.100$).

Conclusion: The prevalence of anterior loop was relatively low in the present sample (14.7%) with a length range of 0.25 to 3.5 mm. Due to the importance of this anatomic variation in implant surgery, it is suggested to carefully assess CBCT images before the surgical procedure to avoid neurosensory complications.

KEYWORDS:

Cone-Beam Computed Tomography; Dental implants; Mental foramen; Mandibular nerve; Mandible; Prevalence.

Received: 06 May 2021 | Accepted: 07 November 2021 | Published online: 28 January 2022

RESUMEN:

Propósito: Este estudio tuvo como objetivo determinar la prevalencia y la longitud del loop anterior (LA) del nervio alveolar inferior, y evaluar la dirección de emergencia del nervio mentoniano y la ubicación del foramen mentoniano en un grupo de pacientes iraníes.

Material y Métodos: Este estudio se llevó a cabo en exploraciones de tomografía computarizada de haz cónico de 150 pacientes (57 hombres y 93 mujeres; edad media 40,8 ± 14,33 años). La presencia y extensión de la LA se determinó en imágenes reconstruidas. La vía de emergencia del nervio mentoniano se clasificó en tres grupos: emergencia dirigida anteriormente, patrón de emergencia en ángulo recto y emergencia dirigida posteriormente. Se determinó la ubicación del foramen mentoniano en relación con los premolares adyacentes.

Resultados: Se identificó LA en el 14,7% de los casos con una longitud media de 1,39 ± 0,91 mm (rango 0,25 mm a 3,50 mm). No se observaron diferencias significativas en

la prevalencia y extensión de la AL entre sexos ($p > 0,05$). El patrón de emergencia en ángulo recto fue más dominante (43,7%). La localización más prevalente del foramen mentoniano fue entre el primer y segundo premolar (68,3%). No hubo asociación significativa entre la presencia de AL con la vía de emergencia del nervio mentoniano ($p = 0,627$) o la ubicación del foramen mentoniano ($p = 0,100$).

Conclusión: La prevalencia de asa anterior fue relativamente baja en la presente muestra (14,7%) con un rango de longitud de 0,25 mm a 3,5 mm. Debido a la importancia de esta variación anatómica en la cirugía de implantes, se sugiere evaluar cuidadosamente las imágenes de tomografía computarizada de haz cónico antes del procedimiento quirúrgico para evitar complicaciones neurosensoriales.

PALABRAS CLAVE:

Tomografía Computarizada de Haz Cónico; Implantes dentales; Foramen mental; Nervio mandibular; Mandíbula; Prevalencia.

INTRODUCTION.

Mental nerve branches off the inferior alveolar nerve (IAN) through mental foramen (MF) to supply the skin of the chin, as well as the skin and mucous membrane of the lower lip. It sometimes continues anterior to the MF, inside the IAN canal, and then turns back to exit through the foramen. This is called the anterior loop (AL) of the mandibular canal by some authors,¹⁻³ whereas others used the anterior loop of the inferior alveolar nerve,⁴⁻⁶ or the anterior loop (AL) of the mental nerve.⁷⁻⁹

Anterior loop is an important anatomic variation in dental implant placement, osteotomies, and endodontic surgeries. In the presence of the anterior loop, any surgical trauma in the interforaminal area may lead to complications including paresthesia, anesthesia, and dysesthesia of the lower lip and chin, due to the transient or persistent damage to the

nerve. Previous studies have shown that the prevalence of the anterior loop varies between different countries and within a specific population. The length of the anterior loop also shows a great variation among different studies.

The prevalence of AL in Brazilians varied from 10.2% to 41.6%.¹⁰⁻¹² In Iran, there is a discrepancy in the prevalence of anterior loop as well, ranging from 32.8% to 84% in different studies.^{7, 11,13,14} Apostolakis *et al.*,¹⁵ reported that the prevalence of AL was 48% within the Greeks with a mean length of 0.89mm (range 0mm-5.7mm).

In a selected United States population, Lu *et al.*,⁸ identified AL in 85.2% of cases with a mean length of 1.46mm ± 1.25mm. Wong and patil⁶ reported the prevalence of 94% for anterior loop in the Malaysian population with a length range between 0.73mm and 7.99mm.

The mental foramen is a landmark with great clinical implications due to the numerous nerve fibers in its vicinity, and it is considered as a danger zone for mandibular surgeries and implant placement. Some studies classified the anatomical variations of mental foramen concerning the emergence direction of its neurovascular bundle and its location relative to the adjacent structures.

Kieser *et al.*,¹⁶ classified the path of emergence of the mental nerve into posterior, anterior, right-angled or multiple. The horizontal location of MF relative to the adjacent teeth has been categorized into six groups:

- Type I: Mesial to the apex of the first premolar;
- Type II: Below the apex of the first premolar;
- Type III: Between the apices of first and second premolars;
- Type IV: Below the apex of the second premolar;
- Type V: Distal to the apex of the second premolar and;
- Type VI: Below the mesial root of the first molar.^{17,18} However, Chen *et al.*,⁵ argued that due to the low rate of incidence for type I and VI, the classification should be narrowed into four remaining groups.

For many years, conventional radiography was used to study dentomaxillofacial anatomical structures and preoperative examinations. In recent years, cone-beam computed tomography (CBCT) has been considered as the radiographic method of choice in such studies, as it provides images in any desired plane with high resolution and without magnification or superimposition of adjacent craniofacial structures.^{3,10}

Using CBCT, it is possible to diagnose the presence and measure the length of the anterior loop of the inferior alveolar nerve with high precision and reliability.^{3,4,19} There is a remarkable variation in the prevalence and extent of the anterior loop in different ethnic groups.

Furthermore, only a few studies have dealt with the emerging direction of the mental nerve, and there is little information regarding any possible

relationship between the presence of the anterior loop with the emergence path of the mental nerve or the location of the mental foramen.

Therefore, the present study aimed to investigate the prevalence and extent of the anterior loop of the inferior alveolar nerve, and assess the anatomic variations in emergence direction of mental nerve and location of mental foramen using 3-dimensional CBCT images in a sample of Iranian population.

MATERIALS AND METHODS.

Sample

The sample of this cross-sectional study was achieved from the CBCT scans of subjects referred to the Department of Oral and Maxillofacial Radiology, School of Dentistry, Shiraz University of Medical Sciences, Shiraz, Iran, between October 2018 and March 2019. Four hundred and thirty six CBCT images were screened for eligibility. To be included in the study, CBCT images should have high diagnostic quality with proper fields of view (FOV) covering mandibular canines to first molars on both sides.

The images showing any pathology in the mandibular canal or mental foramen (MF) area were excluded. The exclusion criteria also involved images that pertained to subjects with missing mandibular premolars, and those who had a history of previous surgery or implant placement in the region of mental foramen. From the pool of 436 CBCT images evaluated, 150 scans, totaling 300 hemimandibles, met the inclusion criteria of the study. These pertained to 57 males and 93 females with a mean age of 40.8 ± 14.33 years (age range: 17-73 years).

The protocol of the study was approved by the Ethical Committee of Shiraz University of Medical Sciences (Protocol No. IR. SUMS. DENTAL. REC. 1398.30), and informed consent was obtained from all participants.

CBCT imaging

All the images were acquired using a NewTom VGi evo CBCT unit (QR SRL Co., Verona, Italy)

with the following specifications: 75-110 kV, 1-32 mA, pulsed mode, focal spot 0.3 mm, amorphous silicon flat panel, scan time 15s – 25s, and emission time 0.9s – 6s.

All CBCT images were taken in a standard voxel size (300 μ m) in different fields of view (FOV; 8cm \times 8cm, 10cm \times 10cm, 12cm \times 8cm, 15cm \times 12cm, and 16cm \times 16cm). Image reconstruction and measurement was performed by the use of the proprietary NewTom software (NNT viewer, version 9.2). The measurements were done by one experienced oral and maxillofacial radiologist in a darkened room. The adjustment in density and contrast of the images was made if necessary for better assessment and measurement procedures.

Measurements

The presence of the anterior loop was evaluated in reconstructed panoramic and axial and coronal (buccolingual) cross sections. The axial slices were reconstructed parallel to the lower border of the mandible. For each case, a panoramic image (thickness 0.5mm) was constructed based on an appropriate axial cross section.

Then the path of the right and left inferior alveolar nerve canals were determined and marked on the image. The anterior loop appeared as a clear returning curve of the inferior alveolar nerve in the reconstructed panoramic images (Figure 1).

This approach was used for quick screening of the anterior loop. Coronal cross sections were also prepared with 0.3 mm thickness and 0.3 mm intervals perpendicular to the mandibular cortices.

These slices were prepared from the most mesial point of the mental foramen. The presence or absence of the anterior loop was decided based on the coronal cross sections. In the coronal cross sections, it was possible to identify two basic types of anterior loop in front of the anterior border of the mental foramen (Figure 2).

1) The presence of a round, oval or elongated sha-ped hypodense area (single canal) with more than 3 mm diameter.

2) The existence of two separate round hypodense areas (double canal); one corresponding

to the lumen of the incisive canal that traverses the mental foramen anteriorly and inferiorly, and the other reflecting the doubling back (loop) of the inferior alveolar nerve.

According to the fact that the size of the incisive canal is never more than 3mm, Apostolakis *et al.*,¹⁵ suggested the 3mm cut off point for differentiating between the anterior extension of the inferior alveolar nerve (anterior loop) and the incisive canal. This suggestion has been accepted and used in the present study for identification of the loop.

The anterior border of the loop could be seen in the axial cross section as a sudden constriction of the canal (Figure 3). However, the presence of the loop in the axial view was not clearly seen in every case. So, the final decision concerning the presence or absence of the loop was made based on the consequent coronal cross sections with the thinnest available thickness (0.3mm).

In cases presenting AL, the length of the anterior loop was measured by counting the number of the contiguous coronal cross sections situated in between the anterior border of the mental foramen and the anterior border of the loop. Using the axial view, the number of buccolingual slices with AL was multiplied by the thickness of the slices (0.3mm) to give the length of the loop in mm.¹⁵

On CBCT axial cross-sections, the emergence direction (ED) of the mental nerve was categorized into three classes: anteriorly directed emergence, right-angled pattern of emergence and posteriorly directed emergence (Figure 4).

Finally, the location of mental foramen (LMF) was classified into four groups based on reconstructed 3D images (Raycast 3D rendering option of NNT software; Figure 5) as follows:

- Type I: below the apex of the first premolar;
 - Type II: between the apices of the first and second premolars;
 - Type III: below the apex of the second premolar;
 - Type IV: distal to the apex of the second premolar.
- All measurements were done only once and by the same investigator.

Statistical analysis

Descriptive statistics were used to indicate the prevalence and length of the anterior loop, the unilateral *versus* bilateral presence of the loop, the emergence direction of the mental nerve and the location of mental foramen. The chi-square test was employed to detect the difference in the prevalence of anterior loop and the difference in the emergence direction of the mental nerve between genders.

The difference in the length of the loop between males and females was assessed by the student *t*-test. The left-right patterning in the emergence of the mental nerve was evaluated by the McNemar test. The association between the presence of the anterior loop with the emergence direction of the mental nerve or the location of mental foramen was evaluated by the chi-square test. The data were processed with SPSS (Statistical Package for the Social Sciences; version 16.0; Chicago, IL, USA)

RESULTS.

Anterior loop was detected in 22 of the 150 patients (14.7%) and in 29 of 300 hemimandibles evaluated in this study. From the 22 patients with AL, 10 were male (17.5 % of 57 males), and 12 were female (12.9 % of 93 females). There were

7 instances of bilateral anterior loop and 15 cases showed unilateral anterior loop occurrences (6 occurrences on the right side and 9 occurrences on the left side).

The mean length of the anterior loop was 1.39mm \pm 0.91mm, ranging from 0.25mm to 3.50mm in the sample. Table 1 presents the prevalence and length of the anterior loop according to the gender of the participants. No significant differences were observed in the prevalence and extent of the anterior loop between males and females ($p>0.05$; Table 1).

Table 2 presents the frequency of different emergence directions of the mental nerve in both genders. The dominant pattern of emergence in 300 hemimandibles was right-angled, observed in 43.7% of the sample. After that, posterior emergence and anterior emergence were common, seen in 34% and 22.3% of the hemimandibles. The chi-square test revealed a significant association between the gender and the emergence direction of the mental nerve ($p=0.040$) (Table 2).

A higher prevalence of posteriorly-directed emergence was observed among males (42.1%) as compared to females (29%). Table 3 shows the left-right patterning in the path of emergence

Figure 1. Panoramic reconstruction showing the path of the mandibular canal and formation of bilateral anterior loop in a curved fashion.

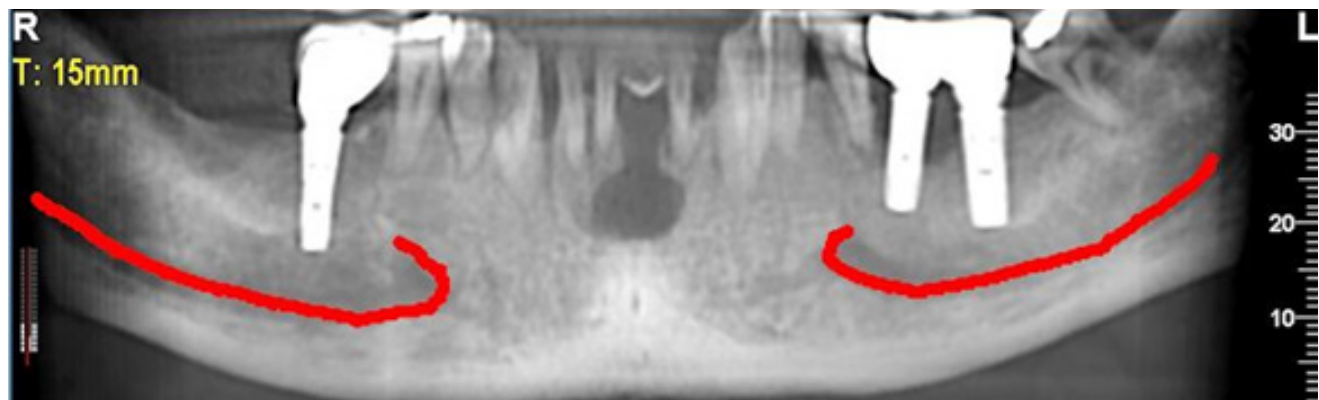
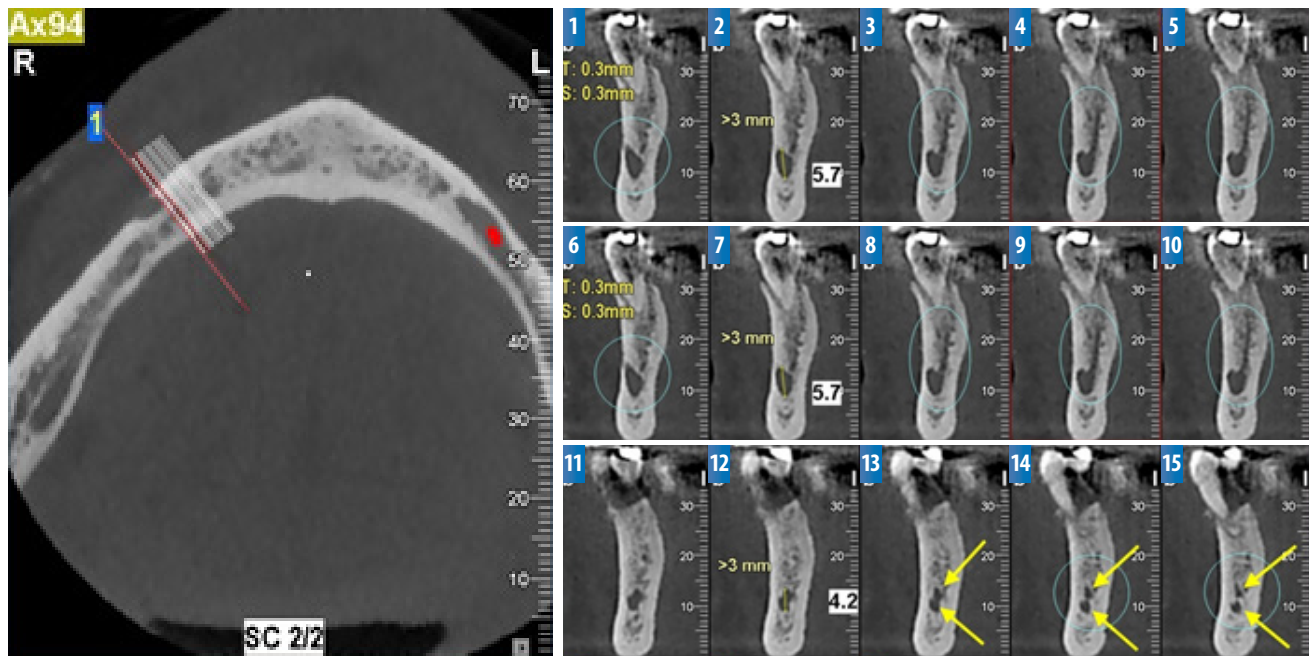


Figure 2. Coronal reconstructions were prepared perpendicular to mandibular cortices from the anterior border of the mental foramen (Cross section 1) to anterior extension of the anterior loop.



The anterior loop can be seen as a single canal with more than 3 mm diameter (cross sections 1-12) or as a double canal (cross section 13-15). Considering the slice thickness, the length of the right anterior loop in this case is equal to 4.5 mm ($15 \times 0.3 = 4.5$ mm).

Figure 3. Arrow in this axial cross section is pointed to the sudden constriction of the canal which represent the anterior border of the anterior loop.

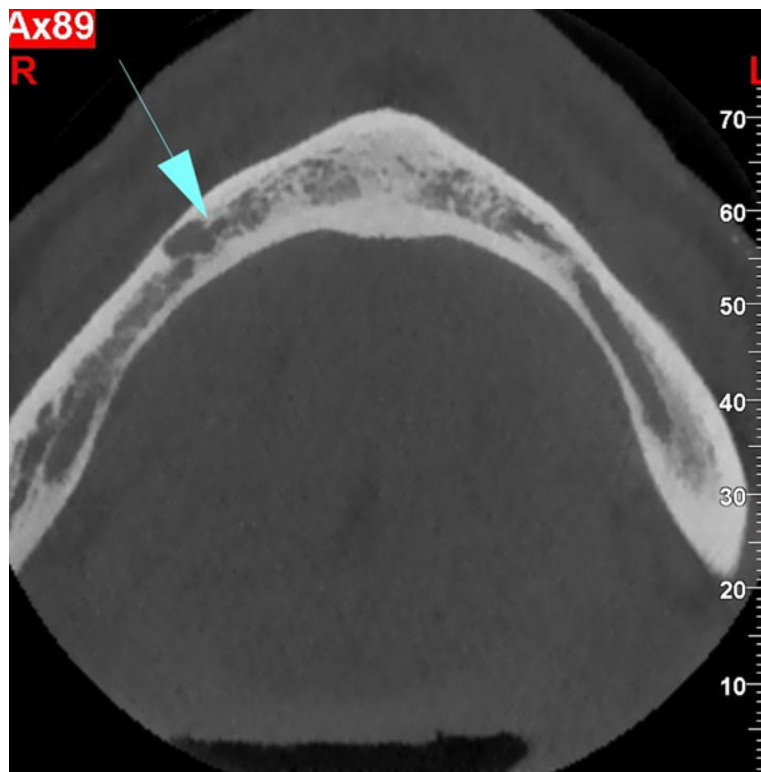
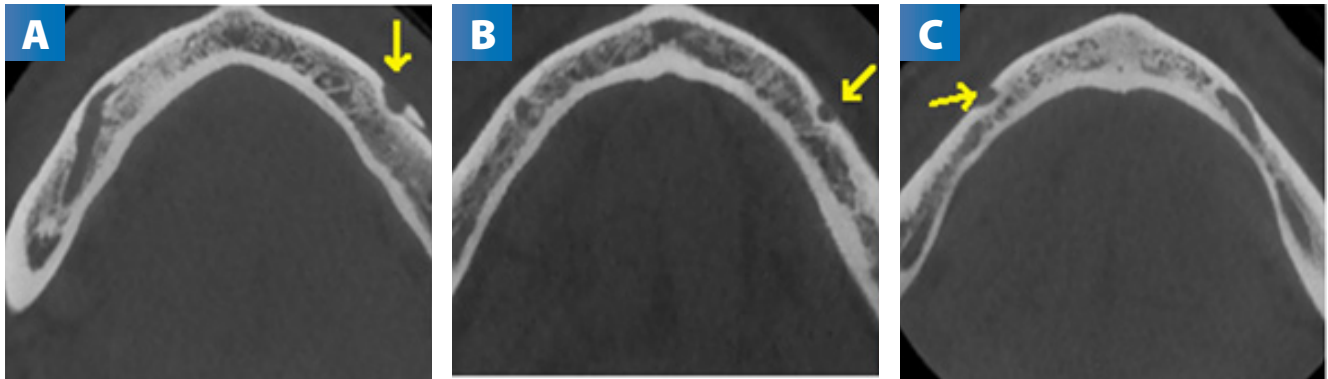


Figure 4. Axial cross sections showing three emergence categories of mental nerve.



A: Anteriorly directed. **B:** Right-angled. **C:** Posteriorly directed.

Figure 5. Reconstructed Raycast 3D rendering image showing the location of mental foramen in relation to premolars.

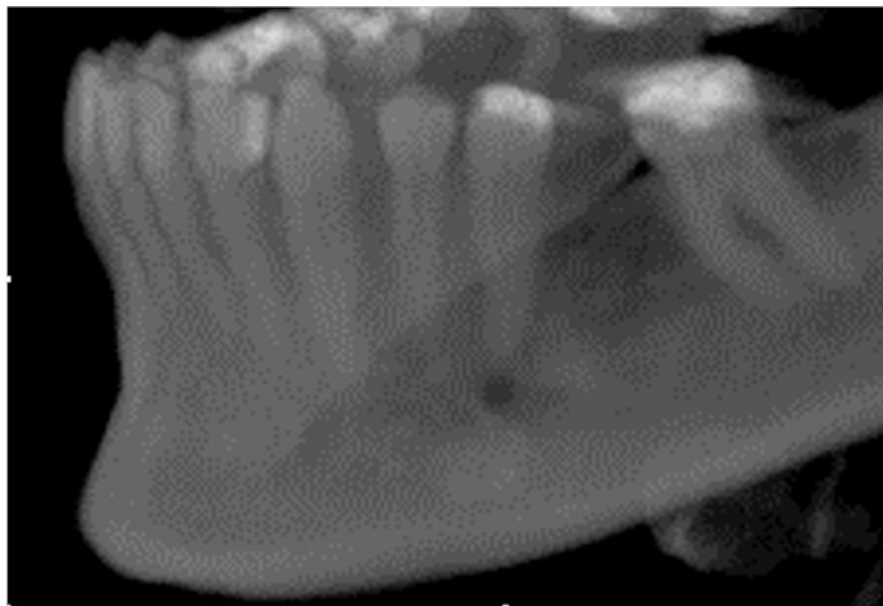


Table 1. The distribution [number (%)] of cases showing the presence or absence of the anterior loop and the length [mean ± standard deviation (SD)] of the loop (mm) if present, in males and females of this study.

GENDER	PRESENCE OF AL n (%)	ABSENCE OF AL n (%)	LENGTH OF ANTERIOR LOOP (mm), IF PRESENT Mean ± SD
Female	12 (12.9)	81 (87.1)	1.25 ± 1.01
Male	10 (17.5)	47 (82.5)	1.50 ± 0.79
Statistical significance	p=0.480		p=0.484

Table 2. The frequency [number (%)] of the different emergence directions of mental nerve in males and females of this study.

EMERGENCE DIRECTION	FEMALE n (%)	MALE n (%)	TOTAL n (%)
Anterior	48 (25.8)	19 (16.7)	67 (22.3)
Right-angled	84 (45.2)	47 (41.2)	131 (43.7)
Posterior	54 (29.0)	48 (42.1)	102 (34.0)
Total	186 (100)	114 (100)	300
Statistical significance		$p=0.040$	

Table 3. The distribution [number (%)] of three emergence paths of mental nerve in the corresponding sides of each patient.

EMERGENCE DIRECTION	LEFT MENTAL NERVE		
	Anterior n (%)	Right-angled n (%)	Posterior n (%)
RIGHT MENTAL NERVE			
Anterior	24 (77.4)	3 (9.7)	4 (12.9)
Right-angled	11 (16.4)	39 (58.2)	17 (25.4)
Posterior	1 (1.9)	22 (42.3)	29 (55.8)
Statistical significance		$p=0.072$	

Table 4. The frequency [number (%)] and association between the presence and absence of anterior loop (AL) with different emergence directions of mental nerve.

EMERGENCE DIRECTION OF MENTAL NERVE	PRESENCE OF AL n (%)	ABSENCE OF AL n (%)	STATISTICAL SIGNIFICANCE
Anterior	5 (17.3)	62 (22.9)	$p= 0.627$
Right-angled	15 (51.7)	116 (42.8)	
Posterior	9 (31.0)	93 (34.3)	
Total	29 (100.0)	271 (100.0)	

Table 5. The frequency [number (%)] and association between the presence and absence of anterior loop (AL) with different locations of mental foramen.

LOCATION OF MENTAL FORAMEN	PRESENCE OF AL n (%)	ABSENCE OF AL n (%)	STATISTICAL SIGNIFICANCE
Type I	2 (6.9)	4 (1.5)	$p=0.100$
Type II	22 (75.9)	184 (67.8)	
Type III	3 (10.3)	65 (24.0)	
Type IV	2 (6.9)	18 (6.7)	
Total	29 (100.0)	271 (100.0)	

of the mental nerve. Among the scans that had anterior direction on the right side, 77.4% had the same direction on the left side. Furthermore, 58.2% and 55.8% of the scans with right-angled and posteriorly directed emergence on the right side showed the same pattern of emergence on the left side. In general, 92 scans (61.3%) had the same path of emergence on both sides, indicating a bilateral agreement ($p=0.072$).

Regarding the location of mental foramen to adjacent teeth, the frequency of type II (68.3%) and type III (22.7%) was highest, followed by type IV and type I (6.7% and 2.0%, respectively).

The statistical analysis revealed that the presence of the anterior loop had no significant association with either the path of emergence of the mental nerve ($p=0.627$; Table 4) or the location of mental foramen ($p=0.100$; Table 5).

DISCUSSION.

The present study evaluated the prevalence and extent of the anterior loop, and the anatomic variations in the emergence direction of mental nerve and the location of mental foramen using CBCT images in a sample of Iranian population.

The detection of anterior loop is of remarkable clinical importance, as it affects the placement of dental implants, which are frequently prescribed in the anterior part of the mandible for edentulous patients with atrophic mandibular ridges.

Although several methods such as two-dimensional (2D) panoramic radiography and anatomical measurements on dry skulls or cadavers have been employed to detect the prevalence and measure the length of the anterior loop, CBCT is a more accurate, reliable and viable option for pre-surgical diagnosis and planning^{3,4,19} and its measurements yield important information to prevent iatrogenic damage to the neurovascular bundle.

The outcomes of this study revealed that the anterior loop existed in about 14.7% of the sample. Although some studies reported the prevalence rate of as low as 9.7%,² 10.2%,¹⁰ or 11.76%¹ for the anterior loop, but most others found higher

values.^{3, 8,9,11,14,19} Kheir *et al.*,⁷ and Panjnoush *et al.*,¹³ reported the prevalence of 32.8% and 59.5%, respectively in Iran, and Lu *et al.*,⁸ found the rate of 85.2% in the United States.

In this study, the anterior loop was more frequently detected on the left side (40.9%), followed by the bilateral presence (31.8%), and then the unilateral occurrence on the right side (27.3%). In contrast, Apostolakis *et al.*,¹⁵ and do Nascimento *et al.*,³ reported that most of the anterior loops occurred bilaterally. The average anterior loop length in the current study was $1.39\text{mm} \pm 0.91\text{mm}$ with the minimum and maximum lengths of 0.25 mm and 3.5mm, respectively.

In previous studies, the average length for anterior loop varied from 0.37mm⁹ to 3.85 mm,⁶ and the range of loop length reached even 11mm²⁰ in some cases. The prevalence and length of the anterior loop did not show any significant intersexual differences, similar to that reported in previous studies.^{6,8,11,21}

The length of the anterior loop is important when estimating a safe limit for placement of interforaminal implants in different ethnic groups. Since traditional radiographic techniques and clinical measures may lead to inaccurate diagnosis in the length of the loop, this conventional safe limit may help the clinician when CBCT images are not available for any reason.

The outcomes of this study are consistent with the findings of Moghaddam *et al.*,¹¹ and Apostolakis *et al.*,¹⁵ who implied that when placing implants, a safety distance of at least 3mm should be considered from the mental foramen in order to preserve the neurovascular bundle.

The remarkable variations in the prevalence and extent of the anterior loop in different studies might be related to the discrepancies in ethnicity, dissimilarities in the age and gender distribution of the subjects. Another influential factor is the measurement technique, as some studies employed conventional radiography,²² whereas others performed direct anatomical measurements²³ and others used computed tomography [CT]^{21,24} or

CBCT scans.^{1,3,4,6,9-15,25} The use of two-dimensional panoramic radiography for identification of the loop can overestimate or underestimate the results, as it is associated with inherent distortion and different extents of magnification throughout the image.²³

The studies that used 3D volumes provided more accurate and reliable data but even in these studies, various anatomical planes and diagnostic criteria have been employed for detection and measurement of the anterior loop. In the present study, we used the reconstructed panoramic images for quick screening of the anterior loop, but the final decision regarding the presence or absence of the loop was made in coronal (buccolingual) cross sections.

Although the loop could be observed in axial view in some cases, it was not always the case. The method applied in this study was strict and precise to detect the anterior loops.

The pattern of emergence of the mental nerve is an important landmark in surgical planning in the mandibular premolar region. In the present study, the most frequent emergence direction of the mental neurovascular bundle was right-angled in both sides, followed by posterior and anterior directions. There was a significant difference in the pattern of emergence of the mental nerve between males and females, so that in males the posterior direction was more prevalent than females.

The majority of patients showed similar emergence path of mental neurovascular bundle on the right and left sides, similar to the outcomes of Kieser *et al.*,¹⁶ and Chandramohan *et al.*,²⁶ Using panoramic radiographs, Iyengar *et al.*,²² categorized the pattern of entry of mental nerve as straight, looping, or perpendicular, and reported that the straight pattern was the most common, followed by the presence of an anterior loop in 21% of the total radiographs examined.

Again it should be noted that panoramic radiographs, provide a two-dimensional image of a three-dimensional structure, and may not be as accurate as CBCTs in identifying the anatomical

landmark directions. By direct visualization of cadaver mandibles, Kieser *et al.*,¹⁶ classify the path of emergence of the mental nerve into posterior, anterior, right-angled or multiple.

They found that in African skulls a right-angled path of emergence was more frequently found, which is in agreement with the outcomes of this study. However, the posterior direction was more pre-valent in caucasoid and Maori skulls. The etiology for different emergence patterns of the mental nerve is not clear. It has been assumed that the posterior gradient of mandibular growth would open the foramen in the posterior direction in most cases. Kieser *et al.*¹⁶

However, argued that the higher prevalence of right-angled path of emergence in Africans might indicate that the genetic control is more dominant in the determination of emergence direction than the functional factors. In the current study, there was no significant association between the presence of the anterior loop and the emergence pattern of the mental nerve. To the best of our knowledge, there is no study evaluating any possible relationship between the presence of the anterior loop and the path of emergence of the mental nerve.

However, the sample size of this study was small and the prevalence of AL was very low. Therefore, more studies with larger sample sizes are warranted to identify if any relation exists. The most frequent location of mental foramen in our study was Type II (between the apices of first and second premolars).

The location of mental foramen is an important subject in the field of implant surgery, because it is desirable to place interforaminal implants as distally as possible while preserving the neurovascular bundle within and in close proximity to the foramen. Some previous studies were in accordance with our results;^{5,17,25,27,28} whereas others exhibited that the most frequent location of MF was at the level of the apex of the second premolar (Type III).^{26,29-33}

This might be the result of different population differences such as age and ethnicity factors

among the studies. Santini *et al.*,³⁴ reported that the most common model position of the foramen in the European and Indian skulls was between the first and second premolars, but in the Chinese skulls in line with the second premolar.

Another reason explaining the heterogeneous results between the studies might be the method of evaluation. Chandramohan *et al.*,²⁶ studied mental foramen on human dry mandibles and Ngeow *et al.*,³⁰ determined the position of the mental foramen using panoramic radiographs, whereas in this study reconstructed 3D CBCT imaging (Ray cast model) was employed.

In the present study, there was no significant association between the presence of anterior loop and the location of mental foramen. This is in accordance with the findings of Krishnan *et al.*,²⁵ In contrast, Chen *et al.*,⁵ reported a significant relationship between the presence of the anterior loop and the location of mental foramen.

This might be due to the methodological as well as to the ethnic differences between the study of Chen *et al.*,⁵ and the present investigation. The limitations of this study were the small sample size and the lack of grouping of subjects according to the age range. Some investigators have indicated that the length of AL decreases with age,⁸ and others reported that the AL was most commonly found in middle-aged patients.²

Considering that the prevalence and length of AL shows a wide discrepancy even in the same population; it seems that performing multicenter researches with larger sample sizes are warranted to assess the effect of different variables such as age, gender, and ethnicity.

Future studies can provide more insights on other possible relationships between the anterior loop and neighboring neurovascular bundles and anatomical landmarks.

Within the limitations of this study, the following conclusions can be drawn:

1). The prevalence of anterior loop of the inferior alveolar nerve was relatively low in the present sample (14.7%). However, due to the importance of this anatomic variation in implant surgery, it is suggested to carefully assess CBCT images before the surgical procedure to avoid neurosensory complications.

2). The average length of the anterior loop in this study was 1.39mm with the range between 0.25mm and 3.50mm. Since most loops were less than 3.5mm in length, a safe distance of at least 3.5mm should be considered from the mental foramen when planning implant placement in the anterior mandible to avoid neurovascular injury.

3). The most frequent emergence direction of the mental nerve was right-angled and there was a bilateral agreement in the path of emergence between the right and left sides.

4). The most prevalent location of mental foramen was between the first and second premolar teeth. The presence of the anterior loop did not show any significant association with either the emergence direction of the mental nerve or the location of mental foramen

CONCLUSION.

Conflict of interests:

There is no conflict of interest to be declared.

Ethics approval:

The protocol of the study was approved by the Ethical Committee of Shiraz University of Medical Sciences (protocol number IR.SUMS.DENTAL.REC.1398.30), and informed consent had been obtained from all participants.

Funding:

A grant from the Vice-Chancellor for Research of Shiraz University of Medical Sciences.

Authors' contributions:

Khojastepour L: project development, supervision, manuscript editing.

Assar S: data collection, data analysis, manuscript writing.

Movahhedian N: project development, supervision, manuscript editing.

Mahjoorighasrodashti M: data collection, data analysis, manuscript writing.

Farzaneh Ahrari: data management, data analysis, manuscript writing and editing.

Acknowledgements:

The authors would like to thank the Vice-Chancellor for Research of Shiraz University of Medical Sciences for financial support of this project (number: 97-01-03-18711). The authors also thank Dr. M. Vossoughi from the Dental Research Development Center for the statistical analyses. This article is based on the thesis by Dr. Sahar Assar.

REFERENCES.

1. J PC, Marimuthu T, C K, Devadoss P, Kumar SM. Prevalence and measurement of anterior loop of the mandibular canal using CBCT: A cross sectional study. *Clin Implant Dent Relat Res.* 2018 Aug;20(4):531-534. doi: 10.1111/cid.12609. PMID: 29624863.
2. Sinha S, Kandula S, Sangamesh NC, Rout P, Mishra S, Bajoria AA. Assessment of the Anterior Loop of the Mandibular Canal Using Cone-Beam Computed Tomography in Eastern India: A Record-Based Study. *J Int Soc Prev Community Dent.* 2019 May-Jun;9(3):290-295. doi: 10.4103/jispcd.JISPCD_83_19. PMID: 31198703; PMCID: PMC6559048.
3. do Nascimento EH, Dos Anjos Pontual ML, Dos Anjos Pontual A, da Cruz Perez DE, Figueiroa JN, Frazão MA, Ramos-Perez FM. Assessment of the anterior loop of the mandibular canal: A study using cone-beam computed tomography. *Imaging Sci Dent.* 2016 Jun;46(2):69-75. doi: 10.5624/isd.2016.46.2.69. PMID: 27358813; PMCID: PMC4925653.
4. do Nascimento EH, Dos Anjos Pontual ML, Dos Anjos Pontual A, da Cruz Perez DE, Figueiroa JN, Frazão MA, Ramos-Perez FM. Assessment of the anterior loop of the mandibular canal: A study using cone-beam computed tomography. *Imaging Sci Dent.* 2016 Jun;46(2):69-75. doi: 10.5624/isd.2016.46.2.69. PMID: 27358813; PMCID: PMC4925653.
5. Chen Z, Chen D, Tang L, Wang F. Relationship between the position of the mental foramen and the anterior loop of the inferior alveolar nerve as determined by cone beam computed tomography combined with mimics. *J Comput Assist Tomogr.* 2015 Jan-Feb;39(1):86-93. doi: 10.1097/RCT.000000000000166. PMID: 25299797.
6. Wong SK, Patil PG. Measuring anterior loop length of the inferior alveolar nerve to estimate safe zone in implant planning: A CBCT study in a Malaysian population. *J Prosthet Dent.* 2018 Aug;120(2):210-213. doi: 10.1016/j.prosdent.2017.10.019. PMID: 29551376.
7. Kheir MK, Sheikhi M. Assessment of the anterior loop of mental nerve in an Iranian population using cone beam computed tomography scan. *Dent Res J (Isfahan).* 2017 Nov-Dec;14(6):418-422. doi: 10.4103/1735-3327.218566. PMID: 29238381; PMCID: PMC5713066.
8. Lu CI, Won J, Al-Ardah A, Santana R, Rice D, Lozada J. Assessment of the Anterior Loop of the Mental Nerve Using Cone Beam Computerized Tomography Scan. *J Oral Implantol.* 2015 Dec;41(6):632-9. doi: 10.1563/aid-joi-D-13-00346. PMID: 24552176.
9. Rodricks D, Phulambrikar T, Singh SK, Gupta A. Evaluation of incidence of mental nerve loop in Central India population using cone beam computed tomography. *Indian J Dent Res.* 2018 Sep-Oct;29(5):627-633. doi: 10.4103/ijdr.IJDR_50_17. PMID: 30409944.
10. Vieira CL, Veloso SDAR, Lopes FF. Location of the course of the mandibular canal, anterior loop and accessory mental foramen through cone-beam computed tomography. *Surg Radiol Anat.* 2018 Dec;40(12):1411-1417. doi: 10.1007/s00276-018-2081-6. PMID: 30120507.
11. Moghddam MR, Davoudmanesh Z, Azizi N, Rakhshan V, Shariati M. Prevalence and Length of the Anterior Loop of the Inferior Alveolar Nerve in Iranians. *J Oral Implantol.* 2017 Oct;43(5):333-336. doi: 10.1563/aid-joi-D-16-00212. PMID: 28708475.
12. do Carmo Oliveira M, Tedesco TK, Gimenez T, Allegrini S Jr. Analysis of the frequency of visualization of morphological variations in anatomical bone features in the mandibular interforaminal region through cone-beam computed tomography. *Surg Radiol Anat.* 2018 Oct;40(10):1119-1131. doi: 10.1007/s00276-018-2040-2. PMID: 29785677.
13. Panjnoush M, Rabiee ZS, Kheirandish Y. Assessment of Location and Anatomical Characteristics of Mental Foramen, Anterior Loop and Mandibular Incisive Canal Using Cone Beam Computed Tomography. *J Dent (Tehran).* 2016 Mar;13(2):126-132. PMID: 27928241; PMCID: PMC5139930.
14. Parnia F, Moslehifard E, Hafezeqoran A, Mahboub F, Mojaver-Kahnamoui H. Characteristics of anatomical landmarks in the mandibular interforaminal region: a cone-beam computed tomography study. *Med Oral Patol Oral Cir Bucal.* 2012 May 1;17(3):e420-5. doi: 10.4317/medoral.17520. PMID: 22143718; PMCID: PMC3476108.
15. Apostolakis D, Brown JE. The anterior loop of the inferior alveolar nerve: prevalence, measurement of its length and a recommendation for interforaminal implant installation based on cone beam CT imaging. *Clin Oral Implants Res.* 2012 Sep;23(9):1022-30. doi: 10.1111/j.1600-0501.2011.02261.x. PMID: 22092440.
16. Kieser J, Kuzmanovic D, Payne A, Dennison J, Herbison P. Patterns of emergence of the human mental nerve. *Arch Oral Biol.* 2002 Oct;47(10):743-7. doi: 10.1016/s0003-9969(02)00067-5. PMID: 12356506.
17. Bositykh YY, Turkina AY, Franco RPAV, Franco A, Makeeva MK. Cone beam computed tomography study on the relation between mental foramen and roots of mandibular teeth, presence of anterior loop and satellite foramina. *Morphologie.* 2019;103(341 Pt 2):65-71. doi: 10.1016/j.morpho.2019.04.002. PMID: 31036461.
18. Zmyslowska-Polakowska E, Radwanski M, Ledzion S, Leski M, Zmyslowska A, Lukomska-Szymanska M. Evaluation of Size and Location of a Mental Foramen in the Polish Population Using Cone-Beam Computed Tomography. *Biomed Res Int.* 2019 Jan 2;2019:1659476. doi: 10.1155/2019/1659476. PMID: 30719439; PMCID: PMC6334310.
19. Filo K, Schneider T, Locher MC, Kruse AL, Lübbers HT. The inferior alveolar nerve's loop at the mental foramen and its implications for surgery. *J Am Dent Assoc.* 2014 Mar;145(3):260-9. doi: 10.14219/jada.2013.34. PMID: 24583891.
20. Neiva RF, Gapski R, Wang HL. Morphometric analysis of implant-related anatomy in Caucasian skulls. *J Periodontol.* 2004;75(8):1061-7. doi: 10.1902/jop.2004.75.8.1061. PMID: 15455732.
21. Juan del VL, Grageda E, Gómez Crespo S. Anterior loop of the inferior alveolar nerve: Averages and prevalence based on CT scans. *J Prosthet Dent.* 2016 Feb;115(2):156-60. doi: 10.1016/j.prosdent.2015.06.025.

22. Juan del VL, Grageda E, Gómez Crespo S. Anterior loop of the inferior alveolar nerve: Averages and prevalence based on CT scans. *J Prosthet Dent.* 2016 Feb;115(2):156-60. doi: 10.1016/j.prosdent.2015.06.025. PMID: 26460167.
23. Khan I, Halli R, Gadre P, Gadre KS. Correlation of panoramic radiographs and spiral CT scan in the preoperative assessment of intimacy of the inferior alveolar canal to impacted mandibular third molars. *J Craniofac Surg.* 2011 Mar;22(2):566-70. doi: 10.1097/SCS.0b013e3182077ac4. PMID: 21403569.
24. Watanabe H, Mohammad Abdul M, Kurabayashi T, Aoki H. Mandible size and morphology determined with CT on a premise of dental implant operation. *Surg Radiol Anat.* 2010 Apr;32(4):343-9. doi: 10.1007/s00276-009-0570-3. Epub 2009 Oct 8. PMID: 19812884.
25. Krishnan U, Monsour P, Thaha K, Laloo R, Moule A. A Limited Field Cone-beam Computed Tomography-based Evaluation of the Mental Foramen, Accessory Mental Foramina, Anterior Loop, Lateral Lingual Foramen, and Lateral Lingual Canal. *J Endod.* 2018 Jun;44(6):946-951. doi: 10.1016/j.joen.2018.01.013. Epub 2018 Mar 15. PMID: 29550007.
26. Chandramohan RV, Ramanathan S, Rethinasamy M, Muthulingam V. A comparative study of morphological and morphometric analysis of mental foramen and its clinical importance on human dry mandibles of South Indian population. *JEMDS* 2016;5(74):5439-44.
27. Goyushov S, Tözüm MD, Tözüm TF. Assessment of morphological and anatomical characteristics of mental foramen using cone beam computed tomography. *Surg Radiol Anat.* 2018 Oct;40(10):1133-1139. doi: 10.1007/s00276-018-2043-z. PMID: 29802432.
28. Alsoleihat F, Al-Omari FA, Al-Sayyed AR, Al-Asmar AA, Khraisat A. The mental foramen: A cone beam CT study of the horizontal location, size and sexual dimorphism amongst living Jordanians. *Homo.* 2018 Nov;69(6):335-339. doi: 10.1016/j.jchb.2018.11.003. PMID: 30501895.
29. Aoun G, El-Outa A, Kafrouny N, Berberi A. Assessment of the Mental Foramen Location in a Sample of Fully Dentate Lebanese Adults Using Cone-beam Computed Tomography Technology. *Acta Inform Med.* 2017 Dec;25(4):259-262. doi: 10.5455/aim.2017.25.259-262. PMID: 29284917; PMCID: PMC5723193.
30. Ngeow WC, Yuzawati Y. The location of the mental foramen in a selected Malay population. *J Oral Sci.* 2003 Sep;45(3):171-5. doi: 10.2334/josnusd.45.171. PMID: 14650583.
31. Sheikhi M, Karbasi Kheir M, Hekmatian E. Cone-Beam Computed Tomography Evaluation of Mental Foramen Variations: A Preliminary Study. *Radiol Res Pract.* 2015;2015:124635. doi: 10.1155/2015/124635. PMID: 26609432; PMCID: PMC4644840.
32. Khojastepour L, Mirbeigi S, Mirhadi S, Safaee A. Location of Mental Foramen in a Selected Iranian Population: A CBCT Assessment. *Iran Endod J.* 2015;10(2):117-21. PMID: 25834596; PMCID: PMC4372786.
33. Safaee A, Mirbeigi S, Ezoddini F, Khojastepour L, Navab-Azam A. Buccolingual course of the inferior alveolar canal in different mental foramen locations: A cone beam computed tomography study of an Iranian population. *Int J Appl Basic Med Res.* 2016 Oct-Dec;6(4):262-266. doi: 10.4103/2229-516X.192589. PMID: 27857894; PMCID: PMC5108103.
34. Santini A, Alayan I. A comparative anthropometric study of the position of the mental foramen in three populations. *Br Dent J.* 2012 Feb 17;212(4):E7. doi: 10.1038/sj.bdj.2012.143. PMID: 22349415.