

PREVALENCE AND C-SHAPED ROOT CANAL CONFIGURATION IN LOWER MOLARS IN THE METROPOLITAN REGION, CHILE.

Prevalencia y configuración de conductos en C en molares inferiores de la región metropolitana, Chile.

Fernando Peña-Bengoia.¹
Juan Contreras-San Martín.²
Patricio Meléndez-Rojas.³

AFFILIATIONS:

¹Universidad Andres Bello, Facultad de Odontología, Departamento de Endodoncia, Viña del Mar, Chile.

²Practica privada, Viña del Mar, Chile.

³Universidad Andres Bello, Facultad de Odontología, Departamento de Imagenología Oral y Maxilofacial, Viña del Mar, Chile.

CORRESPONDING AUTHOR:

Fernando Peña-Bengoia. Quillota 980, Facultad de Odontología, Universidad Andres Bello, Viña del Mar, Chile. **Phone:** (56-9) 85481196.

E-mail: fernandopenab@gmail.com

CITE AS:

Peña-Bengoia F, Contreras-San Martín J & Meléndez-Rojas P.

Prevalence and C-shaped root canal configuration in lower molars in the metropolitan region, Chile.

J Oral Res.2022;11(4):1-10.

doi:10.17126/joralres.2022.046

ABSTRACT:

Objective: The aim of this study was to determine the prevalence, demographics, and root configuration of C-shaped canals of mandibular molars by means of cone beam computed tomography in the population of the Metropolitan Region, Chile.

Material and Methods: 912 molars (456 first and 456 second molars) resulting from the analysis of 228 mandibular CT scans were evaluated. The root configuration was established by means of a panoramic reconstruction and axial tomographic sections, classifying the presence and type of canals through the analysis of five sections along the root. Data were statistically analyzed using a 5% confidence interval.

Results: Of the 912 molars analyzed, 70 were classified as C-shaped canals (7.68%), corresponding to 58.33% of those molars that presented fused roots. 95.7% of this root canal configuration was observed in lower second molars, occurring more frequently in females (n=45, 64.29%). 45.65% of the cases that presented C-shaped canals were bilateral and the most frequent configuration was C3 (n=401, 66.63%) according to the Melton classification.

Conclusion: The C-shaped canals of the mandibular molars in the studied population were observed mainly in second molars, showing a clear predilection among females and a high percentage of bilaterality. The presence of fused roots significantly increases the possibility of finding this type of root configuration.

KEYWORDS:

C-shaped canals; cone-beam computed tomography; molars; endodontics; anatomy; prevalence.

RESUMEN:

Objetivo: El objetivo del presente estudio fue determinar, por medio de tomografía computarizada de haz cónico, la prevalencia, demografía y configuración radicular de los conductos en forma de C de molares inferiores en la población de la Región Metropolitana, Chile.

Material y Métodos: 912 molares (456 primeros y 456 segundos molares) resultantes del análisis de 228 tomografías mandibulares fueron evaluados. Mediante una reconstrucción panorámica y cortes tomográficos axiales se estableció la configuración radicular, clasificando la presencia y tipo de conducto por medio del análisis de 5 cortes a lo largo de la raíz. Los datos fueron analizados estadísticamente con un intervalo de confianza del 5%.

Resultados: De los 912 molares analizados, 70 fueron clasificados como conductos en forma de C (7.68%), correspondiendo al 58.33% de aquellos molares que presentaron

raíces fusionadas. El 95.7% de esta configuración de conductos fue observada en segundos molares inferiores, presentándose con mayor frecuencia en mujeres (n=45, 64.29%). El 45.65% de los casos que presentaron conductos en C se manifestaron bilateralmente y la configuración más frecuente observada fue la C3 (n=401, 66.63%) según la clasificación de Melton

Conclusión: Los conductos en forma de C de los molares mandibulares en la población estudiada fueron observados principalmente en segundos molares, marcando una clara predilección por el sexo femenino y un alto porcentaje de bilateralidad. La presencia de raíces fusionadas aumenta significativamente la posibilidad de encontrar este tipo de configuración radicular.

PALABRAS CLAVE:

Conductos en C; tomografía computarizada de haz cónico; molares; endodoncia; anatomía; prevalencia

INTRODUCTION.

Knowing the internal anatomy of teeth plays a key role in endodontic therapy. The great variability of the root canal system (RCS) means that treatment planning, based on the knowledge of tooth anatomy, increases the possibilities of encompassing and treating these variations and thus performing endodontic treatments with a high success rate.¹

C-shaped canals correspond to an anatomical variation that occurs mainly in lower molars and premolars.² Their name derives from the shape that the root canals present when they join partially or totally and are observed in a cross section. This anomaly originates during odontogenesis and is caused by a failure of Hertwig's epithelial sheath, on its buccal and/or lingual surface, causing a cleft that leaves a small thickness of dental tissue in its internal portion.³

This area of smaller thickness and the characteristic shape of these canals pose a challenge for the clinician since, in addition to having to maximize efforts to achieve complete cleaning and/or disinfection of the RCS, they must consider these thin walls during the canal shaping to avoid accidental communication with the periodontium.^{3,4,5}

C-shaped canals were initially classified by Melton *et al.*,⁶ who established three categories: continuous, semicolon, and discrete separation of the canals. Over the years, Fan *et al.*,⁷ redefined this classification, taking into consideration that C-shaped canals may vary along their length. With this, two categories are added to those already described initially: single canal (round or oval) and non-observable canal (generally in areas close to the apex).

The initial planning of root canal treatment is a

key process, especially in complex cases.⁸ Although conventional retro-alveolar radiography provides important data and is routinely used in endodontic treatment, in complex configurations, such as C-shaped canals, it is not capable of providing detailed data to perform an effective treatment.⁹ The use of cone beam computed tomography (CBCT) is an essential tool for the treatment of this type of canals, as it allows the clinician to do a complete and three-dimensional study of the anatomical complexities of the RCS.¹⁰

The widespread use of CBCT has made it possible to analyze C-shaped canals on a larger scale and with a greater degree of precision, obtaining relevant data on the prevalence and configuration of this type of canal in various parts of the world. Global studies report important differences in relation to the prevalence of this anatomical variation, with values ranging from 6.8% in the Brazilian population to 44% in the Chinese population, with an average world prevalence of 13.9%.¹¹ On the other hand, Martins *et al.*,² report a global prevalence of 12%, with values ranging between 8.9% in the European population and 43.1% in the Asian population.

Although there is a significant number of studies on the prevalence of C-shaped canals around the world, literature on this type of canals in the South American population is scarce, mostly limited to the Brazilian population. Taking this into consideration, the aim of the present study is to analyze the prevalence and configuration of C-shaped canals, by means of cone beam computed tomography, in the population of the Metropolitan Region, Chile.

MATERIALS AND METHODS.

This descriptive cross-sectional and observational study was approved by the Scientific Ethics Committee of the School of Dentistry of Universidad Andrés Bello, Viña del Mar, Chile, under resolution 80-21.

The sample size was determined using the known population formula, obtained from the national statistics registry¹² using 95% confidence and 5% significance. The expected prevalence of C-shaped

canals was 10.6%, obtained from the study by Tassoker *et al.*,¹³ determining a sample size of 228 patients.

Imaging Analysis

The sample used in this study was obtained from the Imaging Center at Universidad Andrés Bello, Santiago. All CBCT with bilateral presence of lower first and second molars and complete root formation taken between 2014 and 2019 were considered in the study. All CBCT that showed endodontically treated lower molars, signs of root resorption, intracanal calcification or artifacts that prevented correct visualization were excluded. For the final selection of the sample, a simple random sampling was used until obtaining the 228 CBCT needed for the study.

Image management was performed with iCAT Vision software (Imaging Sciences International, Hatfield, United States), in a darkened room with regulated brightness and contrast. The imaging analysis was performed by a previously calibrated operator using Cohen's Kappa test. For calibration, 10 CBCT were selected, which were analyzed and classified by a radiologist and then analyzed by the operator in two stages. Subsequently, the results were compared between the radiologist and the operator to determine the intra-operator agreement.

The methodology proposed by Nejaim *et al.*,¹⁴ was used for the analysis of root configuration, presence and type of C-shaped canal. By means of a 20.4 mm thick panoramic reconstruction, obtained from the CBCT of each patient, the root configuration was analyzed, classifying the molars according to their morphology (Figure 1).

The presence of C-shaped canals was evaluated at five points at root level. These levels were pre-established by means of standardized sections from a multiplanar reconstruction in an axial view (Figure 2A), classifying each section according to the classification proposed by Melton *et al.*,⁶ (Figure 2B).

The configuration of the canals was considered as C-shaped when simultaneously presenting root

fusion, a longitudinal groove on the lingual or buccal surface, and at least one of the 5 axial cuts classified as C1 or C2.

Data analysis plan

The descriptive statistics of the variables was carried out through an exploratory analysis of the data. The proportions test was used for the comparison of prevalence. The data obtained were analyzed using Stata 11.2 statistical software (StataCorp LLC, Texas, United States) with a significance level of 5%.

RESULTS.

The results of the intra-operator calibration were optimal, with a value of 0.85 and 0.95 for the parameters analyzed. Of a total of 912 molars analyzed, 70 presented a C-shaped configuration, which corresponds to 7.68% of the analyzed sample. When analyzing all the C-shaped canals found, it was observed that 95.7% (n=67) occurred in second molars. Regarding the distribution by gender, a significant prevalence was observed in females (Table 1).

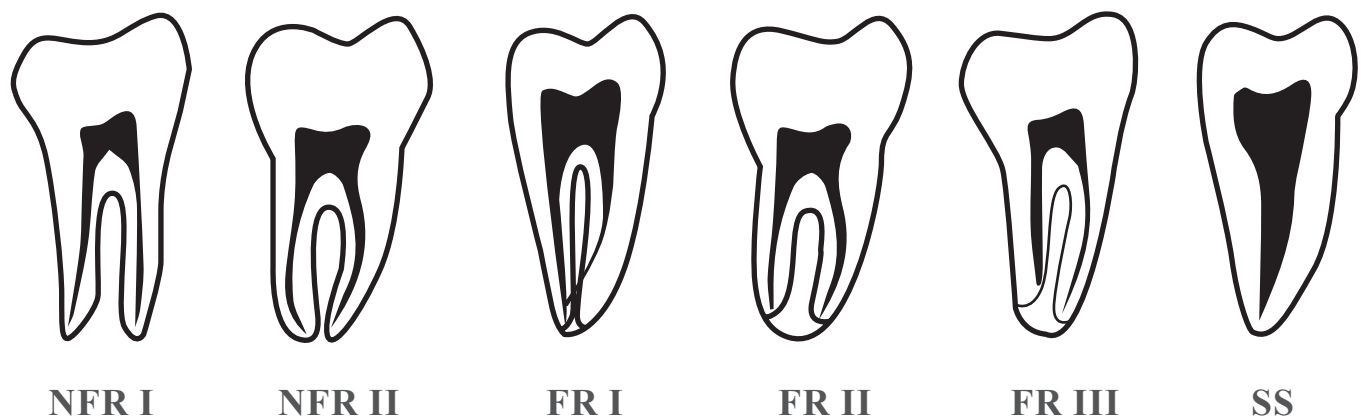
In relation to the distribution by age groups, the highest proportion of C-shaped canals were found in the range of 15-24 years old (8.33% CI95% [6.96-11.06]) followed by those in the range of 25-34 years old (7.42% CI95% [4.53-11.35]) (Figure 3).

A lower proportion of C-shaped canals was observed in the 35-44 and 45-80 age ranges; however, despite the differences, age did not show statistically significant values for any of the groups ($p>0.05$).

Of the total number of patients who presented C-shaped canals, it was observed that 21 of them did so bilaterally (45.65% CI95% [30.90-60.99]). Among these, eight were male and 13 were female, a proportion without significant statistical value ($p=0.1230$).

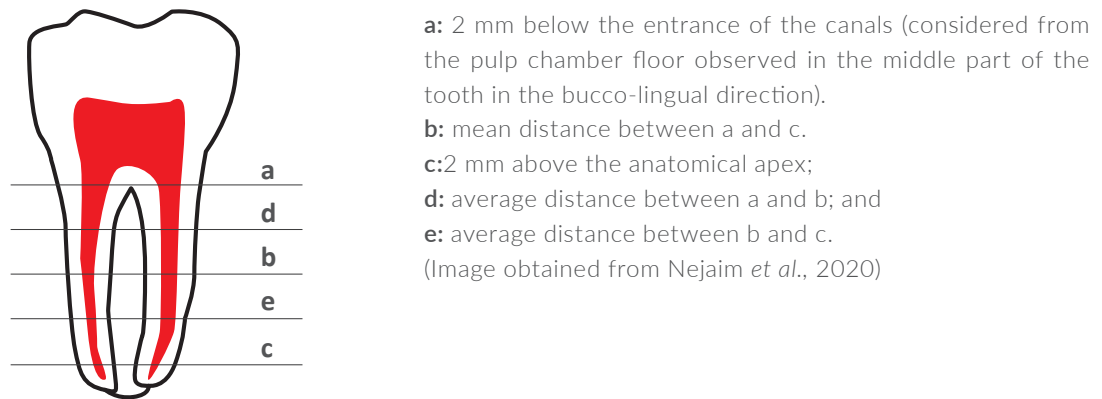
When analyzing the root configuration of molars that presented C-shaped canals, it was observed that 100% of the cases presented some degree of root fusion (Table 2), showing a marked prevalence of the C3 type configuration according to the Melton classification. (Table 3).

Figure 1. Classification of root configuration in panoramic reconstruction.

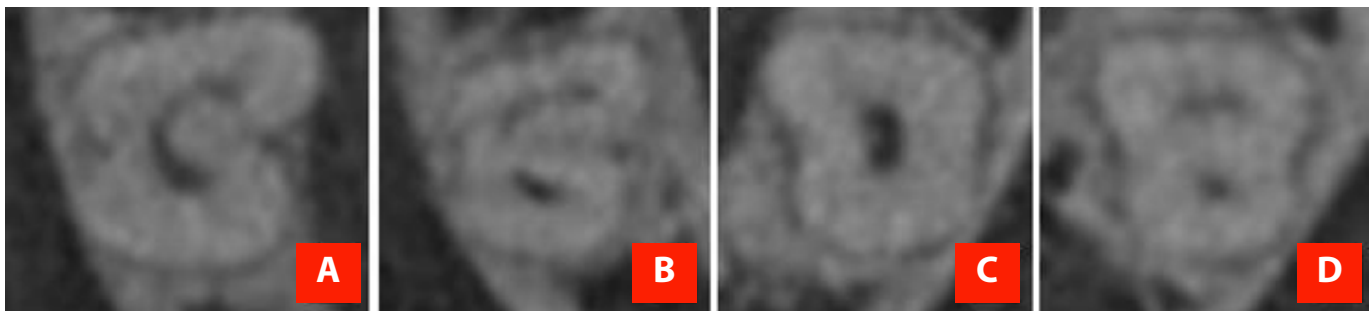


NFR I: Parallel or divergent unfused roots; **NFR II:** convergent non-fused roots; **FRI:** conical roots fused with mesial and distal canals converging apically; **FR II:** conical roots fused with both mesial and distal independent canals up to the foramen; **FR III:** fused conical roots with distal canal curved towards a radiolucent line on its way to the apex and the longest mesial canal towards the apex independently; and **SS:** a conical root fused with a single root canal. (Image obtained from Nejam *et al.*, 2020)

Figure 2. A Cut-off points established to classify C-shaped canals and Melton's classification for C-shaped canals.



a: 2 mm below the entrance of the canals (considered from the pulp chamber floor observed in the middle part of the tooth in the bucco-lingual direction).
b: mean distance between a and c.
c: 2 mm above the anatomical apex;
d: average distance between a and b; and
e: average distance between b and c.
 (Image obtained from Nejaim *et al.*, 2020)



A: C1, "C" continuous; **B:** C2, Semicolon; **C** and **D:** C3, single canal or 2 semicircular canals independent of each other.
 (Image obtained from Peña-Bengoa *et al.*, 2021)

Figure 3. Distribution of lower molars classified as C-shaped according to age range.

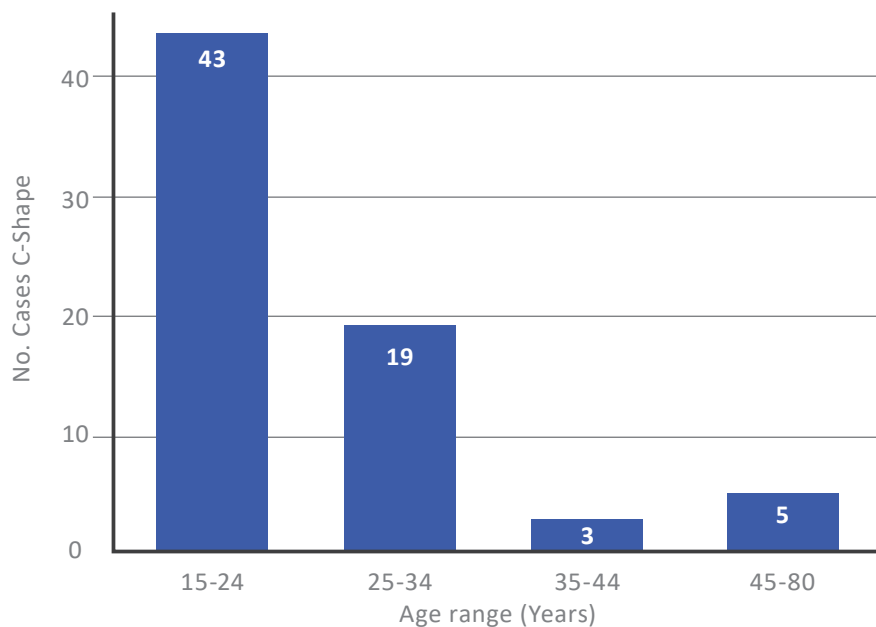


Table 1. Distribution by gender of lower molars classified as C-shaped.

Gender	Total	Percentage (%)	CI95% Male
25	35.71	24.61 – 48.07	
Female	45	64.29	51.93 – 75.39
Total	70	100.00	

CI: Confidence interval

Table 2. Distribution of molars with C-shaped canals according to root configuration.

Root Configuration	Analyzed Samples	C-shaped canals	Percentage with respect to the number of analyzed samples [%] (CI95%)
NFRI	527	0	0
NFR II	265	0	0
FRI, FR II, FR III, and SS	120	70	58.33 (48.98 – 67.26)
Total	912	70	7.68 (6.06 – 9.60)

NFR I: Parallel or divergent unfused roots; NFR II: convergent non-fused roots; FR I: conical roots fused with mesial and distal canals converging apically; FR II: conical roots fused with both mesial and distal independent canals up to the foramen; FR III: fused conical roots with distal canal curved towards a radiolucent line on its way to the apex and the longest mesial canal towards the apex independently; SS: a conical root fused with a single root canal. CI: Confidence interval.

Table 3. Configuration of C-shaped canals at the different levels observed in the axial cuts.

Type		a	b	c	d	e	Total
C1	Number	48	28	4	43	8	131
	Percentage (%)	40.00	23.33	3.33	35.83	6.67	21.83
C2	Number	17	19	3	20	9	68
	Percentage (%)	14.17	15.83	2.50	16.67	7.50	11.33
C3	Number	55	73	3	57	103	401
	Percentage (%)	45.83	60.83	94.17	47.50	85.83	66.63
Total	Number	120	120	120	120	120	600
	Percentage (%)	100.0	100.0	100.0	100.0	100.0	100.0

NFR I: Parallel or divergent unfused roots; NFR II: convergent non-fused roots; FR I: conical roots fused with mesial and distal canals converging apically; FR II: conical roots fused with both mesial and distal independent canals up to the foramen; FR III: fused conical roots with distal canal curved towards a radiolucent line on its way to the apex and the longest mesial canal towards the apex independently; SS: a conical root fused with a single root canal. CI: Confidence interval.

DISCUSSION.

Studies in relation to C-shaped canals show the importance of knowing this type of configuration and the impact that they can have on daily practice depending on the geographical location. Important differences regarding prevalence and configuration can be observed between Western and Eastern countries.^{2,11}

The prevalence of C-shaped canals obtained in the present study was 7.68%, a percentage lower than the world average determined by von Zuben *et al.*,¹¹ who reported a value of 13.9% in 2017. However, when comparing the results from this study with others carried out in South America, it can be observed that they do not differ greatly from the average 6.8% reported in Brazil.¹¹ On the other hand, when comparing these results with other studies carried out in Chile, values of 10.93%,¹⁵ 8.93 %, ¹⁶ and 7.57%¹⁷ have been reported depending on the subpopulation studied. These differences in the results can be attributed to variables in the methodology and to ethnic and/or migratory aspects, considering the current heterogeneity of the resident population in the different regions of the country.

Although the literature shows that this root configuration can occur in premolars, it is most frequently observed in molars.^{2,11,18} In this study, 95.7% of the C-shaped canals were observed in lower second molars. This higher prevalence of second molars has also been reported in studies carried out in Brazil,¹² Saudi Arabia,¹⁸ Israel,¹⁹ and Portugal,²⁰ among others. On the other hand, when analyzing the results obtained regarding the prevalence by gender, a significant predilection among females was observed, a trend that has also been reported in the global studies conducted by von Zuben *et al.*,¹¹ and Martins *et al.*²

In relation to age distribution, the group between 15-24 years old had the highest proportion of C-shaped canals, followed by the 25-34-year-old group. This can be explained by the fact that tooth loss and the progressive obliteration of the canals are greater as age increases,^{21,22} reasons

for which, considering the inclusion criteria of this study, would reduce the possibility of being part of the sample.

The bilaterality of C-shaped canals found in this study was 45.65%, a value similar to other reported in Brazil⁹ and Saudi Arabia.²³ However, it presents important differences with studies carried out in countries such as Mexico²⁴ and China,²⁵ with values of 60% and 81%, respectively. This can be attributed to the fact that in these countries there is a higher prevalence of C-shaped canals, which could mean an increase in the expression of bilaterality.

In the present study, all C-shaped canals were found in molars with some degree of root fusion. These results agree with the studies by Sönmez Kaplan *et al.*,²⁶ and Shemesh *et al.*,¹⁹ who, as in the present study, observed all the C-shaped canals in roots with some degree of fusion. Results such as these should alert the clinician to pay special attention when observing or suspecting a molar with some degree of root fusion since, according to the results reported by Nejaim *et al.*,¹⁴ molars with fused roots are 17.2 times more likely to present C-shaped canals in relation to unfused roots.

When analyzing the configuration of the C-shaped canals along the root path, it was possible to observe that these present variations. However, the type C3 configuration was the most frequently observed, followed by C1 and C2. This distribution in the configuration of the C-shaped canals is consistent with other studies that report a higher prevalence of the C3 configuration over the other types.^{26,19,14}

CONCLUSION.

C-shaped canals of lower molars in the studied population were observed mainly in second molars, showing a clear predilection for females and a high percentage of bilaterality. The presence of fused roots significantly increases the possibility of finding C-shaped canals.

Conflict of interests:

The authors declare no conflict of interests.

Ethics approval:

Approved by the Scientific Ethics Committee of the School of Dentistry of the Universidad Andrés Bello, Viña del Mar. (Number 80-21).

Funding:

Self financed

Authors' contributions:

Conceptualization: Peña-Bengoa F.

Data curation: Contreras-San Martín J.

Formal analysis: Peña-Bengoa F., Contreras-San Martín J.

Funding acquisition: Contreras-San Martín J.

Investigation: Peña-Bengoa F, Contreras-San Martín J, Meléndez-Rojas P.

Methodology: Peña-Bengoa F.

Project administration: Peña-Bengoa F.

Resources: Contreras-San Martín J.

Software: Meléndez-Rojas P.

Supervision: Peña-Bengoa F, Meléndez-Rojas P.

Validation: Peña-Bengoa F, Meléndez-Rojas P

Visualization: Peña-Bengoa F, Meléndez-Rojas P.

Writing – original draft: Peña-Bengoa F, Contreras-San Martín J

Writing – review and editing: Peña-Bengoa F.

Aknowledgements:

None.

REFERENCES.

1. Karobari MI, Parveen A, Mirza MB, Makandar SD, Nik Abdul Ghani NR, Noorani TY, Marya A. Root and Root Canal Morphology Classification Systems. *Int J Dent.* 2021;2021:6682189. doi: 10.1155/2021/6682189. PMID: 33679981; PMCID: PMC7910041
2. Martins JNR, Marques D, Silva EJNL, Caramês J, Mata A, Versiani MA. Prevalence of C-shaped canal morphology using cone beam computed tomography - a systematic review with meta-analysis. *Int Endod J.* 2019;52(11):1556-1572. doi: 10.1111/iej.13169. Epub 2019 Jul 11. PMID: 31215045.
3. Zhao Y, Fan W, Xu T, Tay FR, Gutmann JL, Fan B. Evaluation of several instrumentation techniques and irrigation methods on the percentage of untouched canal wall and accumulated dentine debris in C-shaped canals. *Int Endod J.* 2019;52(9):1354-1365. doi: 10.1111/iej.13119. Epub 2019 Apr 5. PMID: 30897222.
4. Seo DG, Gu Y, Yi YA, Lee SJ, Jeong JS, Lee Y, Chang SW, Lee JK, Park W, Kim KD, Kum KY. A biometric study of C-shaped root canal systems in mandibular second molars using cone-beam computed tomography. *Int Endod J.* 2012;45(9):807-14. doi: 10.1111/j.1365-2591.2012.02037.x. PMID: 2243297
5. Boutsoukis C. Internal tooth anatomy and root canal irrigation. En: *The Root Canal Anatomy in Permanent Dentition.* Cham: Springer International Publishing; 2019.
6. Melton DC, Krell KV, Fuller MW. Anatomical and histological features of C-shaped canals in mandibular second molars. *J Endod.* 1991;17(8):384-8. doi: 10.1016/S0099-2399(06)81990-4. PMID: 1809802.
7. Fan B, Cheung GS, Fan M, Gutmann JL, Bian Z. C-shaped canal system in mandibular second molars: Part I--Anatomical features. *J Endod.* 2004;30(12):899-903. doi: 10.1097/01.don.0000136207.12204.e4. PMID: 15564874.
8. Leonardi Dutra K, Haas L, Porporatti AL, Flores-Mir C, Nascimento Santos J, Mezzomo LA, Corrêa M, De Luca Canto G. Diagnostic Accuracy of Cone-beam Computed Tomography and Conventional Radiography on Apical Periodontitis: A Systematic Review and Meta-analysis. *J Endod.* 2016;42(3):356-64. doi: 10.1016/j.joen.2015.12.015. PMID: 26902914.
9. Ladeira DB, Cruz AD, Freitas DQ, Almeida SM. Prevalence of C-shaped root canal in a Brazilian subpopulation: a cone-beam computed tomography analysis. *Braz Oral Res.* 2014;28:39-45. doi: 10.1590/s1806-83242013005000027. PMID: 25000603.
10. Chogle S, Zuaitar M, Sarkis R, Saadoun M, Mecham A, Zhao Y. The Recommendation of Cone-beam Computed Tomography and Its Effect on Endodontic Diagnosis and Treatment Planning. *J Endod.* 2020;46(2):162-168. doi: 10.1016/j.joen.2019.10.034. Epub 2019 Dec 11. PMID: 31837812.
11. von Zuben M, Martins JNR, Berti L, Cassim I, Flynn D, Gonzalez JA, Gu Y, Kottoor J, Monroe A, Rosas Aguilar R, Marques MS, Ginjeira A. Worldwide Prevalence of Mandibular Second Molar C-Shaped Morphologies Evaluated by Cone-Beam Computed Tomography. *J Endod.* 2017;43(9):1442-1447. doi: 10.1016/j.joen.2017.04.016. PMID: 28734652.
12. Instituto Nacional de Estadísticas. Síntesis De Resultados Censo. INE. 2017. Available at: <https://www.censo2017.cl/descargas/home/sintesis-de-resultados-censo2017.pdf>
13. Tassoker M, Sener S. Analysis of the root canal configuration and C-shaped canal frequency of mandibular second molars: a cone beam computed tomography study. *Folia Morphol (Warsz).* 2018;77(4):752-757. doi: 10.5603/FM.a2018.0040. PMID: 29802711.
14. Nejaim Y, Gomes AF, Rosado LPL, Freitas DQ, Martins JNR, da Silva EJNL. C-shaped canals in mandibular molars of a Brazilian subpopulation: prevalence and root canal configuration using cone-beam computed tomography. *Clin Oral Investig.* 2020;24(9):3299-3305. doi: 10.1007/s00784-020-03207-6. PMID: 31965283.
15. Abarca J, Duran M, Parra D, Steinfort K, Zaror C, Monardes H. Root morphology of mandibular molars: a cone-beam computed tomography study. *Folia Morphol (Warsz).* 2020;79(2):327-332. doi: 10.5603/FM.a2019.0084. PMID: 31322722.
16. Torres A, Jacobs R, Lambrechts P, Brizuela C, Cabrera C, Concha G, Pedemonte ME. Characterization of mandibular molar root and canal morphology using cone beam computed tomography and its variability in Belgian and Chilean population samples. *Imaging Sci Dent.* 2015;45(2):95-101. doi: 10.5624/isd.2015.45.2.95. PMID: 26125004; PMCID: PMC4483626.
17. Peña-Bengoa F, Ibañez C, Erices P, Meléndez P, Cáceres C. Prevalence and configuration of C-shaped canals in lower molars from a Chilean subpopulation. *Braz Dent Sci.* 2021; 24(4).
18. Mashyakhly MH, Chourasia HR, Jabali AH, Bajawi HA, Jamal H, Testarelli L, Gambarini G. C-shaped canal configuration in mandibular premolars and molars: Prevalence, correlation, and differences: An In Vivo study using cone-beam computed tomography. *Niger J Clin Pract.* 2020;23(2):232-239. doi: 10.4103/njcp.njcp_335_19. PMID: 32031099.
19. Shemesh A, Levin A, Katzenell V, Itzhak JB, Levinson O, Avraham Z, Solomonov M. C-shaped canals-prevalence and root canal configuration by cone beam computed tomography evaluation in first and second mandibular molars-a cross-sectional study. *Clin Oral Investig.* 2017;21(6):2039-2044. doi: 10.1007/s00784-016-1993-y. PMID: 27844150.

20. Martins JNR, Mata A, Marques D, Caramês J. Prevalence of C-shaped mandibular molars in the Portuguese population evaluated by cone-beam computed tomography. *Eur J Dent.* 2016;10(4):529-535. doi: 10.4103/1305-7456.195175. PMID: 28042270; PMCID: PMC5166311.
21. Solomonov M, Kim HC, Hadad A, Levy DH, Ben Itzhak J, Levinson O, Azizi H. Age-dependent root canal instrumentation techniques: a comprehensive narrative review. *Restor Dent Endod.* 2020;45(2):e21. doi: 10.5395/rde.2020.45.e21. PMID: 32483538; PMCID: PMC7239687.
22. Kassebaum NJ, Bernabé E, Dahiya M, Bhandari B, Murray CJ, Marcenes W. Global Burden of Severe Tooth Loss: A Systematic Review and Meta-analysis. *J Dent Res.* 2014;93(7 Suppl):205-285. doi: 10.1177/0022034514537828. PMID: 24947899; PMCID: PMC4293725
23. Alfawaz H, Alqedairi A, Alkhayyal AK, Almobarak AA, Alhusain MF, Martins JNR. Prevalence of C-shaped canal system in mandibular first and second molars in a Saudi population assessed via cone beam computed tomography: a retrospective study. *Clin Oral Investig.* 2019;23(1):107-112. doi: 10.1007/s00784-018-2415-0. PMID: 29536188.
24. Vega-Lizama EM, Morales-Ortega EA, Ramírez-Salomón M, Cucina A. Bilaterality and symmetry of C-shaped mandibular second molars in a Mexican Maya and non-Maya population: A CBCT in vivo study. *Int J Morphol.* 2021; 39(2):455–62.
25. Zheng Q, Zhang L, Zhou X, Wang Q, Wang Y, Tang L, Song F, Huang D. C-shaped root canal system in mandibular second molars in a Chinese population evaluated by cone-beam computed tomography. *Int Endod J.* 2011;44(9):857-62. doi: 10.1111/j.1365-2591.2011.01896.x. Epub 2011 May 21. PMID: 21599707.
26. Sönmez Kaplan S, Kaplan T, Sezgin GP. Evaluation of C-shaped canals in mandibular second molars of a selected patient group using cone beam computed tomography: prevalence, configuration and radicular groove types. *Odontology.* 2021.109(4):949-955. doi: 10.1007/s10266-021-00616-1. PMID: 34081247.