

CASE

Dental autologous transplantation: technique optimization of immediate step by step for clinical practice.

Oriental Luiz de Noronha Filho,^{1,2} Claudio Valente,² Fabio Sevilha,¹ Badyr Naddy,¹ Nedson Luiz Fernandes Da Rocha,³ Fabio Valentim.¹

Abstract: Dental transplantation is a treatment used to replace a missing tooth with another tooth. It is autogenous when it comes from the same individual. The aim of this article is to discuss the surgical protocol and present a case study to optimize the technique for the general dental practitioner. The first molars are the first permanent teeth to erupt during infancy, they are teeth most commonly lost among the permanent dentition. The third molars are best suited for this treatment, the treatment should be undertaken as soon as possible, as the patient ages there is decrease in the mesenchymal cells. Whenever possible, the pericoronal bag should be preserved in the removal of the tooth germ or tooth formed. We present a case where the tooth was placed in the receiver socket, taking into account the anatomical orientation of its faces, in infra-occlusion. The contention was made by silk and point "X" on the occlusal graft and fixed to the adjacent teeth with light-cured resin. Transplantation is an excellent alternative for treating the loss of one molar, especially in young patients.

Keywords: Dental Transplantation; Autologous; Third Molar.

INTRODUCTION

There are several factors that cause tooth loss in children and adults (Marzola, 1997). Harland and Miller were the first to describe a protocol for the autogenous transplantation of the first and second molars using the third molars. However, it was Fleming who demonstrated the criteria for its success, while Costich presented the factors for success and failures in performing the transplant (Pires et al., 2002).

There are three ways to classify dental transplants: according to the relationship between the donor and the recipient (*autogenous*); according to the anatomical relationship between the origin of the donated tooth (*isotopic*) and according to the vitality and viability of the transplant (*homovital*) (Apfel, 1954; Miller, 1950).

Dental transplantation can be performed using an immediate technique in a single stage, in which the recipient alveolus is prepared and then the extraction of the tooth to be transplanted is performed. There is also the mediate technique in two stages, the alveolus receptor is prepared surgically in the first stage and 14 days after extraction the transplantation is done (Valente, 2003; Barbieri et al., 2008; Aguiar & Aguiar, 2009; Noronha Filho et al., 2010).

A correct technique must include a plan that considers both the local and systemic factors of the patient, as well as a thorough clinical and radiological evaluation (Cuffari & Palumbo, 1997; Counihan & Hegarty, 1997).



INT J MED
SURG SCI

Affiliation: ¹INNS-Funorte. ²Unifoa. ³IICA.

Corresponding: Oriental Luiz de Noronha Filho. Rua Ângela Maria Scianne, 231, Cruzília. Phone: +903742534656. E-mail: orientalnfilho@gmail.com.

Receipt: 01/07/2019
Revised: 02/06/2019
Acceptance: 02/14/2019
Online: 02/17/2019

Conflict of interests: None.

Ethics approval: None.

Funding: None.

Authors' contributions: All authors carried out the entire case report.

Acknowledgements: None.

doi: [10.32457/ijmss.2018.030](https://doi.org/10.32457/ijmss.2018.030).

It is important that the tooth to be transplanted has two thirds to three quarters of its root length, since the process of pulp revascularization depends on this stage of rhizogenesis.

The objective of this article is to describe step by step the autogenous transplant technique of a third molar into the position of a first molar.

CASE REPORT

After anamnesis, clinical and radiographic examination, a large amount of coronary destruction of tooth 16 was confirmed (*Figure 1*). Due to financial constraints, the initial treatment of a crown was ruled out. Therefore, the extraction of tooth 16 and the immediate transposition or auto-transplantation of tooth 18 were proposed. Clarifications on the risks, benefits, prognosis, post-operative care and dental terms used were provided to the patient through informed consent.

The proposed surgical technique does not involve any dental sectioning, so an osteotomy was necessary for molar extraction. This must be performed with care, due to the proximity of anatomical structures, to avoid any possible accidents (*Valente, 2003*). After performing the asepsis and antisepsis, we performed:

1. Anesthesia is used to block the regional trunk; high tuberosity, posterior superior alveolar nerves and palatine nerves. Anesthetic complementation is used in the vestibular fundus with an emphasis on the mesio-vestibular root of the upper first molar.

2. Incision of the fibro-mucosa with a number 12 scalpel, starting in the tuberosity region, followed by a number 15 scalpel, passing through the center of the crest and extending towards the intrasulcular region, until it was distal to the second pre-molar.

3. The syndesmotomy and the displacement of the flap are performed using a number 7 spatula. This flap should be moved along the periosteum upwards and maintained with a Minnesota retractor. The cooperation of the patient in keeping the oral cavity partially open to enable visualization and access to the region is essential.

4. The dislocation of the first molar using elevators should be done in a rather cautious way in order to preserve the remaining alveolar structures. (*Figure 2*)

5. After avulsion of the first molar, it is necessary to prepare the remaining alveolus with a Lucas curette and irrigate with an abundant physiological serum.

6. Extraction of the third molar is performed using an osteotomy that covers both the occlusal surface and the vestibular surface. The actual avulsion is performed from an elevated position in the interdental septum between the upper third and second molars. This elevator is placed perpendicularly and is moved using a twisting action. The transposition and insertion into the alveolus receptor is performed with great care to avoid trauma to the Sharpey's fibers. The infra-occlusal positioning of the transplanted molar was deliberate as it has a better prognosis. (*Figure 3*)

7. Suture of the donor region.

8. Suture in "X" on the coronary surface of the element by transplanting using silk thread 4.0.

9. Fixation with light-cured resin and a nylon suture on the vestibular face of the transplanted molar.

10. Guidance on hygiene care and postoperative medication with: Cephalexin 500 mg, Meloxicam 7.5 mg, Dexamethasone 4 mg and Toragesic 10 mg. The patient was monitored for 15 days. (*Figure 4*)

11. Return of the patient after six months, for clinical and radiographic evaluation. (*Figure 5*)

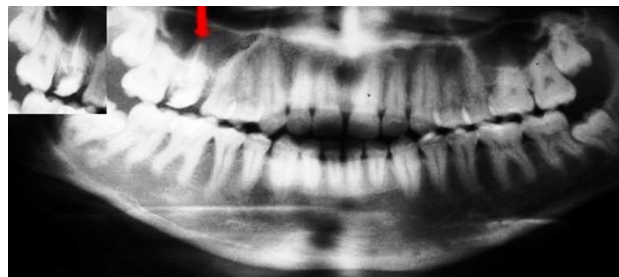

Figure 1: Panoramic radiograph of teeth 16 and 18.

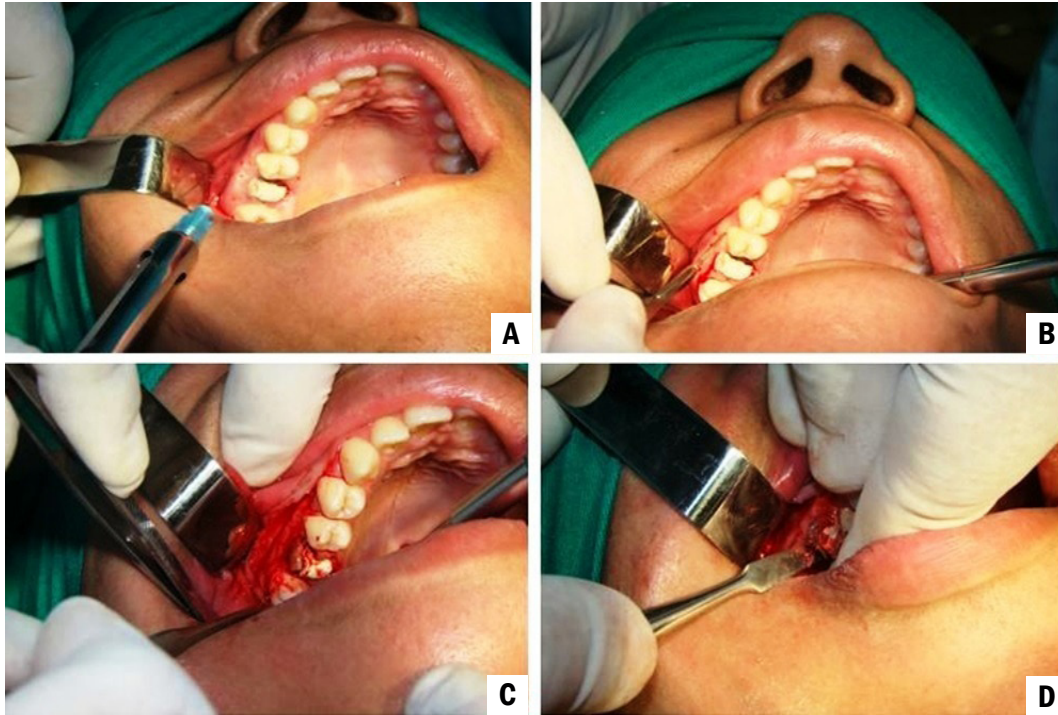


Figure 2: A) Anesthesia. B) Incision. C) Extension of the incision until maxillary tuberosity. D) Extraction of tooth 16.

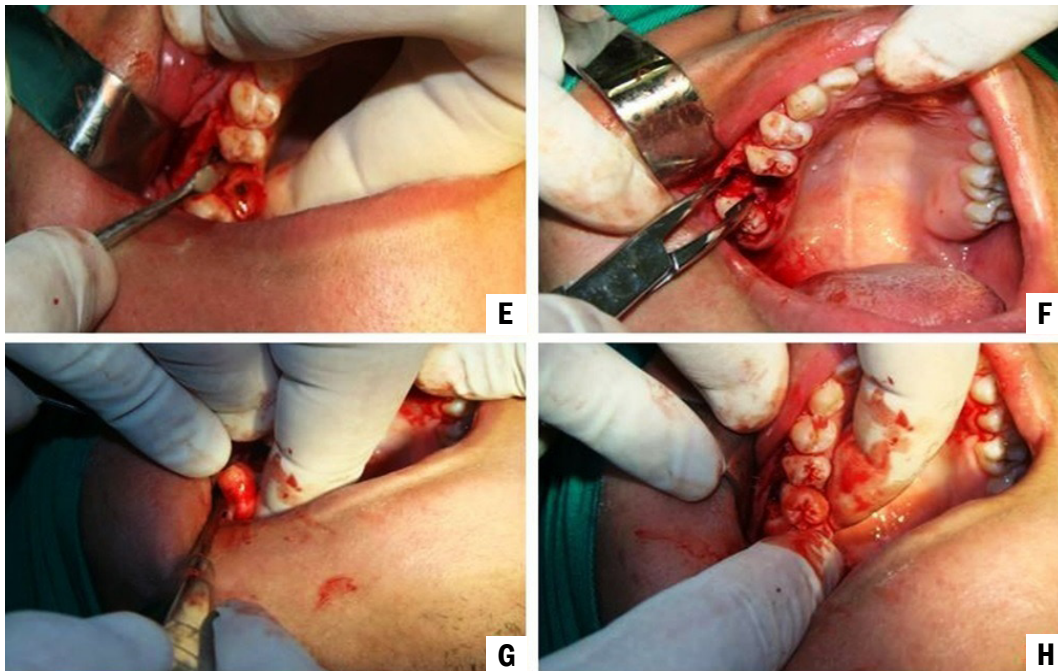


Figure 3: E) Avulsion of tooth 16; F) Preparation of the alveolus receptor; G) Avulsion of tooth 18; H) Insertion of tooth 18 in alveolus receptor, respecting vestibular-palatine orientation.

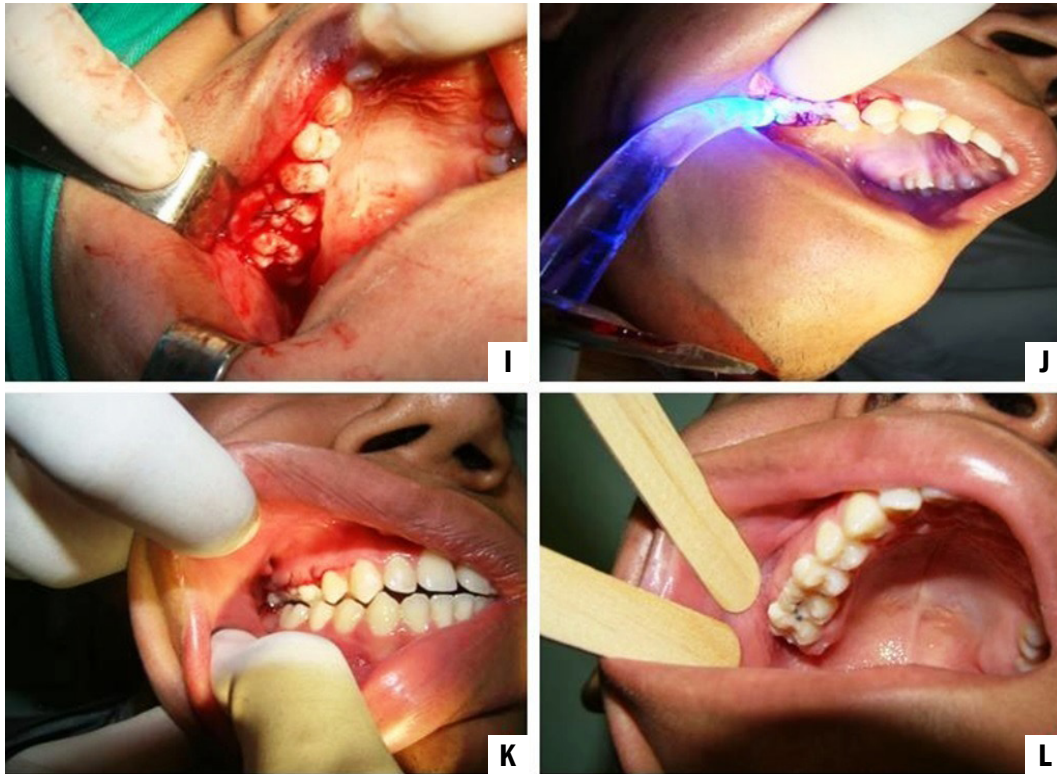


Figure 4: I) Suture in “X”; J) Fixation of trasplanted teeth onto the surrounding teeth with light-cured resin, aimed at leaving the trasplanted tooth in infra-occlusion; K) Final appearance of the procedure; L) Return of the patient after 15 days.

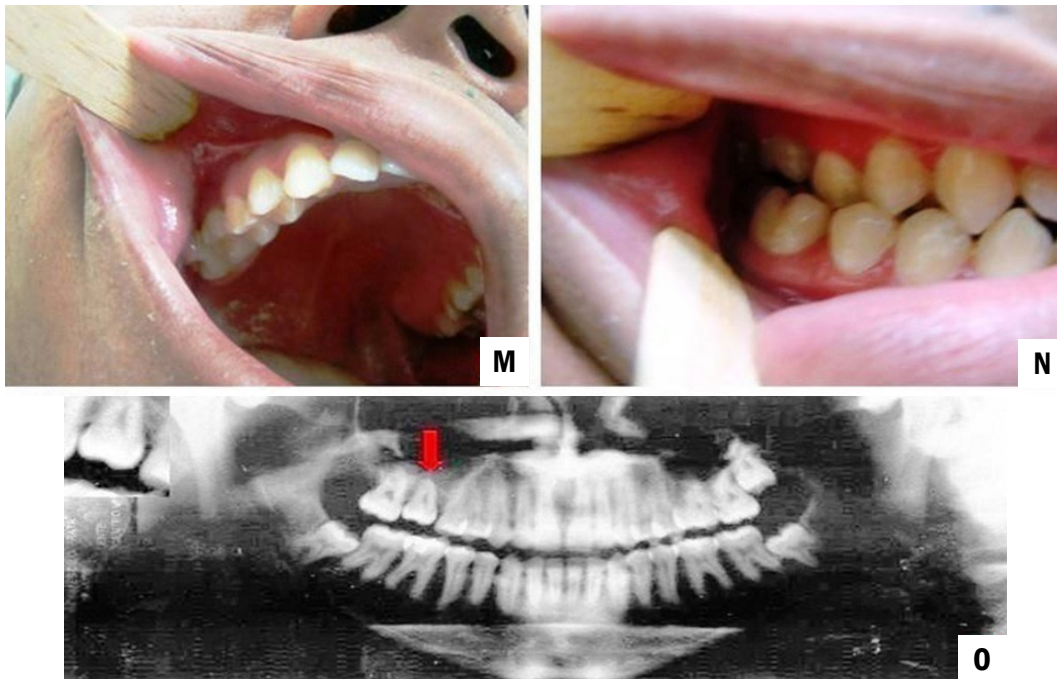


Figure 5: M and N) Return after six months; O) Panoramic radiograph six months after the trasplant procedure. Revealing tooth 18 and its pulp chamber.

DISCUSSION

Andreasen and his team were pioneers in showing the results of autogenous transplants, based on the technique described by Slagsvold and Bjercke (Roldi, 2006). Dental autologous transplantation is a clinical procedure that has been carried out successfully in oral rehabilitation (Kahnberg, 1987). The third molar transplant is most commonly used for the replacement of first and second molars (Andreasen, 1994).

The success of the autogenous transplant technique depends on a series of multifactorial relationships. According to John Hunter, autogenous transplants should be based on the viability and preservation of the periodontal ligament, which determines the success of reimplantation and transplantation (Andreasen, 1994; Clokie et al., 2001; Consolaro & Pinheiro, 2008).

The stage of root formation is very important for the indication and realization of the transplant. The dental germ must have undergone at least a third of its complete root formation to provide stability in the new alveolus. The ideal time to perform the dental transplant is when root development has reached half to two thirds of the total root length and the apical foramen is still open (Valente, 2003; Kahnberg, 1987; Consolaro & Pinheiro, 2008; Sebben et al., 2004; Macedo et al., 2003).

However, many authors report success in dental transplants with complete root formation. However, in fully formed teeth the tissues are mature, fibrous and denser than embryonic or newly formed tissues (Marzola, 1997; Valente, 2003; Marzola et al., 2007).

Medeiros (2003) recommended the use of rotary instruments for the preparation of the receptor alveolus. However, Valente (2003) describes that this technique reduces the success rate due to the heat caused by the rotary instrument.

Moss (1968) stated that endodontic therapy must be adopted during apical alterations, since performing it before or after the autogenous transplant increases the susceptibility to reabsorption. Rios (1993) indicated using endodontic treatment if there are any clinical symptoms of pulpal necrosis, periapical inflammation and progressive internal and/or external resorption.

Andreasen (1994) pointed out that the transplanted

tooth must return to its function as soon as possible, since functional stimulus can prevent or eliminate the occurrence of ankylosis, preventing any alterations to the fibers of the periodontal ligament. In addition, this prolonged fixation time would be directly related to an increase in root resorption. The transplanted tooth must be fixed in place for the period of two weeks, this can be rigid or semi-rigid.

For the success of the therapy the patient's willingness to participate is extremely important, the patient must be willing to attend periodic reviews and radiographic control examinations. The technique should only be indicated in patients who are willing and who express the intention of collaborating with the necessary follow up (Valente, 2003; Zambrano et al., 2002).

REFERENCES

- Aguiar E, Aguiar O. Transplante de germe dental. *Diálogos e Ciência. Revista da Rede de Ensino FTC.* 2009; 3(9).
- Andreasen JO. *Atlas de Reimplante e Transplante de Dentes.* São Paulo: Médica Panamericana; 1994.
- Apfel H. Autoplasty of enucleated prefunctional third molars. *J Oral Surg.* 1950; 8:289-96.
- Barbieri AA, Gracio ACMM, Agostini R, Rocha PB, Carvalho KS, Júnior ED. Cirurgia de transplante autógeno pela técnica imediata. *Rev Cir Traumatol Buco-Maxilo-Fac.* 2008; 8(3): 35-40.
- Clokie CML, Yau DM, Chano L. Autogenous tooth transplantation: an alternative to dental implant placement. *J Can Dent Assoc.* 2001; 67:92-96.
- Consolaro A, Pinheiro TN. Transplantes autógenos dentários: uma solução para casos ortodônticos e uma casuística brasileira. *Rev Dental Press Ortodon Ortop Facial.* 2008; 13(2):23-28.
- Counihan DR, Hegarty DJ. In defence of transplants: a case report. *Dent Update.* 1997; 24(4): 138-42.
- Cuffari L, Palumbo M. Transplante de germe de 3 molar. *J Bras Odontol Clin.* 1997; 1(2): 23-7.
- Kahnberg KE. Autotransplantation of teeth. *J Oral Maxillofac Surg.* 1987; 16(5):577-85.
- Macedo JC, Medeiros PJ, Silva JS, Almeida RC. Autotransplante de germes de terceiros molares: relato de dois casos. *Rev Bras Odont.* 2003; 60:24-26.
- Marzola C. *Transplante & Reimplantes.* 2 ed. São Paulo: Pancast; 1997
- Marzola C, Wolfgang SR, Lopes JTF. Transplante Autógeno de Germe de terceiro molares inferiores, para de Primeiro Molares Inferiores. Available at: http://www.actiradentes.com.br/revista/2007/textos/26_Revista_ATO-Transplantes_de_germes_de_terceiros-2007.pdf.

Medeiros PJ. Cirurgia dos dentes inclusos. Capítulo 11 - Aproveitamento de dentes inclusos. 1ª Edição. Rio de Janeiro: Editora Santos; 2003.

Miller HM. Transplantation. Case report. J Amer Dent. 1950; 40:237-8.

Moss JP. Autogenous transplantation of maxillary canines. J Oral Surg. 1968; 26(12): 775-83.

Noronha Filho OL, Zefiro AL, Souza CM, Kozlowiski K, Valente C. Transposição autógena de terceiro para primeiro molar. In: 28º Congresso Internacional de Odontologia de São Paulo. São Paulo: Anais do 28º CIOSP; 2010.

Pires MSM, Giorgis RS, Castro AGB, Beltrame J, Saurensing F. Transplante autógeno de germe de terceiro molar inferior com rizogênese completa para alvéolo de primeiro molar inferior. Rev Bras Cir Implant. 2002; 34:157-163.

Rios CHN. Transplante dental autógeno de terceiros molares. Rev Científica Cebios. 1993; 1(2):16-23.

Roldi A. Características epidemiológicas, clínicas e radiográficas e suas implicações terapêuticas e prognósticas a partir de casuística com 91 pacientes submetidos a transplantes dentários autógenos e acompanhados ao logo de 21 anos [Thesis Pós-Doutorado em Odontologia]. São Paulo: Universidade de São Paulo; 2006.

Sebben G, Castilhos MDS, Silva RFC. Transplante autógenos de terceiro molares inclusos. Revista da ADP-PUCRS. 2004; 5:109-11.

Valente C. Técnicas Cirúrgicas Bucais e Maxilofaciais. 2 ed. Rio de Janeiro: Revinter. Ltda.; 2003.

Zambrano CBB, Isolan TMP, Renon MC, Rech DF. Transplante autógeno-caso clínico: avaliação clínico-radiográfica. J Bras Odontol Clin. 2002; 18:40-43.