



## Displasia folicular do pelo preto em cão – relato de caso

*Black hair follicular dysplasia in a dog – case report*

Isielle Da Nóbrega Rodrigues<sup>1</sup>, Alexandre Tavares Camelo Oliveira<sup>2</sup>, Breno Queiroz Pinheiro<sup>3</sup>, Tiago Cunha Ferreira<sup>4</sup>, Diana Célia Sousa Nunes-Pinheiro<sup>5</sup>

**Abstract:** Black-hair follicular dysplasia (BHFD) is a hereditary genetic disease that leads to the occurrence of cutaneous changes in the skin and hair in areas of black hair coverage, such as hypotrichosis, alopecia, melanoderma and scaling. Since it is a rare cutaneous disease, the aim of this work is to report a case of BHFD in a Pinscher dog, aging approximately 6 years old, in Fortaleza. The dog presented diffuse hypotrichosis in the dorsolateral, neck and limb regions since it was 8 months of age. Parasitological exams, fungal culture, dosage of thyroid stimulating hormones (TSH) and thyroxine (T4), trichogram and skin biopsy, for histopathological examination were performed. The results were negative for infectious, parasitic or endocrine diseases, and in association with macroscopic findings, the animal was diagnosed with BHFD. The treatment was based on the use of supportive therapy, an end to prevention the occurrence of secondary infections. It is concluded that BHFD is a dermatological condition present in the clinical routine, suggesting the attention of the Veterinarian in order to improve the identification of patients affected by the disease.

**Key-words:** genetical diseases, hypotrichosis, alopecia, melanin, canine skin diseases.

**Resumo:** A displasia folicular do pelo preto é uma doença genética e hereditária que leva ao aparecimento de alterações cutâneas em pele e pelos de áreas de pelame preto, como hipotricose, alopecias, melanodermia e descamações. Por tratar-se de uma afecção cutânea rara, o objetivo deste trabalho é relatar um caso de displasia folicular do pelo preto em uma cadela da raça Pinscher, de aproximadamente 6 anos de idade, em Fortaleza (CE). O animal chegou à clínica apresentando hipotricose difusa em regiões dorsolateral, pescoço e membros desde os 8 meses de idade. Foram solicitados exames parasitológicos, cultura fúngica, dosagem dos hormônios estimulante da tireóide (TSH) e tiroxina (T4) livre, tricograma e biópsia de pele para exame histopatológico. Os exames apresentaram resultados negativos para doenças infecciosas, parasitárias ou endócrinas e, em associação com achados macroscópicos, o animal foi diagnosticado com displasia folicular do pelo preto. O tratamento se baseou no uso de terapia de suporte, a fim de prevenir o aparecimento de infecções secundárias. Conclui-se que a displasia folicular do pelo preto é uma condição dermatológica presente na rotina clínica, sugerindo a atenção do Médico Veterinário para melhorar a identificação dos pacientes acometidos pela doença.

**Palavras-chave:** doenças genéticas, hipotricose, alopecia, melanina, dermatopatias caninas.

<http://dx.doi.org/>

Recebido em 21.1.2020 Aceito em 30.4.2023

\*Autor Correspondente: E-Mail: isiellemedv@hotmail.com.

<sup>1</sup> - Graduando em Medicina Veterinária, Faculdade de Veterinária (FAVET), Universidade Estadual do Ceará (UECE), isiellemedv@hotmail.com.

<sup>2</sup> - Graduando em Medicina Veterinária, Faculdade de Veterinária (FAVET), Universidade Estadual do Ceará (UECE), alexandretco@hotmail.com.

<sup>3</sup> – Professor de Medicina Veterinária, Universidade Maurício de Nassau (UNINASSAU), brenoqpinheiro@gmail.com.

<sup>4</sup> - Professor de Medicina Veterinária, Faculdade de Veterinária (FAVET), Universidade Estadual do Ceará (UECE), [tiago.cunha@uece.br](mailto:tiago.cunha@uece.br).

<sup>5</sup> - Professora de Medicina Veterinária, Faculdade de Veterinária (FAVET), Universidade Estadual do Ceará (UECE), diana.pinheiro@uece.br.

## 1. Introduction

Black hair follicular dysplasia (BHFD) is a rare skin disease that affects dogs with bicolor or tricolor coat. These animals develop alopecia only in areas of black hair coverage. Usually, such changes occur at an early age, with no gender predilection (CRUZ et al., 2015). The pathogenesis of this dysplasia is not fully understood, but it is known that a primitive problem exists in the hair follicle of genetic origin (FERREIRA et al., 2007). As follicular dysplasias are considered to be of genetic-hereditary basis, purebred dogs show strong racial predispositions, with several predisposed breeds mentioned in the literature. However, the disease has also been reported in crossbred dogs (GROSS et al. 2005; SCOTT et al., 2001).

The clinical signs are nonspecific and the animals are characterized by fractured, opaque, dry and dull hairs, hypotrichosis in varying degrees and scaling (BOMHARD et al., 2006). There may also be the development of secondary dry seborrhea and pyoderma (CARDOSO et al., 2003). The diagnosis of BHFD is based on the findings of the

histopathological analysis of the cutaneous lesions and the trichogram (SCOTT et al., 2001), in association with the clinical history of changes in the areas covered by black fur. The main microscopic changes consistent with BHFD is the accumulation of melanin pigments dispersed in the dermis, epidermis, hair follicle and hair shaft (FERREIRA et al., 2007).

Although BHFD has no specific treatment, supportive therapies can be instituted and, in the case of secondary infections, the use of antimicrobial therapies must be associated (GROSS et al., 2005).

Since it is a rare disease that affects the skin of dogs, this study aims to report a clinical case of BHFD in a Pinscher dog, seen at the Hospital Veterinarian Sylvio Barbosa Cardoso (HVSBC) in Fortaleza (CE).

## 2. Materials and Methods

At the HVSBC, located in Fortaleza (CE), a female Pinscher dog, aging approximately 6 years old, weighing 3,200 kg, with a history of diffuse hair loss in the dorsolateral region, neck, head and

limbs.

These changes started after 8 months of age, with a progressive

evolution of hair loss over the years (Figure 1).




Figure 1 – (A and B) Pinscher dog, 8 months old, with normal clinical appearance of the coat, which is the age the skin lesions appear. (C) Pinscher dog, 6 years old, with diffuse hypotrichosis in dorsolateral, neck and limbs.

According to the provided history, the animal has always presented evident lesions on the skin and sensitivity to external factors, such as physical and chemical skin aggressions. She was taken to other veterinarians for dermatological complaints and has been submitted to some treatments based on antifungal shampoos and ointments for suspecting dermatophytosis, showing improvement initially, but reporting a consequent worsening after the end of

treatment. During anamnesis, it was also reported the absence of lesions in contactant animals or puppies in the same litter.

During the physical examination, the animal was alert, the body condition score 4/9 according to the WSAVA (World Small Animal Veterinary Association) body condition classification, rectal temperature 38.2°C, normohydrated, mucous membrane with normal color, non-palpable lymph

nodes, normal pulmonary and cardiac auscultation. Upon dermatological examination, foci of melanoderma and scattered achromatic macules,

hypotrichosis and alopecia, parched hair and vesicles were noted in the areas of black fur, with absence of these signs in the areas of lighter fur (Figure 2).

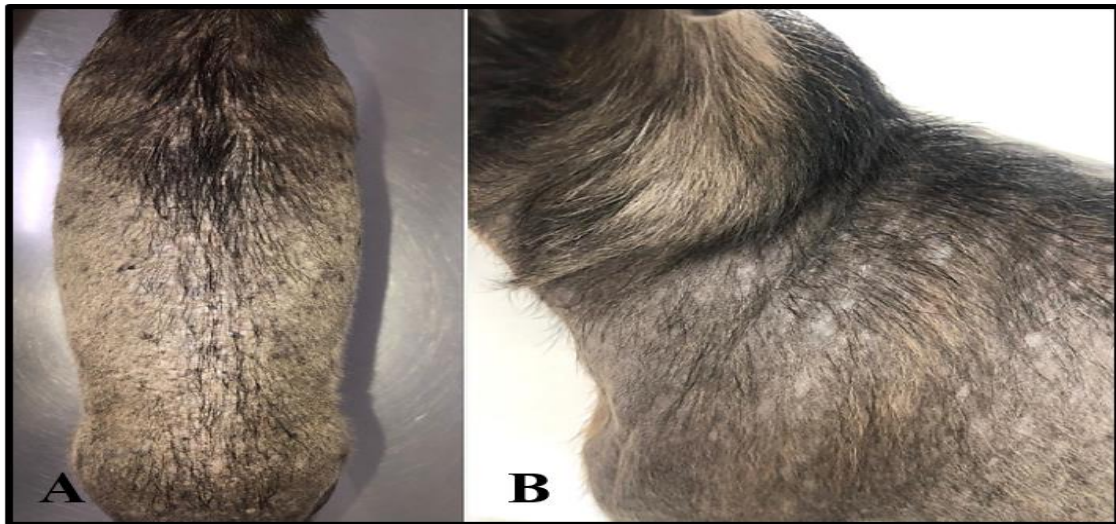


Figure 2 – (A) View of the patient's dorsal region. There is intense hypotrichosis and small foci of hyperpigmentation of the skin (melanoderma). (B) Lateral view of the cervical and scapular region. There is intense hypotrichosis and small foci of achromic macules.

Based on anamnesis, physical and dermatological exams, BHFD was suspected. Thus, complementary exams were requested to rule out other diseases, such as demodicosis, dermatophytosis, pyoderma and alopecia caused by endocrine diseases.

The parasitological examination was performed using acetate tape and skin scraping method. Hair samples were also collected to perform fungal culture of dermatophytes and trichographic examination. Blood samples were collected for hormonal dosing of thyroid

stimulating hormones (TSH) and thyroxine (T4). Skin biopsies in regions of complete skin alopecia were collected and fixed with 10% formalin for histopathological evaluation.

### 3. Results and Discussion

BHFD is an uncommon disease and little reported in the literature. It is known that the primitive problem in the hair follicle is a genetic-hereditary alteration, which causes the impaired transport of melanosomes and leads to pigmentation irregularities (Mecklenburg et al, 2009) and

accumulation of pigment in the melanocytes of the bulb region. This accumulation causes a compression in the cells of the germinal matrix, clinically culminating in the appearance of hair depigmentation, hypotrichosis and alopecia (BOMHARD et al., 2006).

By presenting a genetic-hereditary character, it is believed that it has a predilection for purebred animals, being Collie, Border Collie, Beagle, Basset Hound, Papillon, Saluki, Jack Russell Terrier, American Cocker Spaniel, Cavalier King Charles Spaniel, Dachshund, Gordon Set the breeds cited as predisposed (SCOTT et al., 2001).

The Dobermann and Pinscher breed are also predisposed to BHFD and other dysplastic follicular diseases, such as color dilution alopecia (CDA), and in both it is possible to result in abnormalities of the coat and obtain abnormal characteristics in tricography

(RICHMAN & GRIFFIN, 2018).

According to Ferreira et al. (2007), the main histopathological changes of BHFD are moderate epidermal and follicular orthokeratotic hyperkeratosis, acanthosis, follicular dysplasia, inactive hair follicles in telogen stage, follicular atrophy, epidermal melanocytes full of melanin and macromelanosomes in the epithelium and in the extracellular matrix.

Based on the histopathological findings and clinical presentation, as well as in the absence of others concomitant illnesses, the dog was diagnosed with BHFD. In trichogram, an irregular accumulation of melanin (macromelanosomes) was observed throughout the hair and, also, degeneration in the bulb region, with loss of differentiation between the medullary and cortical regions (Figure 3).

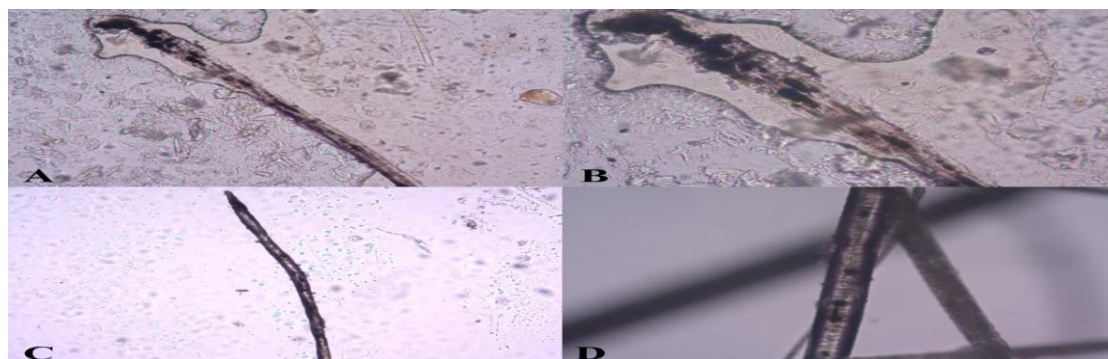


Figure 03 - Trichographic examination of the hair in the affected areas. (A and B) Hair showing macromelanosomes in the follicular bulb, causing deformity of the hair structure. Magnification of 100x and 400x, respectively. (C and D) Telogen hair. Macromelanosomes

distributed in the cortical and medullary hairy regions. Magnification of 100x and 1000x, respectively.

In the histopathological sections, it was possible to observe the epidermis with the presence of macromelasomes. The hair follicle was moderately atrophied and hyperkeratotic, with an accumulation of melanin inside and around of it, as well as in the epidermis (Figure 04).

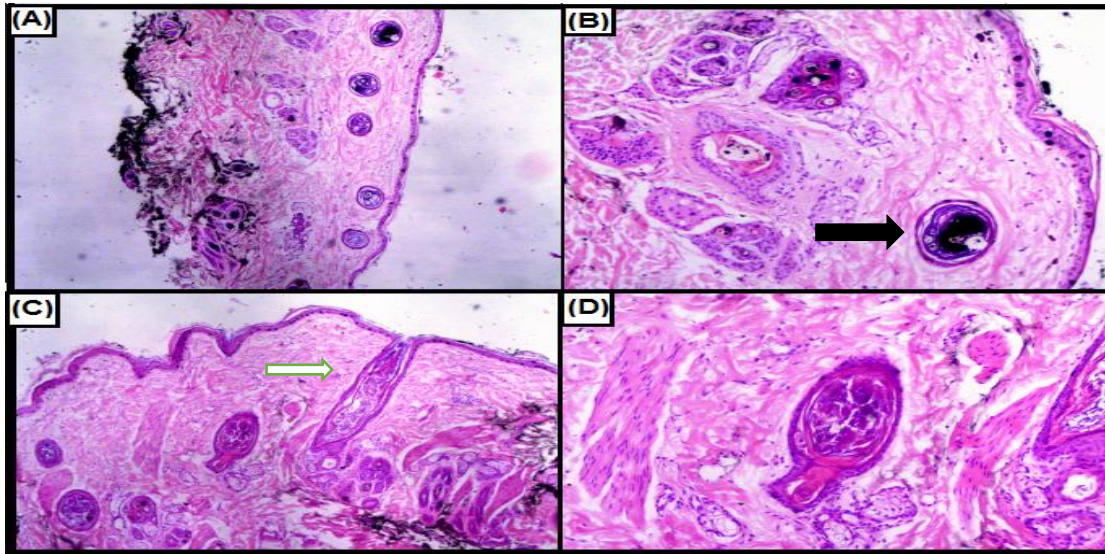


Figure 04 - Histopathological sections of the skin. It is possible to observe in figures (A) and (B) atrophic hair follicles with accumulation of melanin known as “keratotic plugs” (black arrow) and macromelasomas in the epidermis. Magnification of x40 and x100, respectively. In (C) it is possible to notice the excess of keratinous material (white arrow) in the hair follicle and mild orthokeratotic hyperkeratosis. 100x magnification. In (D), a follicle in telogenization stands out in the center of the image. 200x magnification.

The patient began to show changes as a puppy and the lesions progressively increased. The literature mentions that dogs with BHFD are born with normal coat. However, due to the fur shedding starting after the fourth week of life, black hair repilation is compromised (MILLER et al., 2013). The first notable change in most cases is the loss of brightness of the black hair and then there is progressive loss, until it

progresses to complete alopecia (MILLER et al., 2013). As it is a rare disease with nonspecific clinical signs, it was necessary to discard differential diagnoses and comorbidities (CHAVES et al., 2007; MÜNTENER et al., 2012) in order to establish the alopecia main cause. Dermatophytosis are fungal infections that affect skin, hair and nails, compromising and weakening these organs. As a result, the hair grows, but

breaks easily near the surface of the skin, resulting in areas of alopecia (CHAVES et al., 2007; LIMA & STELLA, 2021). With these changes, it is essential to perform specific tests to discard this skin disease.

Regarding the differential diagnosis for endocrine diseases, such as hypothyroidism, this must be done because these diseases cause alopecia due to an interruption in the normal hair growth cycle, stopping in the telogen phase (COSTA et al., 2016). Such hairs fall without replacement, similar to what happens in BHFD. However, in endocrine disorder, when the hormonal abnormality is corrected, there is a return to the anagen phase, which does not occur in BHFD (MÜNTENER et al., 2012; COSTA et al., 2016).

These common causes of alopecia and hypotrichosis were ruled out through complementary tests. The parasitological examination of the skin and the fungal culture of dermatophytes showed negative results, as well as the TSH and T4 levels that were within the reference values for the specie (0.32 ng/mL and 1.49 ng/mL, respectively).

It is common for animals with BHFD to present secondary alterations such as pyoderma and dry seborrhea (CARDOSO et al., 2003). In the

described case, the animal did not have these lesions at the time of the diagnosis, although it has been reported that the dog has already had some episodes of lesions associated to superficial pyoderma. This information justifies the improvement after the institution of antimicrobial and moisturizing therapies (CRUZ et al., 2015).

Although there is no specific treatment for this disease, some studies report the possibility of BHFD being attributed to a deficit in the melatonin-stimulating hormone (MSH), since it participates in the regulation of hair growth and protection and, when missing, leaves the cells of the hair matrix exposed to the toxicity of melanin precursors. In these studies, melatonin was used, at a dose of 3 to 6 mg/animal, BID, and partial hair replacement was successful in approximately 50% of cases (FERREIRA et al., 2007).

Other authors, in cases of dysplastic hair diseases, recommends replacement with omega-3 daily for 30 days, weekly baths with shampoo containing urea and glycerin and the use of moisturizer based on macadamia oil, ceramide and silicones after baths (LOPES et al., 2017). In a study carried out with a crossbreed dog with CDA, there was a considerable reduction in the

flaking presented following the proposed protocol, after two months (LOPES et al., 2017). In cases where the diagnosis is BHFD, because both diseases have similar histopathological changes, it is possible to use omega-3 as well.

As the patient did not have infectious conditions, moisturizing shampoo and skin barrier replenishers were prescribed in order to improve the quality of the skin and prevent recurrences of pyoderma (CRUZ et al., 2015; GROSS et al., 2005). In addition, omega-3 supplements have also been recommended. To date, there has been no worsening of the cutaneous clinical condition, with the previously prescribed therapy being maintained.

#### 4. Conclusion

From the above, it can be concluded that black hair follicular dysplasia is a dermatological condition present in the clinical routine, suggesting the attention of the Veterinarian to adopt appropriate diagnostic protocols, in order to improve the identification of patients affected by the disease. Since it does not have a specific therapeutic protocol, the disease management aims at the control of skin hydration and prevent secondary infections.

#### 5. References

BOMHARD, W.V.; MAULDIN, E.A. Black hair follicular dysplasia in Large Münsterländer dogs: clinical, histological and ultrastructural features. **Veterinary Dermatology**, v. 17, n. 03, p. 182-188, 2006.

CARDOSO, M.J.L.; FRANCO, S.R.V.S.; FABRIS, V. Displasia folicular em cão: Hair follicular dysplasia. **Ciência Rural**, v. 33, n. 5, p. 949-951, 2003.

CHAVES, L.J.Q.; BRILHANTE, R.S.N.; CORDEIRO, R.A.; MONTEIRO, A.J.; SIDRIM, J.J.C.; ROCHA, M. F. G. Circular alopecia in dogs: is it really ringworm? **In: Dermatômicoses em cães e gatos: avaliação do diagnóstico clínico-laboratorial e dos aspectos epidemiológicos em uma população de portadores de lesões alopecias circulares**. 88f. Fortaleza, CE. Tese (Mestrado em Ciências Veterinárias) – Programa de Pós-Graduação em Ciências Veterinárias. Universidade Estadual do Ceará.

COSTA, G.M.; ARAUJO, S.L.; XAVIER-JUNIOR, F.A.F.; VIANA, D.A.; EVANGELISTA, J.S.A.M. Dermatological manifestations associated with canine hypothyroidism: A review. **Revista Brasileira de Higiene e Sanidade Animal**, v. 10, n. 4, p. 781-797, 2016.

CRUZ, T.P.P.S.; NEVES, R.C.S.M.; CRUZ, F.A.C.S.; LIMA, S. R.; SOUSA, V. R. F. Displasia Folicular Do Pelo Preto Em Canino. **Acta Veterinaria Brasilica**, v. 9, n. 3, p. 284-288, 2015.

FERREIRA, R.R. MACHADO, M.L.S.; AGUIAR, J.; SPANAMBERG, A.; BIANCHI, S.P.; OLIVEIRA, E.C.; DRIEMEIER, D. Displasias foliculares



ligadas à cor da pelagem em cães: displasia folicular dos pelos pretos e alopecia por diluição da cor. **Acta Scientiae Veterinariae**, v. 35, n. 1, p. 119-124, 2007.

GROSS, T. L.; IHRKE, P. J.; WALDER, E. J.; AFFOLTER, V.K. Dysplastic diseases of the adnexa. **In: Skin diseases of the dog and cat: clinical and histopathologic diagnosis**. 2nd ed. Oxford, England: Blackwell Publishing, 2005; p. 533–534.

LIMA, D.A.; STELLA, A.E. Dermatofitose canina causada por *Trichophyton rubrum* – Relato de caso. **Revista Brasileira de Higiene e Sanidade Animal**, v. 15, n.1., p. 1-8, 2021.

LOPES, N.L.; PEIXOTO, A.P.; COSTA, T. S.; PISANI, R.B.F.; MEDEIROS, C.M. B.T.; RAMADINHA, R.R.; MASCARENHAS, M.B.; FERNANDES, J. I. Alopecia por diluição da cor: relato de caso. **Brazilian Journal of Veterinary Medicine**, v. 39, n. 3, p. 198-202, 2017.


MECKLENBURG, L.; LINEK, M.; TOBIN, D.J. **Hair Loss Disorders in Domestic Animals**. Ames: Wiley-Blackwell, 2009.

MILLER, W.H.; GRIFFIN, C.E. CAMPBELL, K.L. **Small Animal Dermatology**. 7. ed. St. Louis: W.B. Elsevier, 2013.

MÜNTENER, T.; WELLE, M. M. Canine noninflammatory alopecia: a comprehensive evaluation of common and distinguishing histological characteristics. **Veterinary Dermatology**, v. 23, p. 206–244, 2012.

RICHMAN, A.W.; GRIFFIN, C.E. Trichographic features of hair from normal black Doberman pinscher dogs. **Veterinary Dermatology**, v. 29, p. 385-e128, 2018.

SCOTT D.W.; MILLER H.W.; GRIFFIN C.E. **Muller and Kirk's Small Animal Dermatology**. 6. ed. Philadelphia: W.B. Saunders, 2001



This is an open-access article distributed under the terms of the Creative Commons Attribution License