

## CASE REPORT

DOI: 10.15517/ijds.2023.55954

Received:  
1-VI-2023

Chronic Bi-Maxillary Osteomyelitis Caused by Actinomycetes in a Patient with Severe COVID-19

Accepted:  
17-VII-2023

Published Online:  
25-VII-2023

Osteomyelitis bi-maxilar crónica causada por Actinomycetes en un paciente con COVID-19 severo

Emmanuel López-González DDS<sup>1</sup>; Marlen Vitales-Noyola PhD<sup>2</sup>;  
Diana Alvarado-Hernández PhD<sup>3</sup>; Andreu Comas-García PhD<sup>4</sup>;  
Abraham Muñoz-Ruiz PhD<sup>5</sup>; Verónica Méndez-González MS<sup>6</sup>; Amaury Pozos-Guillén PhD<sup>7</sup>

1. Endodontics Postgraduate Program, Faculty of Dentistry, UASLP, San Luis Potosí, SLP, México. International Lomas Hospital San Luis, Oral Maxillofacial Surgery, San Luis Potosí, SLP, México. <https://orcid.org/0009-0008-1590-7226>

2. Endodontics Postgraduate Program, Faculty of Dentistry, UASLP, San Luis Potosí, SLP, México. Department of Molecular Biomedicine, CINVESTAV, Mexico City, México. <https://orcid.org/0000-0002-1659-7476>

3. Department of Microbiology and Immunology, Faculty of Medicine UASLP, San Luis Potosí, SLP, México. <https://orcid.org/0000-0001-5986-0011>

4. Department of Microbiology and Immunology, Faculty of Medicine UASLP, San Luis Potosí, SLP, México. <https://orcid.org/0000-0002-2368-1529>

5. Dental Science Postgraduate Program, Faculty of Dentistry, UASLP, San Luis Potosí, S.L.P., México. <https://orcid.org/0000-0003-2522-3617>

6. Endodontics Postgraduate Program, Faculty of Dentistry, UASLP, San Luis Potosí, SLP, México. <https://orcid.org/0000-0002-0620-6603>

7. Basic Sciences Laboratory, Faculty of Dentistry, UASLP, San Luis Potosí, S.L.P., México. <https://orcid.org/0000-0003-2314-8465>

Correspondence to: PhD. Amaury Pozos-Guillén - [apozos@uaslp.mx](mailto:apozos@uaslp.mx)

**ABSTRACT:** Osteomyelitis is defined as the inflammation of the either medullary, cortical, or cancellous bone, including nerves and blood vessels, causing necrosis and bone sequestrum formation; this condition has become a rare pathology, and odontogenic infections are considered the most frequent causal factor. This case shows a patient with bi-maxillary osteomyelitis caused by *Actinomyces spp*, which was worsened for severe COVID-19 infection. Patient was submitted at surgery as, amplified total bilateral maxillectomy through the surgical technique Weber-Fergusson, and prolonged use of combination of antibiotics, achieved a good recovery. Two years later follow-up, the patient no show imaging or clinical evidence of the infection of osteomyelitis. The present case shows an interesting relationship between a rare infection and its association with COVID-19.

KEYWORDS: *Actinomyces*; Bilateral maxillectomy; COVID-19; Osteomyelitis.

RESUMEN: La osteomielitis se define como la inflamación del hueso medular, cortical o esponjoso, incluyendo nervios y vasos sanguíneos, causando necrosis y formación de sequestro óseo; esta condición es una patología rara, y las infecciones odontogénicas son consideradas como el factor causal más frecuente. En este caso, se muestra un paciente con osteomielitis bi-maxilar causada por *Actinomyces spp*, la cual empeoró por la infección de COVID-19 severo. El paciente fue sometido a una cirugía, maxilectomía bilateral total amplificada, a través de la técnica quirúrgica de Weber-Fergusson, y el uso prolongado de una combinación de antibióticos, logrando una buena recuperación. A los 2 años de seguimiento, el paciente no mostró evidencia clínica o imagenológica de la infección de osteomielitis. El presente caso muestra una interesante relación entre una infección rara y su asociación con COVID-19.

PALABRAS CLAVE: *Actinomyces*; Maxilectomía bilateral; COVID-19; Osteomielitis.

## INTRODUCTION

The oral cavity has a diverse microbial biota, so the latent risk of developing a life-threatening infection such as osteomyelitis is a concern for healthcare staff. Despite it being considered an infrequent infection, maxillary and mandible osteomyelitis is a complex disease about which we have ancient knowledge. The 1.6-million-year-old fossil, belonging to a 13-year-old homo Erectus boy clearly shows, according to paleontologists, the remaining osteomyelitis with an odontogenic infection as the origin (1).

Osteomyelitis is defined as the inflammation of the either medullary, cortical, or cancellous bone, including nerves and blood vessels, causing necrosis and bone sequestrum formation (2,3). Odontogenic infections are considered the most frequent causative factor; however, other factors have also been observed in this disease: trauma, previous endodontic, periodontics infections, surgical procedures, radiation-based treatments, chemotherapeutic treatment, HIV, diabetes, anemia, leukemia, osteoporosis, malnutrition, Paget disease, fluorosis, and alcoholism (3-5). A clinical exploration will be always the best diagnostic tool; however,

imaging is the preferred instrument, being specifically the Resonance Imaging the preferred one to detect osteomyelitis, since an observation of the intramedullary inflammation and soft tissue affection extent can be estimated (2).

Despite the most frequently isolated microorganism in jaw and mandible osteomyelitis being *Staphylococcus aureus*, a nourished group of microorganisms have been found, ranging from gram positive cocci and rods to gram-negative cocci and rods as well, most of them being either facultative anaerobic or strict anaerobic. Despite being classified as anaerobic, *Actinomyces spp*. has also the ability to grow in an aerobic environment and is considered as the most frequent pathogen causing maxillary osteomyelitis, especially in patients suffering from comorbidities such as diabetes mellitus or others immunocompromising diseases (3). Several opportunistic infections have been reported after having developed severe COVID-19, such as histoplasmosis, *actinomyces*, tuberculosis, cytomegalovirus, mucormycosis, candidiasis (6). A few cases have been reported in the last two years, where the maxillary osteomyelitis is presented after an infection of SARS CoV-2, mainly due to heavy treatment with steroids which drives to a deep

immunosuppressive state (1, 6). A surgical as well as pharmacological approach should be taken to increase the probability for a complete recovery; however, the comorbidities and the degree of progression of the disease, will be determinant in the outcome of this aggressive disease.

## CASE REPORT

Male patient of sixty-four years, from a Mexican ethnic community (tének). The patient has mellitus diabetes type II since 5 years ago, detected with 600 mg/dL of glucose, with 156 mg/dL glucose and 7.0 % HbA1(c), at moment of surgery with maxillofacial surgeon; in addition, has diabetic neuropathy and hypertriglyceridemia, take the follow drugs: vildagliptina (50 mg), intravenous insulin (only at begging of the disease), celecoxib (200 mg), pregabalin (150 mg), acetylsalicylic acid (300 mg) and B complex, patient referred arterial hypertension since 7 years ago, treated with telmisartan and/or losartan (40 mg) and nifedipine (30 mg), patient show overweight with body mass index (BMI) = 25, and occasional use of tobacco and alcohol, since forty years approximately. The patient began a three months ago with intermittent fever, which subside with antipyretics, persistent facial pain in the malar area, runny nose bilateral with purulent secretion, hyperemia in oropharynx. In Otorhinolaryngology Service, was diagnosed with chronic sinusitis and to discard invasive fungal sinusitis, was treated with intramuscular ceftriaxone (1 g) during thirty days, ciprofloxacin (500 mg) and erdosteine (200 mg) for twelve days, and amikacin (500 mg); however, the pain and infection did not subside. At the same time, the patient began with right painful periorbital edema with purulent secretion, showing right periorbital cellulitis with involved of maxillary sinus and dental area; was remitted to Ophthalmology Service and diagnosed of infectious conjunctivochalasis treated with ophthalmic chloramphenicol (5 mg) during seven days, ophthalmic solution of neomycin/dexamethasone (3.5 mg/1

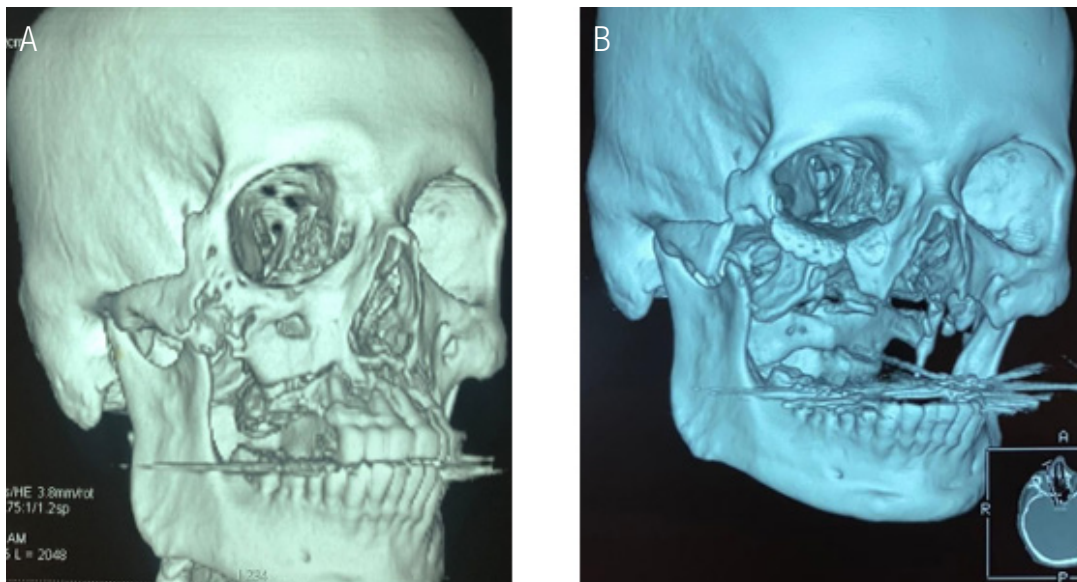
mg), eye drops solution hypromellose (3.2 mg/mL) and ophthalmic prednisolone (1%); however, the patient did not improve. General Dentistry diagnosed periodontal disease, left upper dental abscess with fistula with discharge of purulent material and treated with amoxicillin (500 mg), clindamycin (300 mg) and ibuprofen (400 mg) during seven days, azithromycin (500 mg) for three days, and buccopharyngeal benzydamine 0.15 g/100 mL.

The patient was diagnosed with pneumonia due severe COVID-19, with the next symptoms: dyspnea, fever, body pain, anosmia, dysgeusia; was hospitalized during thirty days, admitted at the hospital with 70% oxygen saturation, requiring supplemental oxygen; later, was admitted at Intensive Care Unit (ICU) for assisted mechanical ventilation (AMV) for eleven days, receiving ascorbic acid (1 g), oseltamivir (75 mg), azithromycin (500 mg) and intravenous prednisolone and/or dexamethasone (6-12 mg). It is important to highlight that at the beginning of the COVID-19 pandemic there were still no vaccines available; in addition, the patient required oxygen for thirty days. So, upon discharge from the hospital, without covid, the patient went to the maxillofacial surgeon; clinical history and informed consent was signed, sinusitis diagnosis was discarded, with four months since the evolution disease, at extra oral evaluation, the patient show pain at palpation in maxillary region, local lymphadenopathy, and limited mouth opening. In the intraoral evaluation was observed an increase of volume in vestibular region, absence of several dental organs; this area was sensitive to palpation with strong pain. The patient was submitted at axial computerized tomography (ACT) of massive facial, skull, orbital and paranasal sinus, axial simple and coronal, and panoramic X-ray, where were evidenced radiolucent zone in the right and left maxillary, malar both, and orbital floor. ACT show evidence of diminished bone density at maxillary level, osteolytic changes in maxillary bone in middle line, anterior wall and lateral of maxillary sinus and orbit floor, osteolytic

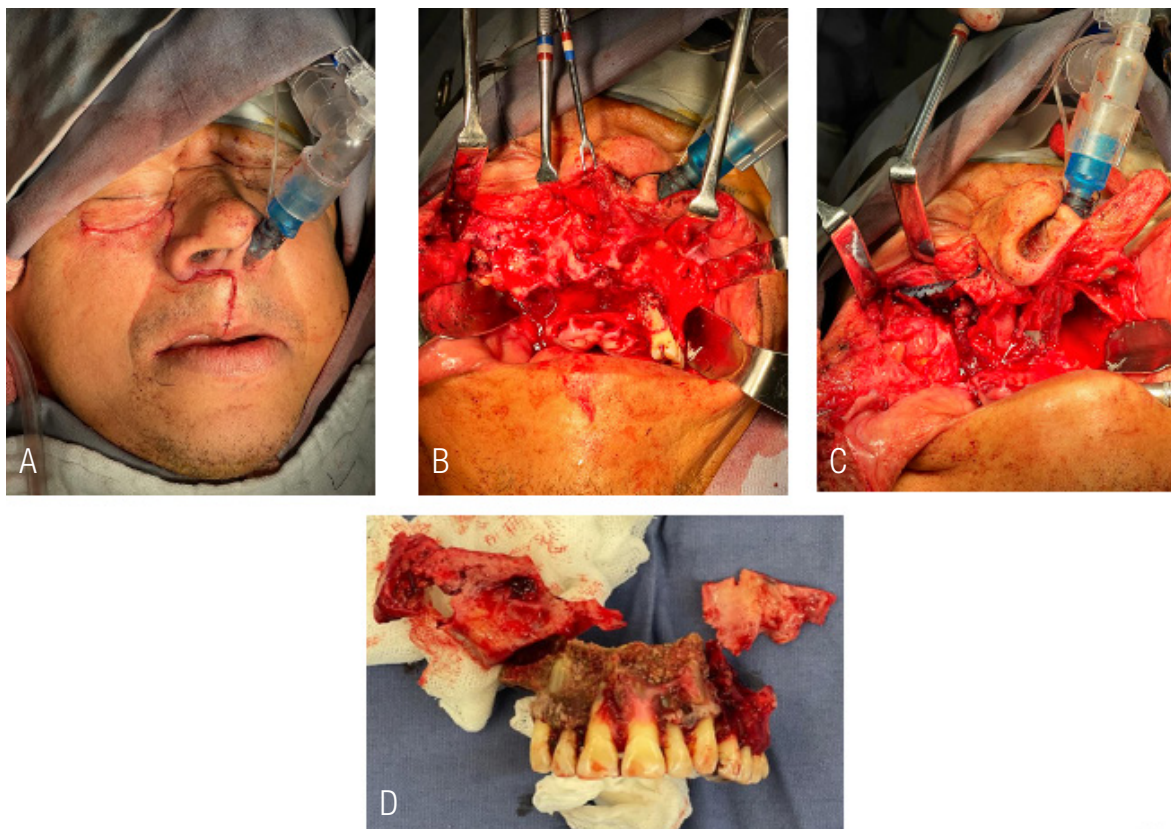
changes at level of ethmoid sinuses in wall of right maxillary sinus, without data of neoplastic infiltration (Figure 1). An incisional biopsy of nasal bone by endoscopy was performed for pathologic study and cellular culture. Final diagnosis was chronic bi-maxillary osteomyelitis with colony microbiological compatible by *Actinomyces spp.* The patient was hospitalized by 5 days, Infectiology Service solicited antibiogram assay, the patient was treated with intravenous ceftriaxone (2 g) and moxifloxacin (400 mg) during fifty days. At two days of hospitalized, the patient was submitted to surgical intervention, where maxillofacial surgeons performed extensive sequestrectomy, type II maxillectomy in left maxillary and type III maxillectomy in right maxillary without exaneration, dehybridization and decortication of right and left maxillary, malar bone both, nose bone and right orbit floor, where was collocated at surgical time a nickel-titanium plate; the surgery consisted in amplified total bilateral maxillectomy, through the surgical technique Weber-Fergusson (Figure 2), which the paralateral nasal incision descends from the superior-internal angle of the orbit medially with respect to the internal canthus of the eye, runs through the nasolabial fold, surrounding the wing of the nose, cross the base of the columella and the incision descends along the midline of the upper line for resections of the palate-dental plane. To avoid scar retractions in lip, a "Z" incision was made (zetoplasty). The time of operating room was 6 hours approximately, balanced general anesthe-

sia was administered, supplied by intravenous via several opioids (fentanyl), hypnotic drugs (propofol), neuromuscular blocker (rocuronium), for posterior nasotracheal intubation by videolaryngoscopy. External non-absorbable monofilament suture nylon 5-0 with sub-dermic points was performed, absorbable suture monofilament vicryl 4-0, was employed inside mouth with simple points and horizontal mattress. In post-operative were administered routine analgesic (ketorolac 60 mg, 1 gram of paracetamol, intravenous via both), at patient was collocated a subclavian catheter, later in home intravenous via through the catheter was administered by nursery, ceftriaxone (1 g), moxifloxacin (400 mg) via oral during one-month, sublingual ketorolac (30 mg) during three days and oral rinses with 0.12% chlorhexidine for ten days. Three months later of the surgical procedure, the patient shows pain absence, increased mouth opening, at six months later, the patient remitted improvement, good prognosis and was referred with maxillofacial prosthetist, which collocated maxillary total prosthesis (maxillary obturator) that separates nasal cavity of oral cavity, showing the patient difficulties for emitting your voice and to eat at first. One year after surgery, the patient was evaluated again, showing success in treatment, without osteomyelitis evidence, at two years follow-up the patient was discharged, without pain or pathological signs or symptoms (Figure 3) and pending facial reconstruction.

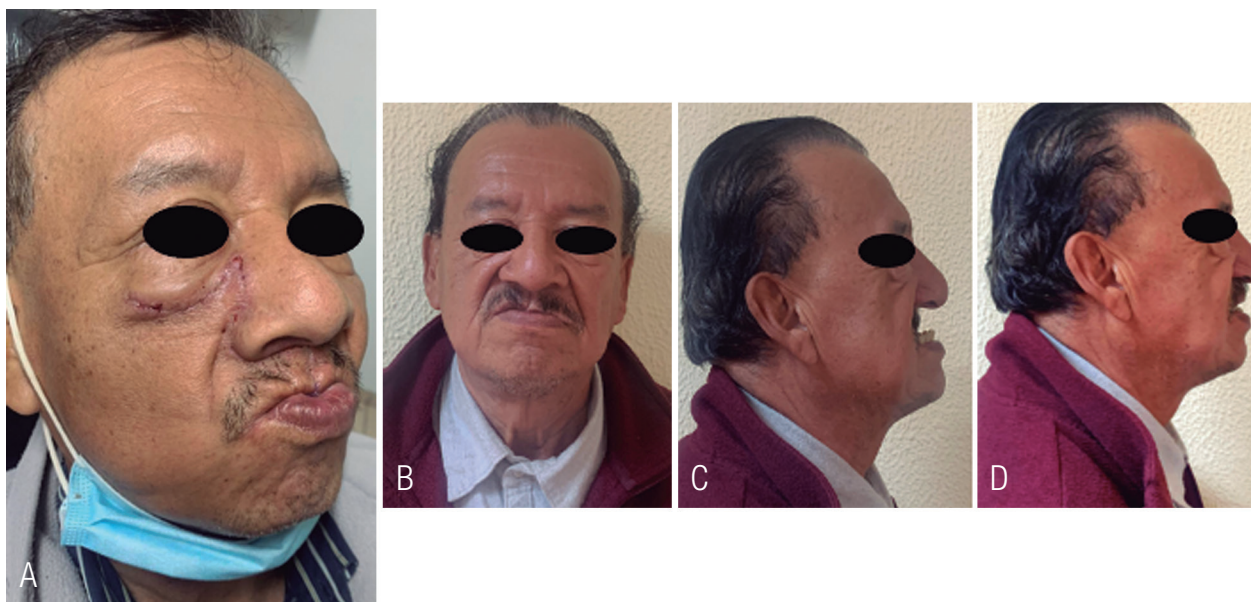



**Figure 1.** Computed tomography of patient with bi-maxillary osteomyelitis. A) Pre-operative computed tomography showing affected zones. B) Post-operative tomography, where observed the elimination of necrotic bone and colocation of Ni-Ti plates in floor orbit.



**Figure 2.** Centro-facial surgical treatment of bi-maxillary osteomyelitis. A) Surgical approach type Weber-Ferguson, where the showing the facial degloving. B) C) Surgical approach and necrotic bone removed during surgery. D) Left and right jaw, dental organs and others bones structures removed, showing necrotic zones.



**Figure 3.** Photographs after the surgical treatment. A) Photograph after surgery, showing the scars. B) Healing after two-years postoperative follow-up. C) The patient without the maxillofacial prosthesis. D) The patient with the maxillofacial prosthesis.

## DISCUSSION

Maxillary osteomyelitis is a very rare infection, due the widespread use of antibiotics, early diagnostic, and the news technologies of imaging that allow the adequate diagnosis and treatment (7). In immunocompromised patients it's most difficult to treat infectious diseases, our patient of case report, show several comorbidities as type II diabetes mellitus, overweight, arterial hypertension and the most significant severe COVID-19, for which he had to be hospitalized in intensive therapy during one month and requires assistance mechanical ventilation, time during which maxillary osteomyelitis spread, necrotizing several facial bones structures; in addition, the patient was treated with wrong diagnosis. The etiology and progression of osteomyelitis can be varied, as, odontogenic infections due exodontia complications, incomplete removal of necrotic bone, discontinuation or inappropriate choice of antibiotic therapy, poor diagnosis, jaw trauma and fractures (8, 9). In this case, the etiology was the odontogenic infection of several dental organs

and first wrong diagnosis, caused by *Actinomyces spp*, which as it is an unusual microorganism and with high levels of virulence and bacterial resistance reported in literature (8, 10); in addition, the immunological status of patient due early COVID-19, all these led to the great dissemination of osteomyelitis, which conditioned the patient to lose a large part of the facial bone structure. In most cases of maxillary osteomyelitis related to diabetes mellitus, the hyperglycemia weakens the immune system by altering the blood flow distribution to the maxilla (9); our patient shown COVID-19 with respiratory difficult, need intubation, treatment with glucocorticoids, which raised glucose levels, being a key factor in actinomycosis. Therefore, it is vitally important for the treatment of the underlying systemic disorder, control diabetes and stopping or modifying immunosuppressive or corticosteroid therapy (9). The presence of high amounts of necrotic tissue further aided actinomycosis spread locally, the present case shows an interesting relationship between a rare infection and its association with COVID-19, the disease of the present.

The treatments for maxillary osteomyelitis include since surgical exodontias to invasive and radical treatment, in combination with antibiotic therapy (3, 10). Surgical treatment involves removal of teeth, sequestration, debridement, decortication, resection, and reconstruction (3, 10). In present case, the patient was treated with intra-hospitalized antibiotics as ceftriaxone and moxifloxacin, and surgical treatment described in material and methods, achieved a good recovery; the osteomyelitis disease was bi-maxillary and with four months of evolution. One case reported in Pakistan was also a middle-age diabetic patient with COVID-19 infection, with an evolution of four months with chronic osteomyelitis in the upper maxilla (1). The other case was a mixed infection (mucormycosis, actinomycosis and candidiasis) in an older diabetic patient, with three months maxillary osteomyelitis infection (11). In post-COVID-19 patients, it also has reported septic hip abscess and other with liver abscess caused by *Actinomyces spp.* In both cases, *Actinomyces* is a rare and serious complication, related with a severe COVID-19 infection in diabetic patients (12).

## CONCLUSION

Is possible a positive association between the progression of maxillary osteomyelitis caused by actinomycetes and severe COVID-19, since patients with severe COVID-19, show a strong immunosuppression, due in part the presence of comorbidities, which contributing at presence of chronic oral infections. Even though maxillary osteomyelitis is a very rare disease today, our patient of case, the causal microorganism was *Actinomyces spp* which makes it even more unlikely, and interesting for medical and scientific community, and the infectious process has been so aggressive, due at the great virulence of these microorganisms. However, this phenomenon should be further studied, since due to the short time of COVID-19 pandemic (three years almost) we still have a lot to learn about this new disease

that is here to stay, and with the passage of time the other systemic implications will be discovered, such as in oral health.

## AUTHOR CONTRIBUTION STATEMENT

Conceptualization and design: E.L.G and A.M.R.  
Literature review: M.V.N., D.A.H. and A.C.G.  
Methodology and validation: V.M.G. and A.P.G.

Formal analysis: M.V.N. and A.P.G.

Investigation and data collection: A.P.G., M.V.N. and D.A.H.

Resources: E.L.G.

Data analysis and interpretation: A.P.G.

Writing-original draft preparation: A.P.G., M.V.N. and D.A.H.

Writing-review & editing: A.P.G.

Supervision: A.P.G.

Project administration: E.L.G.

Funding acquisition: E.L.G.

## REFERENCES

1. Arshad W., Mahmood Kamal M., Rafique Z., Rahat M., Mumtaz H. Case of maxillary actinomycotic osteomyelitis, a rare post COVID complication-case report. *Ann Med Surg.* 2022; (80): 104242. <https://doi.org/10.1016/j.amsu.2022.104242>.
2. Von B., Baltensperger M., Eyrich G., Marx R.E. Osteomyelitis of the Jaws. In *Bone and Joint Infections: From Microbiology to Diagnostics and Treatment.* XXII ed. 2015; ISBN 978 3 540 287643. <https://doi.org/10.1002/9781118581742.ch19>.
3. Gaetti-Jardim Júnior E., Fardin A.C., Gaetti-Jardim E.C., de Castro A.L., Schweitzer C.M., Avila-Campos M.J. Microbiota associated with chronic osteomyelitis of the jaws. *Braz J Microbiol.* 2010; 41 (4): 1056-1064. <https://doi:10.1590/S1517-838220100004000025>.
4. Kvolik Pavić, A., Zubčić V. Osteomyelitis of the Jaw in COVID-19 Patients: A Rare Condition With a High Risk for Severe



- Complications. *Front Surg.* 2022; 9. <https://doi.org/10.3389/fsurg.2022.867088>
5. Carvallo-Venegas M., Fuentes-López E.A., Andrade-Ortega A.J., et al. Disseminated histoplasmosis, pulmonary tuberculosis, and cytomegalovirus disease in a renal transplant recipient after infection with SARS-CoV-2. *Case Rep Transplant.* 2022; (2022): 1-5. <https://doi.org/10.1155/2022/8042168>
  6. Swaminathan N., Anderson K., Nosanchuk J.D., Akiyama M.J. *Candida glabrata* Empyema Thoracis-A Post-COVID-19 Complication. *J Fungi.* 2022; 8 (9): 4-11. <https://doi.org/10.3390/jof8090923>
  7. Habib A., Sivaji N., Ashraf T. Maxillary Osteomyelitis: A Rare Entity. *Case Rep Otolaryngol.* 2016; (2016): 9723806. <https://doi.org/10.1155/2016/9723806>
  8. Gupta N., Aggarwal A., Ramteke P., Soneja M. Mandibular osteomyelitis due to *Actinomycetes* spp. *BMJ Case Rep.* 2020; 13 (5): e235744. <https://doi.org/10.1136/bcr-2020-235744>
  9. Khandelwal P., Saluja H., Shah S., Dadhich A., Harija N. Diabetic Maxillary Osteomyelitis: A Worrisome Vulnerability-Our Experience. *J Maxillofac Oral Surg.* 2022; 21 (2): 590-598. <https://doi.org/10.1007/s12663-020-01371-6>
  10. Balaji S.M., Balaji P. Maxillary rehabilitation after complete destruction by fungal osteomyelitis. *Indian J Dent Res.* 2019; 30 (5): 807-809. [https://doi.org/10.4103/ijdr.IJDR\\_711\\_19](https://doi.org/10.4103/ijdr.IJDR_711_19)
  11. Jawanda-Manveen K., Narula R., Gupta S., Sharma V., Sidhu-Supreet K., Kaur Navneet. Mixed infection (mucormycosis, actinomycosis and candidiasis) leading to maxillary osteomyelitis in diabetic mellitus patients in post COVID phase: first case report. *Acta Medica (Hradec Králové).* 2021; 64 (4): 218-223. <https://doi.org/10.14712/18059694.2022.5>
  12. Lévay K., Daradics N., Horváth I., Kovács T., Fülöp A., Oláh A., Szijártó A. Case report of actinomycotic liver abscess following COVID-19 infection. *Ann Med Surg.* 2022; 82: 104525. <https://doi.org/10.1016/j.amsu.2022.104525>

