

## CASE REPORT

# Surgical and nonsurgical treatment of papillary hyperplasia: A case report

## Tratamiento quirúrgico y no quirúrgico de la hiperplasia papilar inflamatoria: Reporte de Caso

Edison Andrés Cruz Olivo <sup>1</sup>  | Pedro Pablo Castro<sup>2</sup> | Herney Garzón-Rayó <sup>2</sup> 



### ACCESO ABIERTO

<sup>1</sup> Universidad del Valle,  
Facultad de Salud, Escuela  
de Odontología,  
Departamento de  
Periodoncia, Cali,  
Colombia.

<sup>2</sup> Universidad del valle,  
Facultad de Salud, Escuela  
de Odontología,  
Departamento de  
Prostodoncia, Cali,  
Colombia.

### Citation

Cruz-Olivo EA, Castro  
PP, Garzón-Rayó H.  
Surgical and nonsurgical  
treatment of papillary  
hyperplasia: A case  
report. *Rev Estomatol.*  
2019;27(2):19-26. DOI:  
10.25100/re.v27i2.8951

### Correspondence

Edison Andrés Cruz Olivo.  
Universidad del Valle. Calle  
4b # 36b-00 Edificio 132.  
Email:  
andres.cruz@correounivalle  
.edu.co

### Copyright:

© Universidad del Valle.



### ABSTRACT

Dentures with dental plaque predispose recurrent hyperplasia on the palatal mucosa. Surgical procedures for the treatment of inflammatory papillary hyperplasia involve postsurgical discomfort and morbidity. This report describes clinical and histologic aspects of a patient with severe akantolitic inflammatory papillary hyperplasia. The palatal mucosa was treated with a surgical bur with a low-speed handpiece. A new removable denture was performed and adapted. A follow-up of 4 years showed stability of health at palatal mucosa. Patient referred low discomfort and morbidity when using bur technique. Control of removable denture was critical for long-term healing and soft tissue stability.

### KEYWORDS

Hyperplasia, papillary, inflammatory, denture, partial, dental prosthesis, biopsy.

### RESUMEN

Las dentaduras postizas con placa dental predisponen a la hiperplasia recurrente en la mucosa palatina. Los procedimientos quirúrgicos para el tratamiento de la hiperplasia papilar inflamatoria implican molestias y morbilidad posquirúrgicas. Este informe describe los aspectos clínicos e histológicos de un paciente con hiperplasia papilar inflamatoria akantolítica severa. La mucosa palatina se trató con una fresa quirúrgica con una pieza de mano de baja velocidad. Se realizó y adaptó una nueva dentadura removable. Un seguimiento de 4 años mostró estabilidad de la salud en la mucosa palatina. El paciente refirió baja incomodidad y morbilidad al usar la técnica de fresa. El control de la prótesis removable fue crítico para la curación a largo plazo y la estabilidad de los tejidos blandos.

### PALABRAS CLAVE

Hiperplasia, papilar, inflamatoria, prótesis, parcial, prótesis dental, biopsia.

## INTRODUCTION

Inflammatory papillary hyperplasia (IPH) known as granular type prosthetic stomatitis,<sup>1</sup> is a benign and asymptomatic lesion that results from a tissue reaction against trauma and dental plaque.<sup>2, 3</sup> It displays a papillary projections as a result of epithelial proliferation developed in the palatal mucosa that supports a desadapted denture.<sup>4,5</sup> The IPH can occur at any age,<sup>6</sup> however it is frequently found in adult patients wearing dentures, once oral mucosa becomes susceptible to irritants with aging.<sup>7</sup> In addition, it is more prevalent in males (20.5 %) than females (6.9 %), and usually located in anterior region of maxilla (79%).<sup>2</sup>

Histologic examinations described the IPH as papillary projections covered with parakeratotic stratified squamous epithelium.<sup>6,8</sup> The epithelial layer is hyperplastic and is associated with inflammatory infiltrate.<sup>9</sup> Moreover, it is observed not only presence of long and invaginated rete pegs but also crypts that, when enlarged, give rise to papillary projections. The connective tissue layer is highly vascularized and is observed with numerous lymphocytes and plasma cells near the epithelium.<sup>4,6</sup>

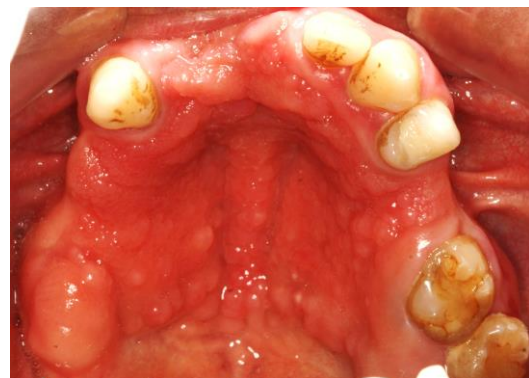Treatment of IPH varies from nonsurgical to surgical approaches depending of severity of the clinical condition.<sup>10</sup> Nonsurgical protocols reduce fungus and bacteria biofilms using antifungal mouthrinses or gels,<sup>11</sup> mouthrinse with Chlorhexidine 0.12%, fabrication of new dentures prostheses, massage of affected mucosa respectively.<sup>5</sup> However, when papillary lesion is extended all over palatal, resective surgery is commonly used.<sup>12</sup>

The aim of this case report was to describe a surgical bur technique along with prosthetic management, for the treatment of IPH in an adult male patient with 4 years of follow-up.

## CLINICAL REPORT

A 35 year-old latin male patient was referred to the Periodontology Department in the School of Dentistry of the Universidad del Valle, at Cali, Colombia for periodontal treatment. A review of patient's medical history found diagnosis of Bronchitis one-year ago and family history of palatal cleft. However, the patient had no medical conditions that contraindicate dental treatment. His chief complain was, "I want to change my denture because is old".

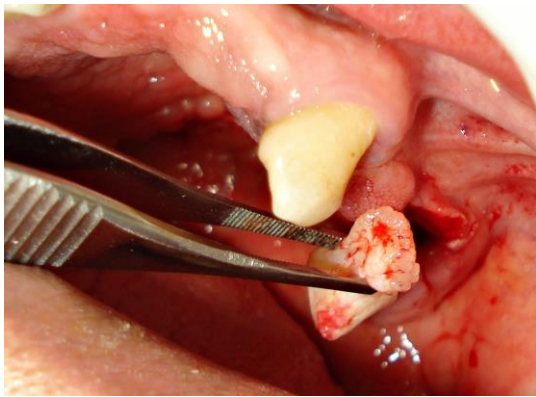
After the interview, patient reported wearing his denture for more than 10 years and no control or maintenance therapy since then. Intraoral examination showed epithelial papillary projections around palatal mucosa and edentulous ridge and under denture was supported as seen in Figure 1. These lesions were not symptomatic to palpation and did not bleed after scaling. Moreover, denture showed plaque accumulation on its palatal surface.



**Figure 1.** Clinical aspect of papillary inflammatory hyperplasia associated to dental

plaque and trauma from a desadapted removable denture.

An incisional biopsy was taken from the edentulous ridge as seen in Figure 2. Analgesic therapy was prescribed with Ibuprofen tablets 600 mg each six hours for three days. Healing by second intention was allowed for 15 days. Immediately after biopsy surgery, the denture was conditioned with a resilient denture liner. Complete healing of biopsy donor site was achieved in one month showing no signs of IPH.



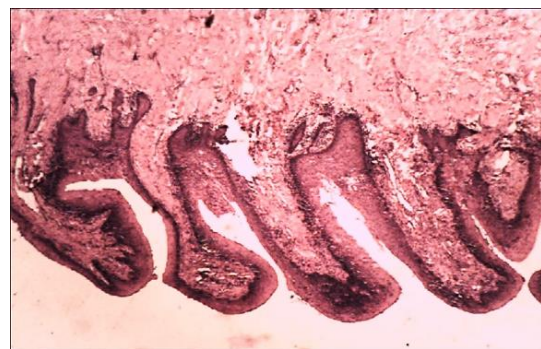
**Figure 2.** Incisional biopsy was taken from the edentulous ridge. Specimen dimensions were 12 mm long x 7 mm wide and 6 mm thick.

The stained sample was examined at a magnification of x100 using a standard 100 point grid. The epithelial width was measured and connective tissue layers were evaluated. The inflammatory infiltrate density was identified as chronic, acute or mixed and evaluated semi-quantitatively as describe by Kaplan *et al.* (1998).<sup>8</sup>

### Pathological Examination

Microscopic evaluation showed presence of oral mucosa with papilar shape both at the epithelial and connective tissue layers. The epithelial component was acantholytic showing areas of squamous cells with

change in their morphology into a koilocytic type. In addition, the epithelial layer revealed a chronic inflammatory infiltrate. Connective tissue was identified with hiperplasic collagen fibers corresponding to a inflammatory reaction with hiperplasic projections where the extracellular matrix was compromised as shown in Figure 3. Thus, confirming the diagnosis of inflammatory papillary hyperplasia.

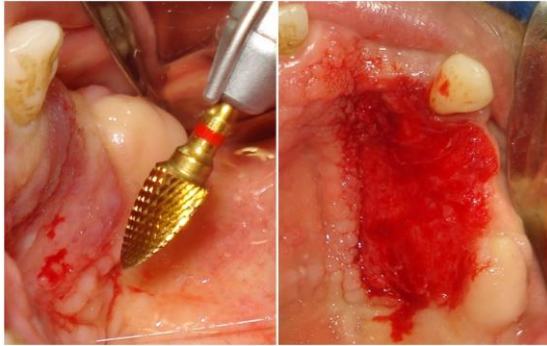


**Figure 3.** Oral mucosa. Represents a papillary type in both epithelium and connective tissue. The epithelial layer displays koilocytosis and is akantolitic.

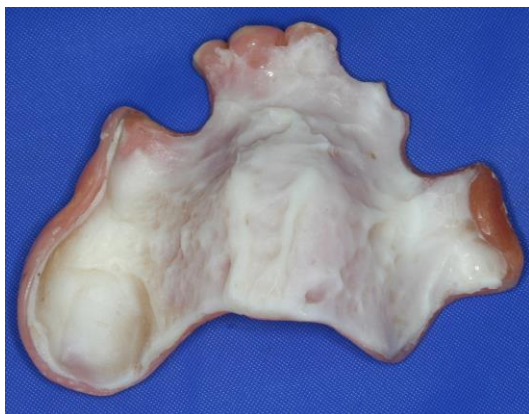### Bur with handpiece technique

Once this is a benign lesion, and the hyperplasic tissue is all over palatal mucosa and ridge, surgical approach was indicated. Then, hyperplasic tissue was removed from the palatal using a surgical bur (Dura-Last – 3/32” Shank, Diatech) with a low-speed hand piece (Kavo micromotor Intramatic 181 M) at 20.000 rpm until expose a smooth connective tissue surface as seen in Figure 4. Analgesic therapy was undertaken with Ibuprofen 600 mg each 6 hours for 3 days. Patient was instructed in using chlorhexidine gluconate 0.12% topically in the form of gel during the healing period of 8 days. Moreover, the prosthesis was

cleaned and the surface was coated with tissue conditioner for 8 days as seen in Figure 5. Finally, oral hygiene instructions were reinforced each appointment.



**Figure 4.** Bur technique for removing the hyperplastic tissue on the right side of palatal.

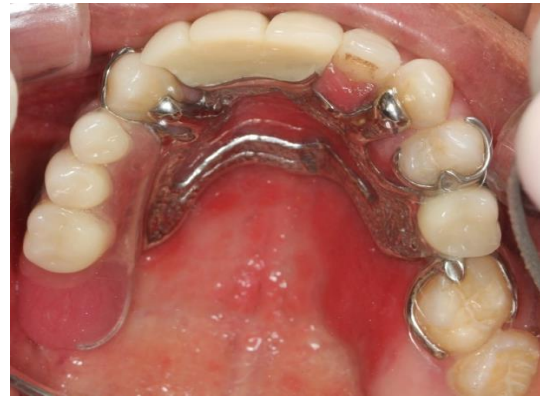

**Figure 5.** Conditioning of palatal surface of the removable denture using CoeComfort, after performing the surgical interventions.

### **Prosthetic Management**

A removable dental prosthesis metal-acrylic was performed according with parameters of retention, stability and support managed in the Prosthetic Department of the Faculty of Dentistry as seen in Figure 6. Patient also received prosthesis and oral hygiene instructions along with a reexamination of soft tissue each 15 days during five months.

Insertion and removal instructions were given and explained to the patient.



**Figure 6.** New removable denture after healing of palatal mucosa.

### **Visual analogue scale**

A visual analog scale (VAS) was used to assess postoperative discomfort and pain immediately after surgery to 4 days. The patient was asked to place a line perpendicular to the image and VAS line, at the point that represented his pain intensity after each surgery.

### **DISCUSSION**

This case report describes the drill surgical technique along with prosthetic management in a male patient with inflammatory papillary hyperplasia, family history of palatal cleft, poor oral hygiene habits, dental plaque accumulation in both teeth and denture. As previously reported, IPH has been found in male adults with more predilection in the maxillary area.<sup>2,6</sup> Moreover, studies have associated biofilm of bacteria on the denture surface, chronic mechanical trauma and systemic factors with IPH what could explain the appearance of this pathology in this patient.<sup>5,6,8,13</sup>

The IPH described in this case report, was associated with a granular inflammation type as describe by Östlund,<sup>1</sup> who classified the IPH in different types of inflammation at the mucosal of the palatal in patients wearing dentures: (i) *Local inflammation*, when palatal mucosa shows erythematous regions in an apparently normal tissue; (ii) *Difuse inflammation*, when observed a mucosa with a flat and athrophic diffuse hyperemia, extended over the area covered by denture; (iii) *Granular inflammation*, when palatal presents a nodular and hyperemic central area.

The histochemical examination showed an acantholytic epithelial component, which displays inside its layers, characteristics of koilocytosis. The acanthosis is defined as the increase of epithelial mass by means of the enhancement of mitosis and cell population. It has been found as a histologic characteristic of the IPH.<sup>4</sup> In addition, formation of crypts and the increase in size explains the source of papillarity found in this lesion. Moreover, the presence of hyperplasic papillary along with koilocytic epithelial cells, indicates an examination for human papilloma virus detection.

At connective tissue layer, it was found hyperplasia of collagen fibers with high amount of collagen content, confirming a diagnosis of koilocytic inflammatory fibroepithelial papillary hyperplasia. This pathological finding corresponds to a inflammatory reaction with hyperplasic projectinos where extracellular matrix was involved.

Lesions such as verrucous carcinoma and squamous cell carcinoma in situ show clinical similarity with IPH.<sup>5</sup> Verrucous carcinoma shows a higher prevalence in

females (56%) than in males (44%), it affect gums and alveolar mucosa, tounge, lips, palatal with possibility to expand to adjacent tissues.<sup>14</sup> In contrast, IPH is limited to the area underneath the denture, that is, palatal mucosa and alveolar ridge, and it is more frequently seen in males than in females.<sup>2</sup> On the other hand, squamous cell carcinoma is a malign lesion characterized by syntoms such as pain, bleeding, and it could be find in soft palate, floor of mouth, retromolar area, tounge.<sup>15</sup> On the contrary, IPH does not represents a maling lesion, as found after the histochemical examination of expecimens in this case report.

In this case report, the patient used his denture for more than 10 years without any prosthetic mantainance and thus, it was found a thick and mucosa beneath it. However, wearing a denture per se, do not influence in the thickness of the palatal mucosa.<sup>1</sup> In fact, a previous study showed that a healthy palatal mucosa without wearing a denture, presents 0.18 mm of thickness.<sup>1</sup> In contrast, a clinically inflammed and granular mucosa in patients wearing a denture, displays 0.28 mm ( $\pm$  0.027 mm) of thickness, that is, an increase in more than 50% compared with a healthy mucosa. Moreover, it was observed a decrease in the salivary glands layer and adipose tissue which it is asume that is replaced by connective tissue.<sup>1</sup>

Plaque control is a determinant factor in the treatment of IPH by means of dental and denture brushing and mechanical debridement.<sup>16</sup> Previous studies have shown that patients wearing partial removable dentures accumulates dental plaque at the base of denture and hooks,<sup>17</sup> and at the interdental area of teeth adjacent to fixed prosthesis.<sup>18</sup> Moreover, teeth

adjacent to a removable denture are susceptible to develop dental caries.<sup>19</sup> For this reason, the patient underwent dental plaque control before periodontal surgery and through the prosthetic treatment.

In addition, different treatments of IPH have been described in literature aiming to eliminate the IPH lesions.<sup>10,20,21</sup> Those approaches can be classified in two groups: (i) non surgical and (ii) surgical approaches. Non surgical treatment by means of prosthetic management have shown reasonable results in terms of controlling the hiperplasic lesion.<sup>10</sup> In fact, by additioning of acrylic resin on denture, and avoiding the nocturnal use for at least 6 hours daily, and by frictioning and cleanising with 0.012% chlorhexidine gluconate, it can control the IPH lesion. However, this approach has limitations when extended IPH lesions along the palatal mucosa, thus needing a surgical approach in order to eliminate completely those lesions.

Once completely healing of extended IPH cannot be achieved by means of non surgical approach, surgical intervention is indicated. This case report combines non surgical and surgical approaches mentioned above. Non surgical management was instaurated by conditioning the denture during surgical therapy and performing a new removable denture after sof tissue healing, thus improving chewing, and the integrity of soft and hard tissues as described in literature.<sup>22</sup>

On the other hand, surgical management by means bur technique showed optimal results in terms of IPH lesions eradication. However, patient referred a mild postoperatory discomfort after the intervention. This can be explained as gingivectomy is a periodontal procedure

with higher postoperative pain and discomfort because of the exposure of denuded connective tissue after tissue resection.<sup>23</sup> Moreover, time of procedure seems to have an impact on postoperative pain, because longer procedures were associated with increased postoperative pain as in this case report.<sup>23,24</sup>

The visual analogue scale (VAS) was useful in assessing the postoperative pain of patient because, it allowed the patient to express his pain in a single-item horizontal scale, with numbers at intermediat points.<sup>25</sup> This scale has been used widely for assesing pain for up 4 weeks.<sup>26</sup> In this clinical report, we used VAS to follow up the postoperative pain in each intervention for 4 days. Therefore, it seems it can be useful to compare two surgical techniques as in this clinical report.

In addition, periodontal and prosthetic management were reinforced with hygiene instructions and use of topical 0.012% chlorhexidine gluconate in gel form as describe in literature.<sup>22</sup> Topical application of gluconate chlorhexidine on the palatal mucosa, avoid bacteria and fungus colonization, kill colonizing bacteria and allows healing of palatal mucosa.<sup>27</sup>

In conclusion, treatment of IPH lesions should include patient oral hygiene instructions combined with surgical intervention by means of bur technique.

## CLINICAL RELEVANCE

This manuscript describes the clinical and histologic characteristics of inflammatory papillary hyperplasia in a latin male patient.

Non-surgical and surgical treatment showed to be efficient in terms of hyperplasic healing and non-recurrence of the lesion.

### CONFLICT OF INTEREST

The authors declare no conflicts of interest.

### REFERENCES

- Östlund SG. The effect of complete dentures on the gum tissues. *Acta Odontol Scand* 1958;16:357-60.
- Canger EM, Celenk P, Kayipmaz S. Denture-related hyperplasia: a clinical study of a Turkish population group *Braz Dent J* 2009;20:243-8.
- Anneroth G, Sigurdson A. Hyperplasic lesions of the gingiva and alveolar mucosa - A study of 175 cases. *Acta Odontol Scand* 1983;41:75-86.
- Bergendal T, Isacson G. A combined clinical, mycological and histological study of denture stomatitis. *Acta Odontol Scand* 1983;41:33-44.
- Bruch JM TN. Variants of Normal and Common Benign Conditions. In: Bruch JM TN, ed. *Clinical Oral Medicin and Pathology*. 1. New York: Springer; 2010:23-4.
- DeLong L BN. Raised Lesions with a Rough or Papillary Surface. In: *General and Oral Pathology for the Dental Hygienist*. 7. New York: Saunders 2017: 386-8.
- Lin HC, Corbet EF, Lo ECM. Oral mucosal lesions in adult Chinese. *J Dent Res* 2001;80:1486-90.
- Kaplan I, Vered M, Moskona D, Buchner A, Dayan D. An immunohistochemical study of p53 and PCNA in inflammatory papillary hyperplasia of the palate: a dilemma of interpretation. *Oral Dis* 1998;4:194-9.
- Vaz Goulart MC, Lara VS. Inflammatory Papillary Hyperplasia of the Palate: Quantitative Analysis of *Candida albicans* and its Negative Correlation with Microscopic and Demographic Aspects. *Int J Prosthodont* 2011;24:235-7.
- Orenstein NP, Taylor T. A nonsurgical approach to treating aggressive inflammatory papillary hyperplasia: a clinical report. *J Prosthet Dent* 2014;111:264-8.
- Salonen MAM, Raustia AM, Oikarinen KS. Effect of treatment of palatal inflammatory papillary hyperplasia with local and systemic antifungal agents accompanied by renewal of complete dentures. *Acta Odontol Scand* 1996;54:87-91.
- Antonelli JR, Panno FV, Witko A. Inflammatory papillary hyperplasia: suprapariosteal excision by the blade-loop technique. *Gen Dent* 1998;46:390-7.
- Ettinger RL. The etiology of inflammatory papillary hyperplasia. *J Prosthet Dent* 1975;34:254-61.
- Shear M, Pindborg JJ. Verrucous hyperplasia of the oral mucosa. *Cancer* 1980;46:1855-62.
- Mashberg A, Morrissey JB, Garfinkel L. Study of appearance of early asymptomatic oral squamous-cell carcinoma. *Cancer* 1973;32:1436-45.
- Petridis H, Hempton TJ. Periodontal considerations in removable partial denture treatment: A review of the literature. *Int J Prosthodont* 2001;14:164-72.
- Drake CW, Beck JD. The oral status of elderly removable partial denture wearers. *J Oral Rehabil* 1993;20:53-60.
- Isidor F, Budtzjorgensen E. Periodontal conditions following treatment with distally extending cantilever bridges or removable partial dentures in elderly patients - a 5-year study. *J Periodontol* 1990;61:21-6.
- Derry A, Bertram U. A clinical survey of removable partial dentures after 2 years usage. *Acta Odontol Scand* 1970;28:581-98.
- Schmitz JF. A clinical study of inflammatory papillary hyperplasia. *J Prosthet Dent* 1964;14:1034-9.
- Amaral WJ, Frost JR, Howard WR, Cheatham JL. Cryosurgery in treatment of inflammatory papillary hyperplasia. *Oral*

Surg Oral Med Oral Pathol Oral Radiol  
Endod 1968;25:648-54.

22. Bergman B, Hugoson A, Olsson CO. Periodontal and prosthetic conditions in patients treated with removable partial dentures and artificial crowns - longitudinal 2-year study. *Acta Odontol Scand* 1971;29:621-38.
23. Canakci CF, Canakci V. Pain experienced by patients undergoing different periodontal therapies. *J Am Dent Assoc* 2007;138:1563-73.
24. Curtis JW, Jr., McLain JB, Hutchinson RA. The incidence and severity of complications and pain following periodontal surgery. *J Periodontol* 1985;56:597-601.
25. Hawker GA, Mian S, Kendzerska T, French M. Measures of adult pain: Visual Analog Scale for Pain (VAS Pain), Numeric Rating Scale for Pain (NRS Pain), McGill Pain Questionnaire (MPQ), Short-Form McGill Pain Questionnaire (SF-MPQ), Chronic Pain Grade Scale (CPGS), Short Form-36 Bodily Pain Scale (SF-36 BPS), and Measure of Intermittent and Constant Osteoarthritis Pain (ICOAP). *Arthritis Care Res (Hoboken)* 2011;63 Suppl 11:S240-52.
26. Joyce CR, Zutshi DW, Hrubes V, Mason RM. Comparison of fixed interval and visual analogue scales for rating chronic pain. *Eur J Clin Pharmacol* 1975;8:415-20.
27. Jones CG. Chlorhexidine: is it still the gold standard? *Periodontol 2000* 1997;15:55-62.